

## Profile of Childhood Non-Hodgkin Lymphomas at a Tertiary Care Hospital

### Abstract

**Context:** Lymphoma was the second most common malignancy accounted for 22% of pediatric cases, of which 34 (68%) were non-Hodgkin's lymphoma (NHL). **Aims:** To find the incidence, clinical presentations, laboratory findings, proportion of extranodal involvement, and to study histological subtypes (REAL/WHO classification) of NHL, compare them with reported case series in the world literature. **Settings and Design:** Gross specimens and biopsies of pediatric NHL were retrieved from the Department of Surgical Pathology from the year 2004 to 2013 at a tertiary care hospital. **Patients and Methods:** Gross and microscopy of incisional biopsies and surgically resected specimens of pediatric cases were studied using hematoxylin and eosin stain and wherever needed special stain and immunohistochemistry were used. **Results:** The incidence of NHL was higher in more than 10 years of age group with male predominance. Burkitt's lymphoma (BL) (41.2%) was the most common subtype followed by T-lymphoblastic lymphoma (T-LL) (29.4%). Predominantly extranodal presentation was seen, BL presented as ileocecal masses (five cases) and orbital swelling (three cases). T-LL presented as a mediastinal masses (six cases). Rare cases of precursor B-LL involving orbital mass and plasmablastic lymphoma involving paranasal sinuses were studied. Among bone marrows studied a case of T-LL developed pancytopenia, during chemotherapy showed giant pronormoblast (Parvovirus infection). HIV association was seen in five cases of NHL. Postchemotherapy disease-free survival was very low and many patients died during chemotherapy. **Conclusion:** Although the incidence of HL is higher in children, in the present study, NHL with extranodal presentation (58%) involving rare sites with poor prognosis is higher, 15% of all cases showed HIV seropositivity.

**Keywords:** Burkitt's lymphoma, Non-Hodgkin lymphoma, Plasmablastic lymphoma, Precursor B- lymphoblastic lymphoma, T - lymphoblastic lymphoma

**Ratnaprabha Anil Gunge,  
Alka D Kalgutakar**

Department of Pathology,  
Lokamanya Tilak Municipal  
Medical College and General  
Hospital, Mumbai, Maharashtra,  
India

### Introduction

The incidence of pediatric tumors is on rise worldwide.<sup>[1]</sup> In developing countries like India, childhood mortality is still due to malnutrition and infections, but pediatric tumors are also rising in number<sup>[1,2]</sup> Lymphomas are the third most common group of malignancies in children and adolescents in the USA.<sup>[3]</sup> Non-Hodgkin lymphoma (NHL) accounts for approximately 7% of newly diagnosed cancers.<sup>[4]</sup> NHL constitutes 6%–10% of all pediatric malignancies in different parts of the world.<sup>[5,6]</sup>

This study looks into various NHLs causing mortality and morbidity in children and their distribution according to age and sex.

This is an open access journal, and articles are distributed under the terms of the Creative Commons Attribution-NonCommercial-ShareAlike 4.0 License, which allows others to remix, tweak, and build upon the work non-commercially, as long as appropriate credit is given and the new creations are licensed under the identical terms.

For reprints contact: reprints@medknow.com

### Patients and Methods

#### Study design

#### Selection and description of participants

In this study, 34 cases of NHL retrieved from surgical pathology were studied from 2004 to 2013. It is a retrospective and prospective study.

#### Inclusion criteria

Cases of pediatric NHL reported in the Department of Surgical Pathology age up to 15 years including males and females.

#### Exclusion criteria

Age above 15 years.

Gross and microscopic study of incisional biopsies and surgically resected specimens done using H and E stain and wherever required special stains, IHC. Furthermore, cases are analyzed according to age, sex,

**How to cite this article:** Gunge RA, Kalgutakar AD. Profile of childhood non-hodgkin lymphomas at a tertiary care hospital. Indian J Med Paediatr Oncol 2019;40:S82-8.

**Address for correspondence:**  
Dr. Ratnaprabha Anil Gunge,  
Department of Pathology,  
Lokamanya Tilak Municipal  
Medical College and General  
Hospital, Mumbai, Maharashtra,  
India.  
E-mail: ratnaprabha\_tdy@  
yahoo.co.in

#### Access this article online

Website: www.ijmpo.org

DOI: 10.4103/ijmpo.ijmpo\_230\_17

#### Quick Response Code:



and clinical features. Retrospectively, surgically resected and biopsied cases of pediatric NHL were studied by using clinical data from record sheets and reviewing slides and paraffin blocks. Detailed clinical history was obtained from the indoor papers from medical record office.

Morphological features of external and cut surfaces of the organs were documented and they were preserved in 10% formalin for adequate fixation. After fixation, adequate sections from each of the organs were taken. Sections were studied by using H and E stain and IHC.

Radiological findings (computed tomography [CT], magnetic resonance imaging [MRI], X-ray, and ultrasonography [USG]) and complete blood count with other laboratory investigations were retrieved from the indoor papers. Subtyping of lymphomas was done with the help of IHC.

Clinical information obtained from patients medical records included as follows:

1. Patients age, sex, and chief complaints
2. Physical examination:
  - a. Lymphadenopathy – localized/generalized
  - b. Hepatosplenomegaly
  - c. Abdominal mass
  - d. Gastrointestinal involvement
  - e. Mediastinal involvement
  - f. Any other site involvement
3. Radiological findings
  - a. USG/CT of abdomen and pelvis
  - b. Positron-emission tomography scan findings (wherever done) findings.
4. Laboratory investigations
  - a. Complete blood count – Hemoglobin, white blood cell count, differential count, and platelet counts.
  - b. Serum B2 microglobulin and LDH (lactate dehydrogenase) levels
  - c. Serum total protein, albumin, and globulin
  - d. Serological tests – HIV
5. Ann Arbor staging.

## Results

During the study 4302 pediatric cases up to the age of 15 years from the year 2004 to 2013 were retrieved, constituting 5.6% of all. The incidence of pediatric malignancies was 5.2% (227) of all pediatric cases, and incidence of pediatric lymphoma was found to be 22% (50) of all pediatric malignancies [Figure 1]. Among these, central nervous system (CNS) tumors (43%) were the most common followed by lymphoma (22%), of which NHL constitutes 15% (34) cases [Figure 2]. Among NHL, Burkitt’s lymphoma (BL) was the most common 14 cases (41.2%) followed by lymphoblastic lymphoma (LL) 11 cases (32.3%), two cases of anaplastic large-cell lymphoma (ALCL) and one case of plasmablastic

lymphoma were reported. Six cases of NHL were unclassified due to unavailability of tissue blocks for further subtyping [Table 1 and Figure 3].

In the present study, maximum number of 15 (44.1%) NHL cases were found beyond 10 years of age (44.1%) cases, mean age of incidence of NHL was 8.7 years, and ranging from 2.5 years to 13 years [Table 2].

The youngest patient was of 2.5 years age presented with abdominal mass, diagnosed with BL. The overall majority

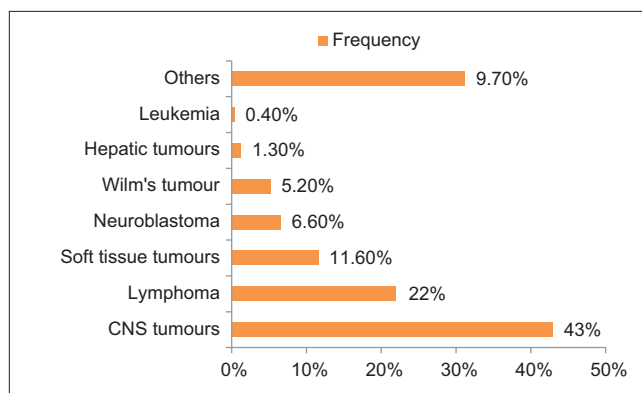


Figure 1: Distribution of different malignancies in pediatric population (n = 227)

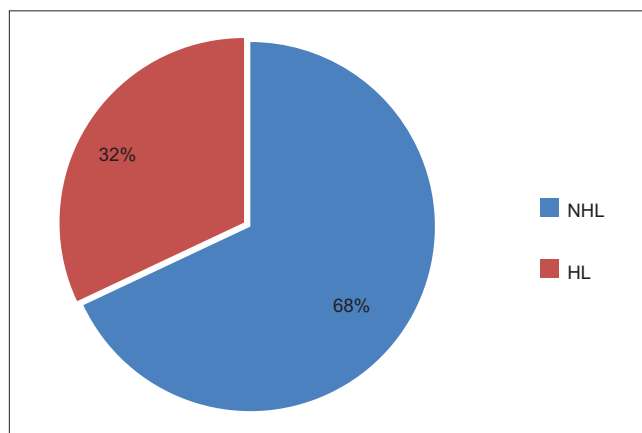


Figure 2: Frequency of Hodgkin's lymphoma and Non-Hodgkin's lymphoma. Out of 50 cases of lymphoma, 34 (68%) diagnosed with Non Hodgkin lymphoma

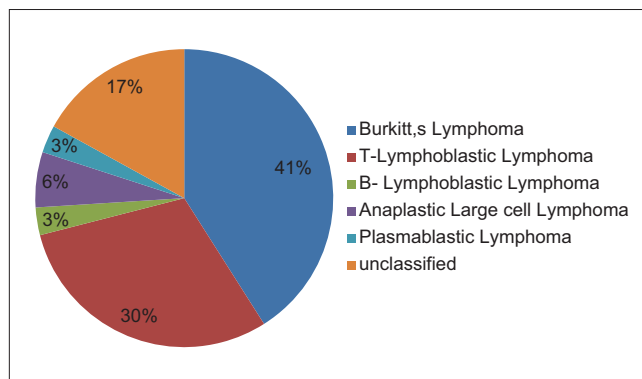


Figure 3: Frequency distribution of subtypes of Non-Hodgkin's lymphoma

of NHL showed male predominance with M: F ratio of 2:1, while ALCL showed gender equality [Table 3].

**Table 1: Frequency distribution of subtypes non-Hodgkin's lymphoma**

Histological type	Frequency (%)
NHL	34 (68)
BL	14 (41.2)
T-LL	10 (29.4)
B-LL	1 (2.9)
ALCL	2 (5.8)
Plasmablastic lymphoma	1 (2.9)
Unclassified	6 (17.8)

NHL – Non-Hodgkin's lymphoma; BL – Burkitt's lymphoma; T-LL – T-lymphoblastic lymphoma; B-LL – B-lymphoblastic lymphoma; ALCL – Anaplastic large cell lymphoma

**Table 2: Age distribution of non-Hodgkin's lymphoma (n=34)**

Age groups (years)	NHL, n (%)
0-5	7 (20.5)
5-10	12 (35.3)
10-15	15 (44.1)

NHL – Non-Hodgkin's lymphoma

**Table 3: Gender distribution of non-Hodgkin's lymphoma**

Histological subtype	n	Male	Female
BL	14	9	5
LL	11	9	2
ALCL	2	1	1
Plasmablastic lymphoma	1	0	1
NHL unclassified	6	4	2

BL – Burkitt's lymphoma; NHL – Non-Hodgkin's lymphoma; ALCL – Anaplastic large cell lymphoma; LL – Lymphoblastic lymphoma

**Table 4: Site of involvement of subtypes of non-Hodgkin's lymphoma (n=34)**

Site of involvement	BL	LL	ALCL	PL	U
Peripheral LN	8	6	1	0	5
Mediastinum	1	6	1	0	0
GIT	5	1	0	0	1
Parotid	1	0	0	0	0
Kidney	0	1	0	0	1
Testis	0	0	0	0	1
Bone marrow	2	1	0	0	1
Spinal cord	1	0	1	0	0
Liver	1	0	0	0	0
Orbit	3	1	0	0	0
Nose	0	0	0	1	0

BL – Burkitt's lymphoma; ALCL – Anaplastic large-cell lymphoma; LL – Lymphoblastic lymphoma; GIT – Gastrointestinal tract; LN – Lymph node; PL – Plasmablastic lymphoma; U – Unclassified

Majority of the cases were found in Stage 2 and 3, constituting 23 cases (68%) suggestive of the widespread involvement of disease at the time of diagnosis.

In the present study, NHL showed predominantly extranodal involvement.

Five cases of BL showed gastrointestinal involvement, the most common site was small bowel (ileocecal). Three cases presented as orbital mass, one case showed paraspinal soft-tissue swelling at D4–D5 level, and another as tibial swelling with extensive abdominal and mediastinal deposits [Table 4].

Maximum cases of BL found in Stage 3 and 4. Four of 14 cases were HIV seropositive, showed poor prognosis, and died during the treatment course.

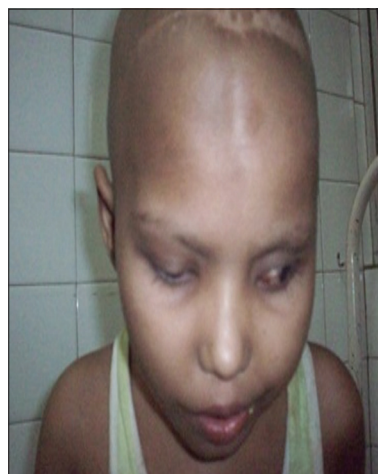Six cases of T-LL presented with mediastinal widening due to mediastinal mass and lymphadenopathy, of which in three cases pleural and pericardial fluid were positive for malignant cells on fluid cytology [Table 4].

One of the cases of T-LL showed CNS involvement with CSF positive for malignant cells and extensive pleural, pericardial, and abdominal involvement, while another showed extensive bone marrow involvement with 80% of blast.

One case of B-LL showed bilateral large lobulated intraorbital mass occupying the retrobulbar portion, orbital apex, and extending into the cavernous sinus. The mass was encasing the optic nerve and the patient died during the treatment.

Two cases of ALCL presented as paraspinal masses, one patient presented as fever, weight loss, and back pain with spinal cord lesion died during therapy. Another patient presented as multiple lymph node enlargement with visceral deposits.

A 14-year-old male child presented with left side nasal obstruction for 3 months with epistaxis, 3–4 episodes. CT



**Figure 4: A 6-year-old child with unilateral proptosis, diagnosed with precursor B-lymphoblastic lymphoma on biopsy (LTMMC, Mumbai, India)**

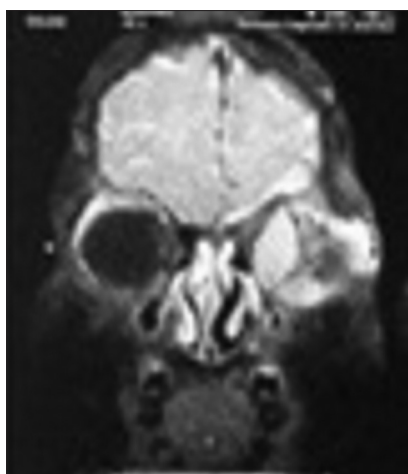


Figure 5: Magnetic resonance imaging of brain and orbit showed large lobulated intraorbital mass occupying the retrobulbar portion, orbital apex, and extends into cavernous sinus, c/o precursor B- lymphoblastic lymphoma

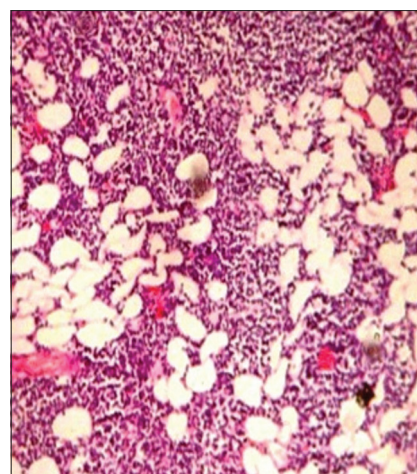

Figure 6: Sheets of tumor cells infiltrating into orbital soft tissue and muscle, medium-sized lymphoid cells with thin nuclear membrane, delicate chromatin, indistinct nucleoli, brisk mitoses, scant cytoplasm – Precursor B LL, (H and E, ×100), IHC: LCA, CD20, and Tdt- Positive

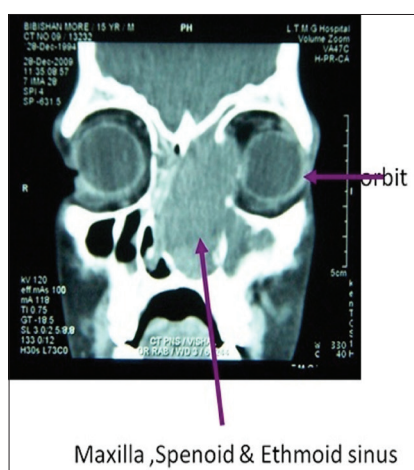


Figure 7: CT skull and nasal cavity shows soft-tissue lesion involving left nasal cavity extending into maxilla, sphenoid, and ethmoid sinus, sparing left orbit - c/o Plasmablastic lymphoma

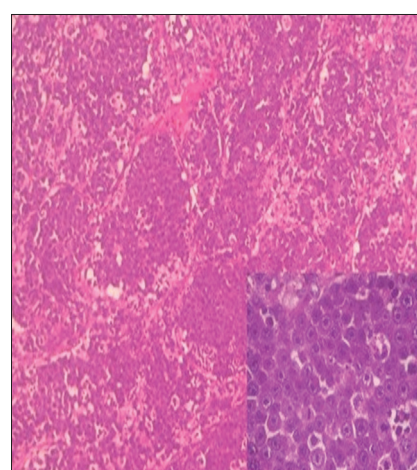


Figure 8: Prominent tingible body macrophages, imparting a starry-sky appearance with prominent mitotic activity, monomorphic population of large plasmablastic cells with abundant basophilic cytoplasm, and prominent peripheral-based nucleoli - Plasmablastic Lymphoma - (H and E, ×100), IHC – Positive – EMA, LCA, CD138

**Table 5: HIV-associated non-Hodgkin's lymphoma**

Age/sex	Subtype of NHL	Site of involvement
12 years/male	BL	Small bowel mass
7 years/male	T-LL	Multiple lymphadenopathy
11 years/male	BL	Lymphadenopathy with paraspinal soft tissue extension
13 years/female	BL	Lymphadenopathy with orbital and small bowel mass
2.5 years/female	BL	Small bowel mass with tibia, peripancreatic, and pericardiac LN deposits

BL – Burkitt's lymphoma; NHL – Non-Hodgkin's lymphoma; T-LL – T-lymphoblastic lymphoma; LN – Lymph node

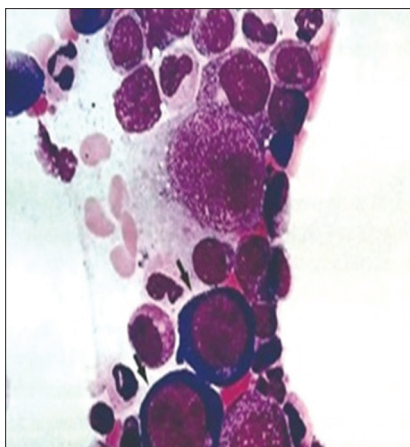
skull and nasal cavity showed soft-tissue lesion involving left nasal cavity extending into maxilla, sphenoid and ethmoid sinus, and sparing left orbit. On histopathological

examination and immunohistochemistry, the patient was diagnosed with plasmablastic lymphoma and the patient died during therapy.

Cases showed the involvement of the kidney, parotid glands, testis, and liver by neoplastic lymphoid cells which are not common. Visceral presentation is more common compared to nodal, later found only in 3 cases.

A higher incidence of NHL is seen in HIV-positive cases, with predominant subtype being BL [Table 5].

On laboratory testing, NHL cases showed decreased levels of hemoglobin, while no significant change was found in total leukocyte count or platelet count, while serum LDH and serum B2 Microglobulin were significantly raised in the majority of cases.



**Figure 9:** A 10-year-old male child diagnosed with T-lymphoblastic lymphoma, Bone marrow aspiration showed giant proerythroblast with pale cytoplasmic inclusions suggestive of parvovirus infection (Giemsa,  $\times 1000$ )

## Discussion

Lymphoma has been reported as the second or third most common childhood malignancy in India,<sup>[7]</sup> and other countries;<sup>[7]</sup> similarly in this study, it was the second most common pediatric malignancy after CNS tumors.

In the present study, the incidence of pediatric lymphoma was 22% of all pediatric malignancies, which is comparable with studies conducted by (24.2%) Jabeen *et al.*,<sup>[8]</sup> (20.3%) Swaminathan *et al.*<sup>[9]</sup>

Srinivas *et al.* (2002)<sup>[10]</sup> have reported the incidence of NHL 10%–13% which is comparable with present study (15%), while Swaminathan *et al.*<sup>[9]</sup> have reported it lower (8.4%).

Incidence of NHL was higher (44.1%) in age group more than 10 years, which is comparable (60%) with the study conducted by Manipadam *et al.*<sup>[7]</sup>

M: F ratio in the present study (2:1) is comparable with the studies conducted by Manipadam *et al.*<sup>[7]</sup> (2.87:1), Wright *et al.*<sup>[11]</sup> (2.7:1), and Nandakumar *et al.*<sup>[12]</sup> (2.5:1) under 15 years of age group reported from India.

Manipadam *et al.*<sup>[7]</sup> have reported most of the NHL subtypes showed a marked male predominance except ALCL, which showed gender equality.

Wright *et al.*, UK,<sup>[11]</sup> Hwang *et al.*, Korea,<sup>[13]</sup> and Burkhardt *et al.*, Germany<sup>[14]</sup> reported BL as the most common NHL subtype which is similar to the present study, while Manipadam *et al.*, India<sup>[7]</sup> and Srinivas *et al.*, (1983) India<sup>[10]</sup> reported LL as the most common NHL subtype and BL as the second most common.

Incidence of extranodal presentation 67.5% (mediastinal and gastrointestinal) in absence of peripheral lymphadenopathy is much higher in the present study compared to previous study done by Srinivas *et al.* (1983)<sup>[10]</sup> (32%) and Manipadam *et al.*<sup>[7]</sup> (52%).

Majority of the cases of BL showed abdominal (ileocecal) 64.2% similar to reported by Advani *et al.*<sup>[15]</sup> (70%) and Srinivas *et al.*<sup>[10]</sup> (85.7%). Furthermore, 72.2% of cases of LL showed mediastinal involvement similar to studies done by Advani *et al.*<sup>[15]</sup> (65%).

## HIV associated Non-Hodgkin's lymphoma

BL is a highly aggressive lymphoma and its association with seropositivity and immunosuppression is known. In the present study, four of 14 cases of BL and one case of LL studies were HIV seropositive, whereas Manipadam *et al.*<sup>[7]</sup> reported only one patient with HIV infection and diagnosed with BL.

## Burkitt's lymphoma

Magrath<sup>[16]</sup> reported Burkitt's lymphoma is biologically heterogeneous, has become notorious due to its high incidence in individuals infected with HIV, which is providing a second, potentially fertile model for the exploration of the pathogenesis of lymphoid neoplasms. In the present study, four of 14 cases diagnosed with BL were HIV seropositive.

## Lymphoblastic lymphoma

Manipadam *et al.*<sup>[7]</sup> reported 61.7% of LL cases, mode of presentation was peripheral lymph node enlargement and only 33.3% of the cases had involvement of mediastinum, while in the present study significantly higher no of cases showed mediastinal involvement.

A 6-year-old girl presented with gradually increasing proptosis of left eye over 6 months [Figure 4]. On examination she had proptosis of the eye with eyelid edema, vision, and pupillary reflexes were preserved, no papilledema. MRI brain and orbit showed fairly large lobulated intraorbital mass occupying the retrobulbar portion, orbital apex which was extending into the cavernous sinus [Figure 5].

Resection of the mass was done. Intraoperatively tumor was well circumscribed, not involving the optic nerve. Histopathological examination showed bits of tumor tissue showing diffuse dense monomorphous proliferation of lymphoid cells, infiltrating in the orbital soft tissue and muscle, and tumor cells were medium-sized lymphoid cells with thin nuclear membrane, delicate chromatin, indistinct nucleoli, brisk mitoses, and scant cytoplasm. On immunohistochemistry, tumor cells were negative for desmin, mic2, MPO, and synaptophysin and positive for LCA, CD20 and Tdt [Figure 6].

Final diagnosis—Primary orbital precursor B-cell lymphoblastic lymphoma.

The patient was started with systemic chemotherapy and died during the treatment course.

Similar cases of primary ocular adnexal lymphomas in younger age group of 7–12 years presenting as proptosis with loss of vision due to unilateral orbital mass involving optic nerve extending into anterior cranial fossa have been

reported by Ferry *et al.*,<sup>[17]</sup> Alford *et al.*,<sup>[18]</sup> and Hari Mohan *et al.*<sup>[19]</sup>

A 14-year-old male child presented with left side nasal obstruction for 3 months with epistaxis, 3–4 episodes. CT skull and nasal cavity showed soft-tissue lesion involving left nasal cavity extending into maxilla, sphenoid and ethmoid sinus, and sparing left orbit. Resection of the mass was done [Figure 7].

On histopathological examination, soft-tissue tumor showed the monomorphic population of large plasmablastic cells with abundant basophilic cytoplasm. Round to ovoid vesicular nuclei with prominent peripheral-based nucleoli. Prominent tingible body macrophages seen imparting a starry-sky appearance with prominent mitotic activity suggestive of plasmablastic lymphoma.

Dignosis was confirmed on IHC and tumor cells were positive for CD138, EMA, LCA, and negative for CD20, CD56, CK, S100, NSE, synaptophysin, and chromogranin [Figure 8].

Plasmablastic lymphoma is a rare and rapidly progressive variety of DLBL that was originally reported exclusively in the jaw and oral mucosa of male-predominant HIV-positive patients. A substantial minority of cases occur in HIV-negative patients following solid organ transplantation or immunosuppressive therapy.

Christine *et al.*<sup>[20]</sup> have reported a 24-year-old male presented with chronic sinusitis, pain in the left cheek, and left-sided facial asymmetry for 2 months. CT scan showed left maxillary sinus mass, involving the nasal septum, and extending through the medial maxillary sinus wall into the left nasal canal. The mass also invaded the inferior orbital rim and abutted the inferior rectus muscle. Biopsy of the mass revealed a monotonous, highly proliferative sheet of mononuclear cells, and IHC studies diagnosed plasmablastic lymphoma.

In the present study, a 10-year-old male child presented with fever, cough, and chest pain with repeated hemorrhagic pleural and pericardial effusion. USG chest showed moderate-to-severe pericardial and pleural effusion with right-sided lung collapse. CT chest showed a mediastinal mass. Pleural fluid cytology showed atypical round cells suggestive of lymphoma.

Histopathological examination and IHC on lymph node biopsy were conducted and diagnosed with T-LL.

Patient was started with chemotherapy, during the treatment course developed pancytopenia for which bone marrow examination was conducted.

Bone marrow aspirate showed erythroblastopenia with giant pronormoblast with 14% lymphomonocytoid cells suggestive of parvovirus infection [Figure 9]. The patient was detected with raised titers of immunoglobulin M parvovirus antibodies and diagnosis was confirmed with serology.

Parvovirus B19 infection causes severe cytopenia and can mimic a leukemic relapse or therapy-induced cytopenia in patients with hematologic malignancies, and Hence, screening for parvovirus B19 DNA by polymerase chain reaction (PCR) in pediatric patients with ALL and unexplained cytopenia is suggested. Detection of giant pronormoblasts and absence of normal mature erythroid precursors is characteristic of parvovirus infection, on a routine bone marrow examination.

Lindblom *et al.*, USA<sup>[21]</sup> reported among 117 children with ALL, 18 (15%) were found to be parvovirus B19 DNA positive, while the infection was suspected on clinical grounds in only one of these 18 patients.

Yetgin *et al.*, Turkey<sup>[22]</sup> reported two cases of parvovirus B19 infection and bone marrow infiltration with preBlymphoblasts, one patient was diagnosed with ALL, and the other patient with neurologic findings, showed total resolution of the blastic morphology and phenotype.

McNall, USA<sup>[23]</sup> described a patient undergoing induction therapy for ALL whose parvovirus B19 infection was identified by the incidental bone marrow examination.

Immunocompromised children including those undergoing chemotherapy treatment of malignant disease, are at particular risk for infection with parvovirusB19, immunoglobulin therapy can revert this changes, this highlights the importance of alertness to the possibility of parvovirus infection in children with cancer.

In the present study, three cases presented as orbital swelling with intracranial extension, 3-year-old male child presented with unilateral proptosis, headache, and decreased vision. CT scan showed soft-tissue lesion involving orbit, small bowl thickening with mesenteric lymphadenopathy. The child was diagnosed with secondary involvement of orbit with primary gastrointestinal BL.

Zak *et al.*<sup>[24]</sup> reported a case of non-African BL presenting an acute bilateral fulminant exophthalmos in as infantile male, correlates with the present study.

Huisman *et al.*<sup>[25]</sup> reported a 12-year-old boy who presented with incomplete right ophthalmoplegia, exophthalmos, and headache diagnosed with BL on mediastinal LN biopsy.

## Conclusion

The incidence of pediatric tumors is increasing worldwide. Although malignant neoplasms are rare in children, it is an important cause of childhood mortality in many of the economically developed nations of the world. Due to the major advances in diagnosis, multimodality therapy, development of the rational use of combination chemotherapy, and improved supportive care, the cure rate in childhood cancer has increased tremendously and over 60% of all childhood cancers are now curable.

Among childhood malignancies, lymphomas contribute the second most common. Although the incidence of

Hodgkin's lymphoma was higher in pediatric age group, number of NHL cases is rising rapidly due to increased prevalence of HIV patients, immunodeficiency, and many undiagnosed etiologies. Disease-free survival period is very less in majority of NHL patients with predominantly extranodal visceral involvement, as many of them died during chemoradiation.

Clinical and histopathological study of these cases helps in knowing their epidemiology and burden of disease in the community. With a careful assessment of histomorphological features along with clinical and radiological imaging information, accurate diagnosis of NHL is possible. Although conventional H and E can diagnose the lymphomas, IHC plays an important role in further subtyping of lymphoma.

Parvovirus B19 infection causes severe cytopenia and can mimic therapy-induced cytopenia in lymphoma patients, and hence, screening for parvovirus B19 DNA by PCR in lymphoma patients on therapy with unexplained cytopenia is suggested. Detection of giant pronormoblasts and absence of normal mature erythroid precursors is characteristic of parvovirus infection on routine bone marrow examination.

#### Declaration of patient consent

The authors certify that they have obtained all appropriate patient consent forms. In the form the patient(s) has/have given his/her/their consent for his/her/their images and other clinical information to be reported in the journal. The patients understand that their names and initials will not be published and due efforts will be made to conceal their identity, but anonymity cannot be guaranteed.

#### Financial support and sponsorship

Nil.

#### Conflicts of interest

There are no conflicts of interest.

#### References

- Rathi AK, Kumar S, Ashu A, Singh K. Epidemiology of pediatric tumors at a tertiary care centre. *Indian J Med Paediatr Oncol* 2007;28:33-5.
- Kusumakumary P, Jacob R, Jothirmayi R, Nair MK. Profile of pediatric malignancies: A ten year study. *Indian Pediatr* 2000;37:1234-8.
- Stiller CA. International patterns of cancer incidence in adolescents. *Cancer Treat Rev* 2007;33:631-45.
- Gross TG, Termuhlen AM. Pediatric non-Hodgkin's lymphoma. *Curr Oncol Rep* 2007;9:459-65.
- Kaplinsky C, Zaizov R. Childhood B-cell non-Hodgkin's lymphoma in Israel. *Leuk Lymphoma* 1994;14:49-53.
- Samuelsson BO, Ridell B, Röckert L, Gustafsson G, Márky I. Non-Hodgkin lymphoma in children: A 20-year population-based epidemiologic study in Western Sweden. *J Pediatr Hematol Oncol* 1999;21:103-10.
- Manipadam MT, Nair S, Viswabandya A, Mathew L, Srivastava A, Chandy M, *et al.* Non-Hodgkin lymphoma in childhood and adolescence: Frequency and distribution of immunomorphological types from a tertiary care center in South India. *World J Pediatr* 2011;7:318-25.
- Jabeen S, Haque M, Islam MJ, Talukder MH. Profile of paediatric malignancies: A five year study. *J Dhaka Med Coll Cancer* 2010;19:33-8.
- Swaminathan R, Rama R, Shanta V. Childhood cancers in Chennai, India, 1990-2001: Incidence and survival. *Int J Cancer* 2008;122:2607-11.
- Srinivas V, Soman CS, Naresh KN. Study of the distribution of 289 non-Hodgkin lymphomas using the WHO classification among children and adolescents in India. *Med Pediatr Oncol* 2002;39:40-3.
- Wright D, McKeever P, Carter R. Childhood non-Hodgkin lymphomas in the United Kingdom: Findings from the UK Children's Cancer Study Group. *J Clin Pathol* 1997;50:128-34.
- Nandakumar A, Anantha N, Appaji L, Swamy K, Mukherjee G, Venugopal T, *et al.* Descriptive epidemiology of childhood cancers in Bangalore, India. *Cancer Causes Control* 1996;7:405-10.
- Hwang IG, Yoo KH, Lee SH, Park YH, Lim TK, Lee SC, *et al.* Clinicopathologic features and treatment outcomes in malignant lymphoma of pediatric and young adult patients in Korea: Comparison of Korean all-ages group and Western younger age group. *Clin Lymphoma Myeloma* 2007;7:580-6.
- Burkhardt B, Zimmermann M, Oschlies I, Niggli F, Mann G, Parwaresch R, *et al.* The impact of age and gender on biology, clinical features and treatment outcome of non-Hodgkin lymphoma in childhood and adolescence. *Br J Haematol* 2005;131:39-49.
- Advani S, Pai S, Adde M, Vaidya S, Vats T, Naresh K, *et al.* Preliminary report of an intensified, short duration chemotherapy protocol for the treatment of paediatric non-Hodgkin's lymphoma in India. *Ann Oncol* 1997;8:893-7.
- Magrath IT. African Burkitt's lymphoma. History, biology, clinical features, and treatment. *Am J Pediatr Hematol Oncol* 1991;13:222-46.
- Ferry JA. Burkitt's lymphoma: Clinicopathologic features and differential diagnosis. *Oncologist* 2006;11:375-83.
- Alford MA, Nerad JA, Conlan RM, Comito M, Giller RH. Precursor B-cell lymphoblastic lymphoma presenting as an orbital mass. *Orbit* 1999;18:17-24.
- Mohan H, Sen DK, Chatterjee PK. Primary reticulo-endothelial tumours of orbit. *Indian J Ophthalmol* 1971;19:61-6.
- Saraceni C, Agostino N, Cornfield DB, Gupta R. Plasmablastic lymphoma of the maxillary sinus in an HIV-negative patient: A case report and literature review. *Springerplus* 2013;2:142.
- Lindblom A, Heyman M, Gustafsson I, Norbeck O, Kaldensjö T, Vernby A, *et al.* Parvovirus B19 infection in children with acute lymphoblastic leukemia is associated with cytopenia resulting in prolonged interruptions of chemotherapy. *Clin Infect Dis* 2008;46:528-36.
- Yetgin S, Çetin M, Aslan D, Öyürek E, Anlar B, Uçkan D, *et al.* Parvovirus B19 infection presenting as pre-B-cell acute lymphoblastic leukemia: A Transient and progressive course in two children. *J Pediatr Hematol Oncol* 2004;26:689-92.
- McNall RY, Head DR, Pui CH, Razzouk BI. Parvovirus B19 infection in a child with acute lymphoblastic leukemia during induction therapy. *J Pediatr Hematol Oncol* 2001;23:309-11.
- Zak TA, Fisher JE, Afshani E. Infantile non-African Burkitt's lymphoma presenting as bilateral fulminant exophthalmos. *J Pediatr Ophthalmol Strabismus* 1982;19:294-8.
- Huisman TA, Tschirch F, Schneider JF, Niggli F, Martin-Fiori E, Willi UV, *et al.* Burkitt's lymphoma with bilateral cavernous sinus and mediastinal involvement in a child. *Pediatr Radiol* 2003;33:719-21.