

A Man with Pulmonary and Bilateral Adrenal Lesions

A 65-year-old male, smoker presented with complaints of dry cough, chest pain, and low-grade fever for the last 3 months in the pulmonary department. Multifocal dense consolidations involving bilateral lung fields were discovered on simple chest X-rays [Figure 1]. His vital signs on admission were normal and laboratory results were white blood cells 5400/mm³, hemoglobin 15.2 g/dL, hematocrit 39.2%, platelet 188 k/mm³, and erythrocyte sedimentation rate 5 mm/h. A serology test and culture for mycoplasma and tuberculosis were all negative. Chest and abdomen computed tomography showed multifocal dense consolidations involving bilateral lungs with perihilar predominance and hypodense bilateral adrenal masses [Figure 2]. Bronchoscopic findings were nonspecific.

What Is the Diagnosis?

- A. Carcinoma lung with Mets
- B. Infective causes.

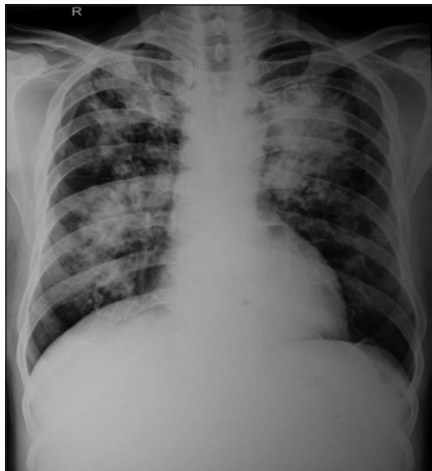


Figure 1: Chest X-ray posteroanterior view

Answer

- Histoplasmosis.

Fine needle aspiration cytology from both lung and adrenal glands showed uniform round-to-ovoid budding yeast surrounded by clear ring of space are seen intracellularly (in macrophages) as well as extracellularly. Background also shows chronic inflammatory cells. On periodic acid schiff (PAS) staining [Figure 3] and hematoxylin and eosin (H and E) staining [Figure 4], numerous capsulated yeasts such as fungal organism with budding were evident morphologically *Histoplasma* species.

Financial support and sponsorship

Nil.

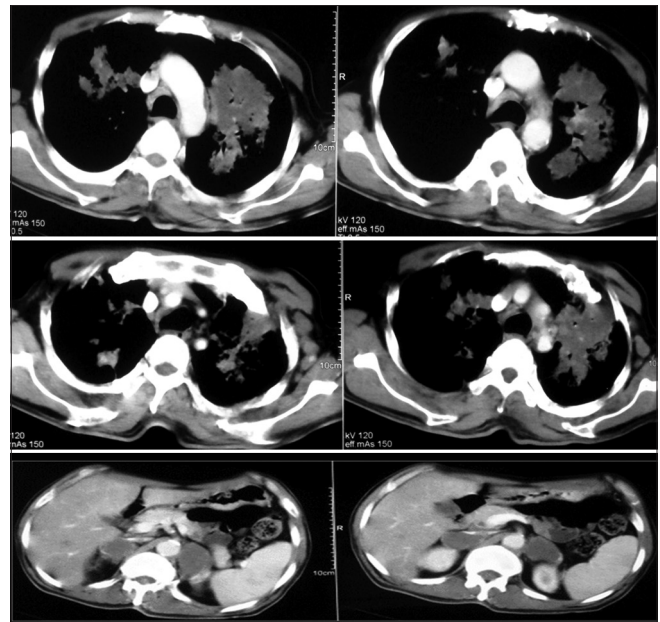


Figure 2: Chest and abdomen computed tomography

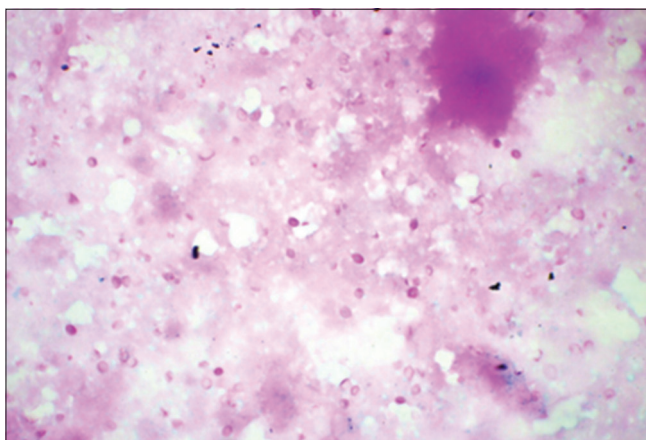


Figure 3: H and E, ×20

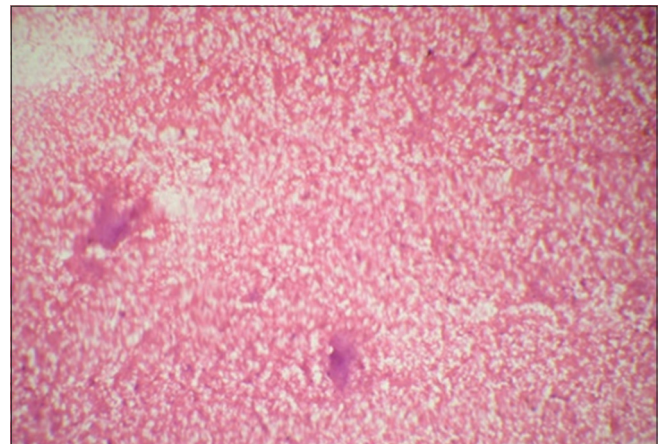


Figure 4: PAS, ×40

Conflicts of interest

There are no conflicts of interest.

Lokesh Kumar Rawat, Sunita Khandelwal¹, Hemant Dadhich²

Department of Radiodiagnosis, Shri Balaji Diagnostic Centre,

¹Department of Paediatrics, Government Medical College,

*²Department of Medical Oncology, Cancer Research Centre,
Kota, Rajasthan, India*

Address for correspondence:

Dr. Hemant Dadhich,

*Department of Medical Oncology, Cancer Research Centre,
Kota, Rajasthan, India.*

E-mail: hkdadhich@gmail.com

Submitted: 12-Nov-2019

Accepted in Revised Form: 18-Nov-2019

Published: 04-Dec-2019

This is an open access journal, and articles are distributed under the terms of the Creative Commons Attribution-NonCommercial-ShareAlike 4.0 License, which allows others to remix, tweak, and build upon the work non-commercially, as long as appropriate credit is given and the new creations are licensed under the identical terms.

Access this article online

Quick Response Code:



Website:

www.ijmpo.org

DOI:

10.4103/ijmpo.ijmpo_231_19

How to cite this article: Rawat LK, Khandelwal S, Dadhich H. A man with pulmonary and bilateral adrenal lesions. Indian J Med Paediatr Oncol 2019;40:432-3.