

Metaplastic Carcinoma of Breast: Case Series with Cytohistological Correlation

Abstract

Metaplastic carcinoma of breast (MCB) is a rare breast malignancy. It is important to differentiate metaplastic carcinoma from malignant phyllodes and primary breast sarcomas because of their differing biological behavior and prognosis. We report four cases of MCB diagnosed over the past 15 years. Retrospective review of patient records in a tertiary care setting to retrieve cases diagnosed as MCB. Patient records of the past 15 years (2002–2015) were retrieved. Four histopathologically diagnosed cases of metaplastic carcinoma out of a total of 880 archived cases of breast carcinoma were studied along with their cytopathology. Immunohistochemistry was performed on sections. MCB comprised 0.45% of all breast malignancies. The four cases of MCB included MCB with chondroid metaplasia, spindle cell carcinoma, adenosquamous carcinoma, and carcinosarcoma. All the tumors were invariably triple negative (estrogen receptor, progesterone receptor, and Her2/Neu negative) and expression of other epithelial and mesenchymal markers was variable. MCB is a rare breast malignancy. Differential diagnosis is related to the presence of heterologous elements and degree of atypia seen in the lesion. It is important to be aware of this entity as it carries a poor prognosis.

Keywords: Breast, carcinoma, fine-needle aspiration cytology, histopathology, immunohistochemistry, metaplastic

Introduction

The term metaplastic carcinoma of breast (MCB) was first introduced by Huvos *et al.*^[1] It comprises of two components, the usual ductal adenocarcinoma and the metaplastic component.^[2,3] It is a rare and aggressive subtype of breast carcinoma, with poor prognosis having reported incidence of 0.2%–0.6% of all breast cancers. MCB is not chemosensitive due to tumor heterogeneity and are also unresponsive to hormonal therapy.^[4,5]

We report a series of four cases of MCB, diagnosed over a 15-year period. Their cytohistologic features and immunohistochemical findings are presented in Table 1.

Methods

In this retrospective study in a tertiary care setting, patient records of 880 archived cases of breast carcinoma in the past 15 years (2002–2015), were retrieved. Four histopathologically diagnosed cases of metaplastic carcinoma out of a total of

880 archived cases of breast carcinoma were selected. Cytopathology reports were available in three of these cases. Immunohistochemistry (IHC) has been performed in all four cases.

Cytology had been performed by fine-needle aspiration and smears were processed using Giemsa and Papanicolaou stains. Histopathology sections were stained by standard H and E technique.

IHC was performed on paraffin tissue sections using the following monoclonal antibodies and standard staining protocols:

- Estrogen receptor (ER) (Biocare, RTU, SP1)
- Progesterone receptor (PR) (Biocare, RTU, SP2)
- Her2neu (Biocare, RTU, EP3)
- Cytokeratin (CK) 5/6 (Dako, RTU, D5/16B4)
- CK 7 (Biocare, RTU, OV-PL12/30)
- Epithelial membrane antigen (EMA) (Biocare, RTU, Mc5)
- Vimentin (Biocare, RTU, V9)
- S100 (Biocare, RTU, 15E2E2)
- CD 68 (Dako, RTU, PG-M1[3]).

A review was conducted to study the cytohistological correlation along

How to cite this article: Sood N, Gupta S, Navmeet S. Metaplastic carcinoma of breast: Case series with cytohistological correlation. *Indian J Med Paediatr Oncol* 2019;40:440-4.

Neelam Sood, Sanjay Gupta¹, Soin Navmeet²

Department of Pathology and Lab Medicine, Deen Dayal Upadhyay Hospital, Government of NCT, Hari Nagar, ²Department of Pathology, Deen Dayal Upadhyay Hospital, New Delhi, ¹Division of Cytopathology, National Institute of Cancer Prevention and Research, Noida, Uttar Pradesh, India

Submitted: 12-Dec-2017

Revised: 05-Mar-2019

Accepted: 19-Apr-2019

Published: 04-Dec-2019

Address for correspondence:

Dr. Neelam Sood,
Department of Pathology and Lab Medicine, Deen Dayal Upadhyay Hospital, Government of NCT, Hari Nagar, New Delhi, India.
E-mail: neesu1234@hotmail.com

Access this article online

Website: www.ijmpo.org

DOI: 10.4103/ijmpo.ijmpo_246_17

Quick Response Code:



This is an open access journal, and articles are distributed under the terms of the Creative Commons Attribution-NonCommercial-ShareAlike 4.0 License, which allows others to remix, tweak, and build upon the work non-commercially, as long as appropriate credit is given and the new creations are licensed under the identical terms.

For reprints contact: reprints@medknow.com

Table 1: Clinical, cytology, histopathology, and immunohistochemistry findings in the study cases

Case number	Age	Size and location of tumor	FNAC findings	Histopathology	Immunohistochemistry
1.	40	3 cm, firm irregular mass, LIQ	Large polyhedral to spindle pleomorphic cells with anisonucleosis lying in chondromyxoid background	Cellular areas of spindle cells around osteochondroid matrix Frequent mitoses Numerous OGCs and tumor giant cells	ER, PR, Her2/Neu negative EMA and CK positive in epithelial cells Vimentin and focal S-100 positive in spindle cells
2.	39	7 cm, ulcerated mass, UOQ	Dissociated pleomorphic spindle cells in an inflammatory background	Admixture of plump ovoid to polygonal cells, bizarre spindle cells and tumor giant cells Stroma hyalinized Frequent mitoses Necrosis+	ER, PR, Her2/Neu negative Vimentin+++ EMA and CK - focal positive
3.	25	5 cm, ulcerated mass, UOQ	FNA not done	Islands of large tumor cells separated by fibrous bands Focal squamous differentiation Tendency to form glandular structures	ER, PR, Her2/Neu negative CK +vein glandular component Pan Keratin and CK Positive in squamoid component
4.	28	3 cm, firm mass, UIQ	Dissociated ovoid to spindle pleomorphic cells with coarse nuclear chromatin abundant cytoplasm	Fascicles of pleomorphic spindle cells admixed with large epithelial cells OGCs and tumor giant cells++	ER, PR, Her2/Neu negative CK and EMA positive in epithelial cells Vimentin positive in spindle cells

FNAC – Fine-needle aspiration cytology; OGC – Osteoclast-like giant cells; ER – Estrogen receptor; PR – Progesterone receptor; EMA – Epithelial membrane antigen; CK – Cytokeratin; LIQ – Lower inner quadrant; UIQ – Upper inner quadrant; UOQ – Upper outer quadrant. Scoring of staining pattern of IHC

with the findings on IHC in these four cases diagnosed as MCB.

Results

The patient details, fine-needle aspiration cytology (FNAC), histopathology, and IHC findings in the four cases of MCB are summarized in Table 1.

Case 1

A 40-year-old female presented with a firm mass measuring 3 cm in lower inner quadrant of the breast. On FNAC A diagnosis of MCB with osteochondroid, differentiation was suggested.

Sections from the well-circumscribed mass in the modified radical mastectomy (MRM) specimen showed a nonencapsulated tumor with peripheral cellular areas and central abundant osteochondroid matrix. No ductal pattern could be identified. All lymph nodes (15/15) isolated from the specimen were negative for tumor metastases.

The tumor was triple negative (ER, PR, and Her2neu). The osteoclast-like giant cells (OGCs) expressed CD 68 while tumor giant cells stained negatively for CD 68. A final diagnosis of MCB with osteochondroid differentiation was made [Figure 1].

Case 2

A 39-year-old female presented with 7 cm ulcerated mass in upper outer quadrant left breast. FNA was reported as high-grade ductal carcinoma, breast (not otherwise specified [NOS]). MRM specimen showed ulcerated skin with gray-white to brown mass with necrotic and cystic areas. Sections showed highly vascular tumor comprising of admixture of plump ovoid to polygonal neoplastic cells, bizarre spindle-shaped cells, and multinucleated tumor giant cells separated by hyalinized and hemorrhagic stroma. Frequent no heterologous elements were identified. No lymph node metastasis was seen in 12/12 lymph nodes dissected from the tumor. The tumor was triple negative but was strongly positive for vimentin and focally positive for EMA and CK. The final diagnosis of MCB, sarcomatoid variant was offered [Figure 2].

Case 3

A 25-year-old female presented with an ulcerated mass measuring 5 cm in diameter, in upper outer quadrant of the right breast. FNA was not available in this case. Sections from MRM specimen showed ulcerated skin with subepithelium infiltrated by tumor cells with high nucleo-cytoplasmic ratio, moderate anisonucleosis, and abundant pale to dense eosinophilic cytoplasm (squamous

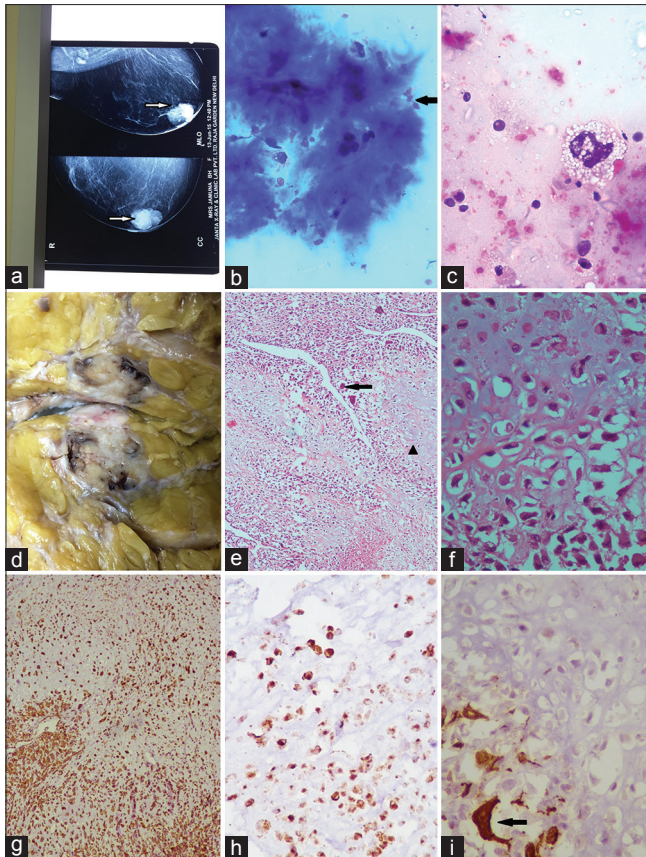


Figure 1: (a) Lobulated calcified mass (mammograph); (b) fine-needle aspiration smears showing chondroid matrix with peripheral spindle cells (arrow) Plump hyperchromatic cells with cytoplasmic vacuolization (c). ($\times 100$ Giemsa); (d) Gross excised firm mass measuring 3×3 cm; (e) Section showing lobulated masses of osteochondroid matrix (arrowhead) with peripheral osteoclastic giant cells (arrow) surrounded by pleomorphic ovoid to spindle-shaped cells. ($\times 100$); (f) High power view of the same. ($\times 400$); (g) Vimentin-positive spindle cells. ($\times 100$); (h) Focal cytokeratin 5 positivity. ($\times 400$); (i) CD 68 positivity of osteoclast-like giant cells (arrow). ($\times 400$)

differentiation). Overlying epidermis was free of tumor. All the lymph nodes (10) isolated from the axillary tail were free of tumor. The tumor was triple negative. The glandular component showed expression of CK7, and the squamoid component expressed pan-keratin and CK 5. Vimentin was not expressed in the tumor cells. The case was reported as adenosquamous carcinoma [Figure 3].

Case 4

A 28-year-old female presented with firm 3 cm mass in upper inner quadrant left breast. FNAC smears were signed out as “suggestive of a high-grade carcinoma.” Sections from the gray-white mass on MRM specimen showed proliferation of pleomorphic spindle-shaped cells in bundles and fascicles with interspersed large hyperchromatic epithelial cells. Tumor giant cells and multinucleated OGCs were also present. Only one out of 12 axillary lymph nodes showed metastatic carcinoma deposits. The tumor was triple negative on IHC. The final diagnosis of carcinosarcoma was given in Figure 4.

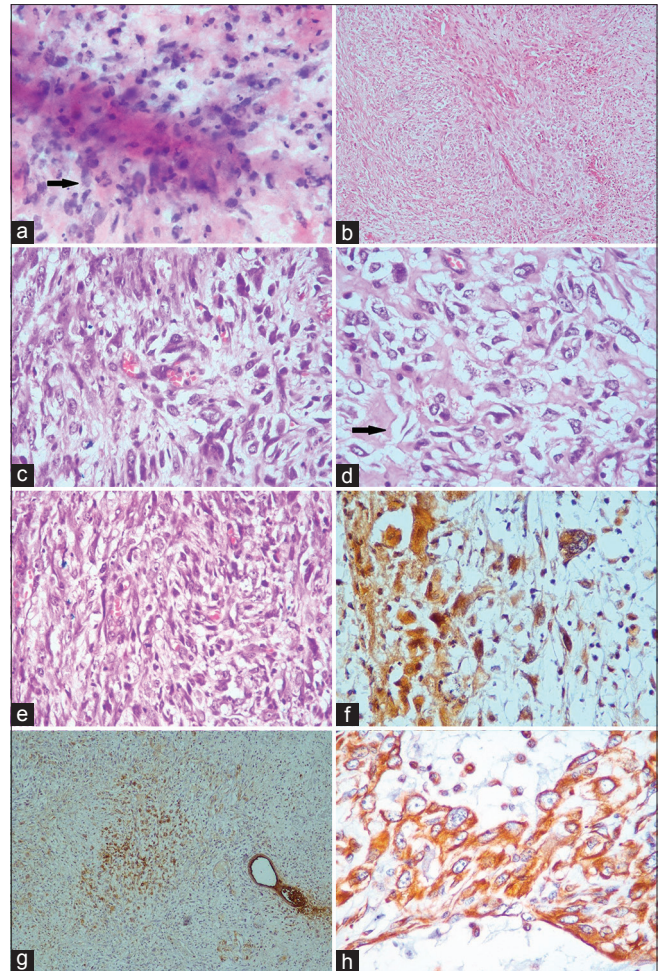


Figure 2: (a) Fine-needle aspiration smear showing proliferation of hyperchromatic spindle cells (arrow) in background of stroma and inflammatory cells. ($\times 400$); (b) Section showing proliferation of spindle cells and necrosis with rich vascularity. ($\times 100$); (c-e) spindle shaped cells with moderate to marked anisonucleosis and rich vascularity. ($\times 400$); (d) focal matrix and stromal hyalinization (arrow). ($\times 400$); (f) strong cyokeratin cytoplasmic expression. ($\times 400$); (g) Epithelial membrane antigen positivity with internal control ($\times 100$); (h) strong vimentin positivity. ($\times 400$)

Discussion

MCB is a rare heterogeneous tumor having areas of spindle, squamous, chondroid, or osseous elements in addition to the features of usual breast adenocarcinoma.^[1,4,6] Due to its heterogeneous nature, precise histological categorization has always been difficult, and these lesions have been given various confusing names.^[4,6] Five variants of MCB were suggested by Wargotz and Norris.^[7] Subsequently, the World Health Organization laid down the defining criteria for these variants^[2,8] [Table 2].

MCB usually presents in postmenopausal age group as a painless, large palpable mass; the median age at presentation being 47–61 years.^[4,5] However, in our series, all the cases were below 45 years. Local recurrence and lung metastasis are commonly seen in MCB while nodal metastases are comparatively less common (6%–26%) than

Table 2: World Health Organization classification of metaplastic carcinomas of breast, with diagnostic criteria

Broad categories	Subtypes	Diagnostic criteria
Purely epithelial	Squamous	Squamous component must be >90%
	Large cell nonkeratinizing	It should not arise from skin, nipple or any skin adnexal elements
	Spindle cell	There should be no other primary Squamous cell carcinoma
	Acantholytic	There should be no other ductal/mesenchymal neoplastic component
	Adenocarcinoma with spindle cell differentiation	Invasive adenocarcinoma with abundant spindle cells
Mixed epithelial mesenchymal	Adenosquamous including mucoepidermoid	CK7 positive negative
	Carcinoma with chondroid metaplasia	Adenocarcinomas with interspersed areas of squamous differentiation
	Carcinoma with osseous metaplasia	Infiltrating carcinoma with often heterologous mesenchymal component (e.g., chondroid, osteoid)
	Carcinosarcoma	Carcinosarcoma: When mesenchymal element is malignant

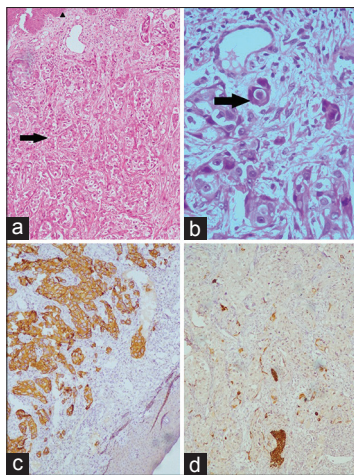


Figure 3: (a) Neoplastic cells (arrow) in nests with interspersed areas of squamous differentiation with overlying normal skin (arrowhead). ($\times 100$); (b) keratin pearls (arrow). ($\times 400$); (c) Strong cyokeratin 7 positivity. ($\times 400$); (d) Strong cyokeratin 5/6 positivity of squamous component. ($\times 400$)

invasive breast carcinoma NOS. The metastasis is most often by carcinomatous component.^[3,4]

The radiological features vary from well-defined to ill-defined and speculated, calcified to noncalcified as in the first case.^[3]

The histogenesis of MCB has been equally debatable, immunohistochemical studies, and electron microscopy point toward myoepithelial origin, whereas other studies have suggested its origin from multipotent undifferentiated cells.^[4,5,9]

Cytological diagnosis of MCBs is difficult due to morphological heterogeneity.^[9] The presence of pleomorphic cells in a background of amorphous/chondroid/osteoid material may be a helpful feature on FNA as was seen in Case 1 of the present series.^[5] In rest of the cases, FNAC could not diagnose MCB accurately, and a diagnosis of high-grade ductal carcinoma of breast was considered.

The histopathology of this lesion is characteristic, but lesions with high degree of atypia need to be

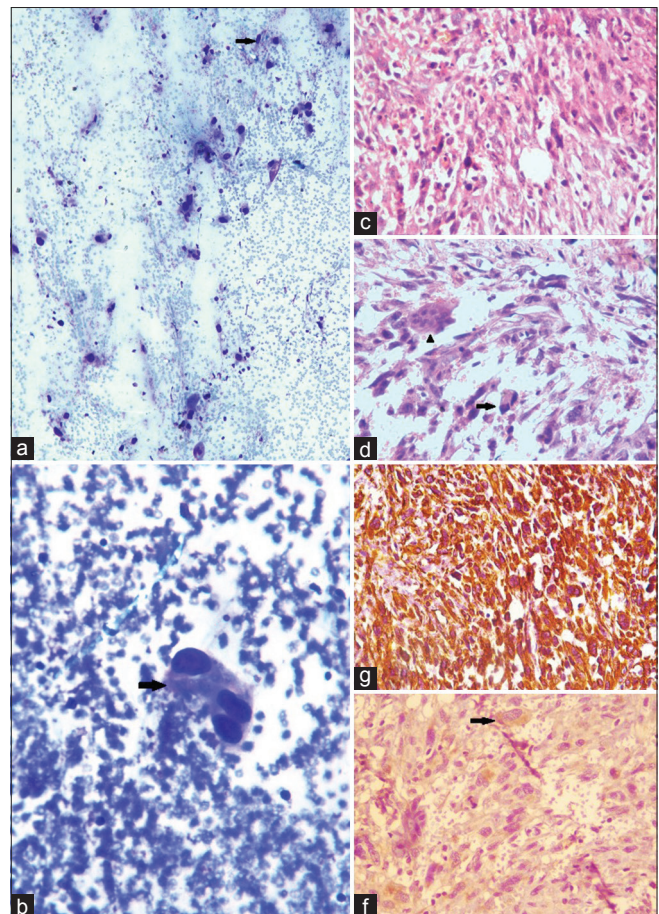


Figure 4: (a) Scattered and clustered neoplastic cells with hyperchromasia, anisonucleosis and spindly cytoplasm ($\times 100$); (b) higher magnification ($\times 400$); (c) Sections Show proliferation of pleomorphic spindle-shaped cells in bundles and fascicles with interspersed large hyperchromatic epithelial cells; (d) Tumor giant cells and multinucleated OG cells; (e) strong vimentin expression ($\times 400$); (f) CD68 expression in giant cells ($\times 400$)

differentiated from malignant phyllodes tumor (MPT), primary chondrosarcoma of breast and malignant adenomyoepithelioma. The presence of neoplastic epithelial cells in the former and demonstration of positivity for vimentin, S-100 protein and CKs 7, 8, and 19 is of

diagnostic importance. CK expression may be focal/patchy hence extensive sampling, and assessment may be required.^[5,6] These tumors are universally triple negative, as was also seen in all our cases.^[6]

The presence/absence of ordinary ductal carcinoma component is important in differentiating it from malignant myoepitheliomas. The absence of smooth muscle markers actin further assists in diagnosis.^[10]

OGCs have been reported in invasive ductal carcinoma. Carcinoma of breast with OGCs is now a separate entity and is characterized by the presence of OGCs admixed with usual picture of breast carcinoma. These are possibly represent a reactive infiltrate with a different origin than that of the carcinoma. In our study, these giant cells were noticed in Case 1 and 4.^[11,12]

Differential diagnosis of MCB with spindle cell component is related to the degree of atypia. Lesions with mild atypia need to be distinguished from exuberant scars, fibromatosis, nodular fasciitis, myofibroblastomas, and pseudoangiomatous stromal hyperplasia,^[6] whereas those with higher degree of atypia need to be differentiated from carcinosarcomas and primary breast sarcomas. Carcinomatous component demonstrated by CK immunopositivity of the neoplastic spindle cells favors diagnosis of MC.^[13]

MPT has leaf-like pattern, cellular overgrowth, stromal atypia, high mitotic rate (>10/10 hpf), and infiltrative borders along with lack of CK expression in spindle cells but benign epithelial component should be carefully searched for, using a broad panel of CKs. Expression of p53 and CD34 in spindle cells is used to differentiate this entity from spindle cell carcinoma.^[6]

A differential diagnosis of adenosquamous carcinoma must be considered in cases of MCB with squamous differentiation. Demonstration of a dual pattern of pan CKs and vimentin expression is needed to clinch the diagnosis, as was seen in Case 3. p63 antibody positivity is near confirmatory of adenosquamous differentiation. Squamous component ranges from poorly differentiated nonkeratinizing to well differentiated, keratinizing. Squamous component is triple negative however the ductal component may show positivity to ER, PR depending on its differentiation.^[2] MCB has a high potential for local recurrence; hence, aggressive local treatment is recommended.^[14,15]

Financial support and sponsorship

Nil.

Conflicts of interest

There are no conflicts of interest.

References

- Huvos AG, Lucas JC Jr, Foote FW Jr. Metaplastic breast carcinoma. Rare form of mammary cancer. *N Y State J Med* 1973;73:1078-82.
- Ellis IO, Schnitt SJ, Sastre-Garau X, Bussolati G, Tavassoli FA, Eusebi V, *et al.* Invasive breast carcinoma. In: Tavassoli FA, Devilee P, editors. *WHO Classification of Tumors of the Breast*. Lyon, France: IARC; 2003. p. 37-40.
- Tavassoli FA. Classification of metaplastic carcinomas of the breast. *Pathol Annu* 1992;27 Pt 2:89-119.
- Al Sayed AD, El Weshi AN, Tulbah AM, Rahal MM, Ezzat AA. Metaplastic carcinoma of the breast clinical presentation, treatment results and prognostic factors. *Acta Oncol* 2006;45:188-95.
- Rossi L, Paglicci C, Caprio G, Barberi S, Ranieri E, Zancla S, *et al.* Matrix-producing carcinoma of the breast: A case report. *Case Rep Oncol* 2013;6:245-9.
- Rungta S, Kleer CG. Metaplastic carcinomas of the breast: Diagnostic challenges and new translational insights. *Arch Pathol Lab Med* 2012;136:896-900.
- Wargotz ES, Norris HJ. Metaplastic carcinomas of the breast: V. Metaplastic carcinoma with osteoclastic giant cells. *Hum Pathol* 1990;21:1142-50.
- Graziano L, Filho GP, Bitencourt AG, Soto DB, Hiro A, Nunes CC, *et al.* Metaplastic squamous cell carcinoma of the breast: A case report and literature review. *Rev Assoc Med Bras (1992)* 2016;62:618-21.
- Joshi D, Singh P, Zonunfawni Y, Gangane N. Metaplastic carcinoma of the breast: Cytological diagnosis and diagnostic pitfalls. *Acta Cytol* 2011;55:313-8.
- Papazian M, Kalantzis I, Galanopoulos G, Mani I, Tzaida O, Iacovidou I, *et al.* Malignant myoepithelioma of the breast: A case report and review of the literature. *Mol Clin Oncol* 2016;4:723-7.
- Niu Y, Liao X, Li X, Zhao L. Breast carcinoma with osteoclastic giant cells: Case report and review of the literature. *Int J Clin Exp Pathol* 2014;7:1788-91.
- Neelam S, Sanjay G. Invasive duct carcinoma of the breast with multinucleated osteoclast-like giant cells: A rare case diagnosed on fine needle aspiration cytology. *Breast J* 2012;18:596-7.
- Adem C, Reynolds C, Ingle JN, Nascimento AG. Primary breast sarcoma: Clinicopathologic series from the mayo clinic and review of the literature. *Br J Cancer* 2004;91:237-41.
- Tse GM, Tan PH, Putti TC, Lui PC, Chaiwun B, Law BK, *et al.* Metaplastic carcinoma of the breast: A clinicopathological review. *J Clin Pathol* 2006;59:1079-83.
- Altaf FJ, Mokhtar GA, Emam E, Bokhary RY, Mahfouz NB, Al Amoudi S, *et al.* Metaplastic carcinoma of the breast: An immunohistochemical study. *Diagn Pathol* 2014;9:139.