

## An Alternate Method of Fabrication of an Obturator in a Patient Diagnosed with Melanotic Neuroectodermal Tumor of Infancy

### Abstract

The quality of treatment and rehabilitation for the pediatric head and neck cancer patient has greatly improved due to interdisciplinary management. Surgical resection of maxilla leads to functional impairment which can be adequately restored with an obturator. However, its fabrication can be challenging in a pediatric patient. A simple, practical, and time-saving procedural modification in the fabrication of obturator in a patient diagnosed with rare melanotic neuroectodermal tumor of infancy has been presented.

**Keywords:** *Interdisciplinary care, melanotic neuroectodermal tumor of infancy, modification, obturator, time-saving*

### Introduction

Melanotic neuroectodermal tumor of infancy (MNTI) has been categorized as “rare clinical entity” by “Office of Rare Diseases” of National Institute of Health. It is a melanin-producing neoplasm which primarily affects maxilla during 1<sup>st</sup> year of life.<sup>[1]</sup>

Although benign, MNTI has been documented to be locally aggressive, resulting in tooth displacement, adjacent bone invasion, and impairment of oral functions such as feeding and sucking.<sup>[2]</sup> Multidisciplinary management includes surgical removal of the tumor mass followed by restoration of oral function with an obturator.

The current report is documentation of novel, simple, and practical approach in the fabrication of an obturator in a growing child.

### Case Report

#### Previous medical history

A 2½-month-old infant presented with sudden onset and progressive left facial swelling. A 3 cm × 3 cm well-circumscribed, nonfluctuant mass was seen in the left maxilla, protruding into oral cavity. Computerized tomographic scan revealed an expansive lytic lesion involving left maxilla associated with significant peripheral sclerosis and displacement of deciduous teeth.

This is an open access journal, and articles are distributed under the terms of the Creative Commons Attribution-NonCommercial-ShareAlike 4.0 License, which allows others to remix, tweak, and build upon the work non-commercially, as long as appropriate credit is given and the new creations are licensed under the identical terms.

For reprints contact: reprints@medknow.com

Incisional biopsy was indicative of MNTI. Immunohistochemical (IHC) analysis was positive for HMB-45 and cytokeratin and equivocal for S-100.

In view of vast tumor spread and focal areas of ulceration, radical surgery was planned. Left total maxillectomy was carried out, and surgical defect was lined with partial thickness skin graft. On sufficient healing, an interim maxillary obturator was given to the patient.

At present, the patient reported to the department at an age of three, with his parents with a complaint of nasal seepage of liquids due to lack of retention of the obturator.

#### Examination

Intraoral examination revealed well-healed, skin graft-lined total maxillectomy defect on left side [Figure 1]. Deciduous canine and molars had erupted with evidence of erupting deciduous right central incisor. The existing obturator had become loose owing to infantile growth spurt. Eruption of deciduous teeth had rendered an incomplete seating of the obturator.

#### Procedure of fabrication of an interim obturator

Existing obturator was duplicated in form and used as a custom tray [Figure 2].

**How to cite this article:** Dholam KP, Singh GP, Gurav SV, Shinde AA. An alternate method of fabrication of an obturator in a patient diagnosed with melanotic neuroectodermal tumor of infancy. *Indian J Med Paediatr Oncol* 2019;40:S148-51.

**Kanchan P Dholam,  
Gurkaran Preet Singh<sup>1</sup>,  
Sandeep V Gurav,  
Arati A Shinde**

*Department of Dental and Prosthetic Surgery, Tata Memorial Hospital, Mumbai, <sup>1</sup>Dental and Prosthetic Services, Tata Memorial Centre-Advanced Centre for Treatment, Research and Education in Cancer (TMC-ACTREC), Kharghar, Navi Mumbai, Maharashtra, India*

**Address for correspondence:**  
*Dr. Gurkaran Preet Singh,  
Dental and Prosthetic Services,  
Tata Memorial Centre-  
Advanced Centre for Treatment,  
Research and Education in  
Cancer (TMC-ACTREC),  
Kharghar, Navi Mumbai - 410  
210, Maharashtra, India.  
E-mail: gurkaranpreetsingh@  
gmail.com*

Access this article online

Website: [www.ijmpo.org](http://www.ijmpo.org)

DOI: 10.4103/ijmpo.ijmpo\_256\_17

Quick Response Code:



Height of the bulb was reduced, and tray was relieved all around by 1–1.5 mm. A handle was attached to enable accurate and convenient seating in the mouth.

The tray was verified for border extensions, and impression of maxillectomy defect was made with polyvinyl siloxane (PVS) impression material (Aquasil Soft Putty™ and Aquasil LV™, Dentsply International, Pennsylvania, United States). Putty material was molded and placed on the bulb and light body PVS loaded onto remaining portion of the tray. A thin layer of light body material was applied over putty to record fine details of the defect. The child was stabilized and tray carefully placed in the mouth. On reaching final set of the material, the impression was removed from the mouth and inspected for errors and inaccuracies [Figure 3]. It was poured in Type III dental stone (Ultrastone™, Kalabhai Pvt. Ltd., Mumbai, India) to obtain master cast [Figure 4]. The defect area was outlined on the cast and medial undercut was blocked. Subsequently, an interim maxillary obturator was fabricated in polymethyl-methacrylate resin (DPI Heat Cure, Dental Products of India Pvt Ltd., Mumbai, India). A relief was designed in the obturator to accommodate erupting

deciduous right central incisor [Figure 5]. The obturator was finished, polished, and delivered to the patient [Figure 6]. Parents were instructed about maintenance of the prosthesis and importance of regular follow-up visits to facilitate frequent adjustments.

### Discussion

MNTI is a rare clinical entity and usually affects infants in first 6 months of life with a mean age of presentation of 4.3 months.<sup>[3,4]</sup> It has no gender predilection though Kruse–Losler reported a male-to-female ratio of 1.48.<sup>[5]</sup> It is a rapidly-growing, nonulcerative enlarging mass that usually affects anterior maxilla. It has also been reported in other sites of head and neck region such as skull, mandible, and brain.<sup>[4]</sup>

Many investigators have proposed numerous theories regarding tumor histogenesis which has resulted in its varied nomenclature.<sup>[6–10]</sup> Current nomenclature of MNTI which reflects its neural crest cell origin is widely accepted and recognized by WHO.<sup>[11]</sup>

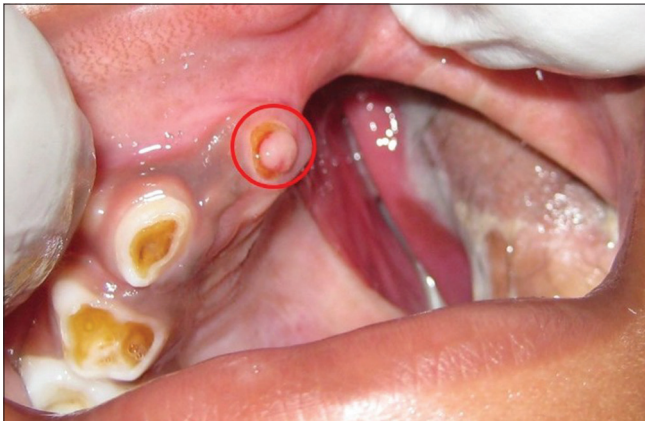


Figure 1: Intraoral view of well-healed maxillectomy defect with red circle showing erupting deciduous incisor

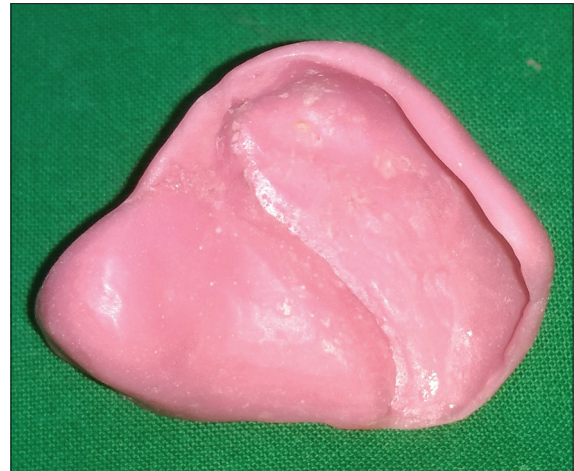

Figure 2: Custom tray obtained by duplicating the existing prosthesis

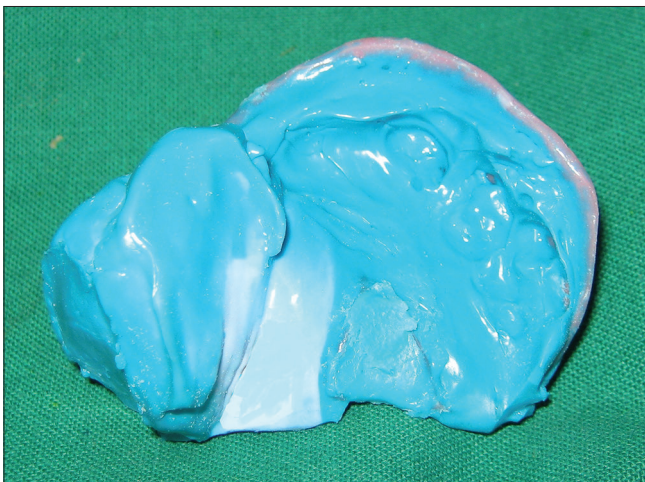

Figure 3: Definitive elastomeric impression

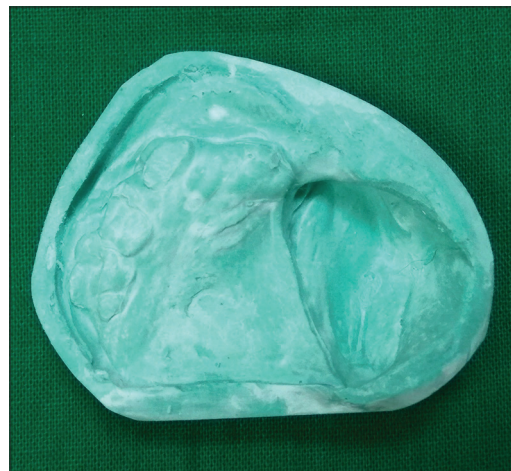

Figure 4: Master cast



Figure 5: Final prosthesis with red circle showing provision to accommodate erupting deciduous incisor

Radiologically, the tumor is osteolytic in appearance with adjoining deciduous teeth appearing to be “floating” within the lesion.<sup>[12]</sup>

Histologically, it shows dual cellular pattern with large melanin-containing polygonal cells arranged in alveolar or tubular structures and small neuroblast-like cells with hyperchromatic nucleus and scanty neoplasm in dense fibrous stroma. IHC markers such as HMB-45, neuron specific enolase, CD 56, synaptophysin, and chromogranin have been proposed to have a positive association with MNTI.<sup>[6]</sup>

Despite aggressive clinical presentation, the prognosis is good and curative surgery is treatment of choice. The probability of recurrence is maximum in first 6–18 months; hence, periodic follow-up is highly recommended.<sup>[1]</sup> The presented case has been on regular follow-up since 3 years and shown excellent locoregional control.

Multidisciplinary management of MNTI is essential as radical surgery impairs essential oral functions such as feeding, mastication, and speech. Interdisciplinary care reduces posttreatment morbidity by providing efficient rehabilitation during critical growth period of the pediatric patient.<sup>[13]</sup>

Maxillary obturator helps in restoring palatal contours and sealing margins of maxillary defect.<sup>[13]</sup> The exercise of recording maxillary defect during dual impression-making can be quite tedious and traumatic for a pediatric patient. In this report, existing obturator was duplicated and sufficiently relieved to act as a custom tray. This was time-saving and allowed us to forego the procedure of making preliminary impression. In addition, it enabled the construction of a well-fitted custom tray which was well tolerated by the child. Such procedural modification greatly improved patient compliance and facilitated prosthesis delivery within a day. An opening was created in the prosthesis

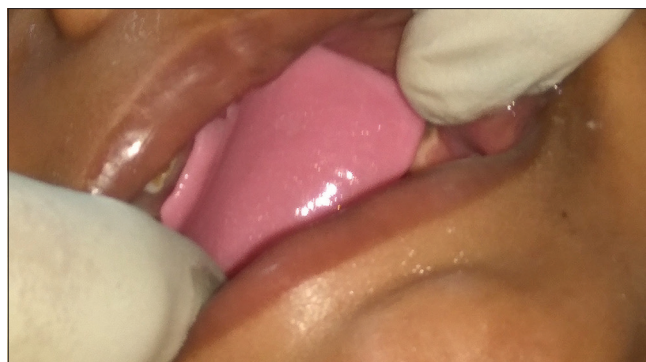


Figure 6: Interim obturator *in situ*

corresponding to erupting deciduous incisor to allow unimpeded eruption.

## Conclusion

The current report throws light on the significance of interdisciplinary management of a rare pediatric solid tumor such as MNTI. A simple, practical, and time-saving procedural modification in the fabrication of obturator for a pediatric patient has been presented. In addition, it stresses on the need to accommodate erupting teeth by necessary adjustment of the prosthesis which is critical in a growing child.

## Declaration of patient consent

The authors certify that they have obtained all appropriate patient consent forms. In the form the patient(s) has/have given his/her/their consent for his/her/their images and other clinical information to be reported in the journal. The patients understand that their names and initials will not be published and due efforts will be made to conceal their identity, but anonymity cannot be guaranteed.

## Financial support and sponsorship

Nil.

## Conflicts of interest

There are no conflicts of interest.

## References

- Rodriguez-Galindo C, Furman WL, Pappo AS. Rare pediatric tumors. In: Pizzo PA, Poplack DG, editors. Principles and Practice of Pediatric Oncology. 7<sup>th</sup> ed. Philadelphia: Wolters Kluwer; 2016. p. 946-7.
- Reddy ER, Kumar MS, Aduri R, Sreelakshmi N. Melanotic neuroectodermal tumor of infancy: A rare case report. Contemp Clin Dent 2013;4:559-62.
- Neven J, Hulsbergen-van der Kaa C, Groot-Loonen J, de Wilde PC, Merckx MA. Recurrent melanotic neuroectodermal tumor of infancy: A proposal for treatment protocol with surgery and adjuvant chemotherapy. Oral Surg Oral Med Oral Pathol Oral Radiol Endod 2008;106:493-6.
- Rajendran R. Benign and malignant tumors of oral cavity. In: Rajendran R, Sivapathasundhram B, editors. Shafer's Textbook of Oral Pathology. 5<sup>th</sup> ed. New Delhi: Elsevier; 2006. p. 283-5.

5. Kruse-Lösler B, Gaertner C, Bürger H, Seper L, Joos U, Kleinheinz J, *et al.* Melanotic neuroectodermal tumor of infancy: Systematic review of the literature and presentation of a case. *Oral Surg Oral Med Oral Pathol Oral Radiol Endod* 2006;102:204-16.
6. Pattanayak S, Ray JG, Mukherjee RS, Mandal C, Chaudhuri K. Melanotic neuroectodermal tumour of infancy. *BMJ Case Rep* 2010;2010. pii:bcr0120102645.
7. Stowens D. A pigmented tumour of infancy – The melanotic progonoma. *J Patol Bact* 1957;73:43.
8. Bernier JL, Tiecke RW. Melanotic ameloblastoma. *Oral Surg Oral Med Oral Pathol* 1956;9:1197-209.
9. Henry TC, Bodian M. A case of pigmented congenital epulis. *Br J Surg* 1960;47:574-6.
10. Halpert B, Patzer R. Maxillary tumor of retinal anlage. *Surgery* 1947;22:837-41.
11. Madrid C, Aziza J, Hlali A, Bouferrache K, Abarca M. Melanotic neuroectodermal tumour of infancy: A case report and review of the aetiopathogenic hypotheses. *Med Oral Patol Oral Cir Bucal* 2010;15:e739-42.
12. Batsakis JG. Pathology consultation. Melanotic neuroectodermal tumor of infancy. *Ann Otol Rhinol Laryngol* 1987;96:128-9.
13. Martin JW, Chambers MS, Lemon JC, Toth BB, Helfrick JF. Prosthodontic and surgical considerations for pediatric patients requiring maxillectomy. *Pediatr Dent* 1995;17:116-21.