

MUC2 and MUC5AC Expression in Colon Cancer: A Preliminary Report from South India

Abstract

Background: There is scanty data from India regarding MUC protein expression from colorectal cancers (CRC) among Indian patients. **Aim of the Study:** The aim of this study is to assess the alterations in the expression of MUC2 and MUC5AC in 25 patients with CRC by site of the tumor location and differentiation at histology. **Materials and Methods:** Patients with proven adenocarcinoma of the colon alone were included for the study. Biopsy specimens obtained from tumorous lesions in the colon were classified based on histopathology as well differentiated, moderately, and poorly differentiated adenocarcinoma. Immunohistochemistry was done in the 4 µm thick sections to identify the expression of MUC2 and MUC5AC mucins. **Results:** MUC2 was uniformly expressed with near similar intensity while MUC5 was moderately (56%) to highly expressed (36%) in mucinous tumors. In nonmucinous tumors, MUC2 was least expressed (68%) with a significant expression on MUC5AC (88%). Except for rectosigmoid growth which had greater expression of MUC5AC (31%), both proximal and distal carcinomas had significant MUC2 and MUC5AC expression. **Conclusion:** MUC2 and MUC5AC are expressed in colonic cancers, the former showing mild to moderate expression and the latter moderate to intense expression. The expression is more in mucinous adenocarcinoma.

Keywords: Cancer, colon, India, mucin

Introduction

One of the strongest prognostic parameter in colorectal cancer (CRC) is tumor node metastasis staging and is currently used as a guide to patient management. However, biological behavior of the tumor with same pathological grading may have different clinical outcomes, and hence, there is a need for identifying other prognostic markers that can stratify patients for different therapeutic and surveillance strategies.

Epithelial surfaces, including the colonic epithelium, are covered and protected by mucus, of which the major glycoprotein constituents are mucins, large carbohydrate-rich glycoproteins. Besides their protective function in the normal colon, alterations in mucin are a common feature of colonic neoplasia.^[1] Expression profiles of mucin may play a role in prognosis and tumor phenotypes.^[2]

Mucins are high-molecular-weight glycoproteins expressed by epithelial tissues and are synthesized throughout

the gastrointestinal tract (GIT) by the epithelial cells and form a protective barrier on the surface. Constituents of mucin include clustered oligosaccharides. They form a mucosal protecting system on the surface of the GIT. Recent studies have characterized the mucin protein. Since the initial characterization of cDNA sequences of MUC1^[3-5] and MUC2,^[6] several genes encoding mucin proteins have been identified and named chronologically as MUC1 through MUC17.

Several types of MUC proteins have been described. These include secreted gel-forming mucins (MUC2, MUC5AC, and MUC6), transmembrane mucins (MUC1), and others that do not fit into either of the two classes. Organ-specific mucin has been identified. MUC1 is expressed in apices of most epithelial cells.^[7] MUC2, for example, is present in the goblet cells of the small and large intestine, MUC5AC, and MUC6 are especially expressed in the gastric epithelium and rarely in the colon.^[4-6]

During a neoplastic transformation or progression of a benign polyp to a

Jayanth R¹,
Devaraj H²,
Surendran R¹,
Mayank Jain³,
Jayanthi
Venkataraman^{1,3}

¹Department of Medical and Surgical Gastroenterology, Stanley Medical College and Hospital, ²Glycotechnology Centre, AC Tech, University of Madras, ³Gleneagles Global Health City, Chennai, Tamil Nadu, India

Submitted: 09-Feb-2018

Revised: 01-Mar-2018

Accepted: 12-Sep-2018

Published: 04-Dec-2019

Address for correspondence:

Dr. Mayank Jain,
Gleneagles Global Health City,
Chennai - 600 100, Tamil Nadu,
India.

E-mail: mayank4670@rediffmail.com

Access this article online

Website: www.ijmpo.org

DOI: 10.4103/ijmpo.ijmpo_33_18

Quick Response Code:



How to cite this article: Jayanth R, Devaraj H, Surendran R, Jain M, Venkataraman J. MUC2 and MUC5AC expression in colon cancer: A preliminary report from South India. Indian J Med Paediatr Oncol 2019;40:402-5.

This is an open access journal, and articles are distributed under the terms of the Creative Commons Attribution-NonCommercial-ShareAlike 4.0 License, which allows others to remix, tweak, and build upon the work non-commercially, as long as appropriate credit is given and the new creations are licensed under the identical terms.

For reprints contact: reprints@medknow.com

malignant one, expression of specific mucins can be reduced or the organ specificity may be lost, and still more, there may be an aberrant expression of new mucins. For example, MUC5AC can be aberrantly expressed by colorectal polyps and carcinoma. It has been hypothesized that aberrant expression of MUC5AC in CRC tissues increased the overall survival of these patients. Mucin 2 (MUC2) is known to undergo significant changes during malignant transformation of colorectal tumor.^[8] While MUC2 downregulation is noted in nonmucinous adenocarcinomas, there is upregulation of MUC2 in mucinous adenocarcinomas.

Our study aimed to assess the alterations in the expression of MUC2 and MUC5AC in 25 patients with CRC by site of the tumor location and differentiation at histology. These were compared with five healthy controls.

Materials and Methods

Patients with proven adenocarcinoma of the colon alone were included for the study. Biopsy specimens obtained from tumorous lesions in the colon were classified based on histopathology as well differentiated, moderately, and poorly differentiated adenocarcinoma. Immunohistochemistry was done in the 4 µm thick sections to identify the expression of MUC2 and MUC5AC mucins. The slides were dewaxed in xylene and treated in descending grades of ethanol (100%, 90%, 70%, 50%, and 30%). The sections were then treated with 3% hydrogen peroxide in methanol. Antigen retrieval was done in citrate buffer (pH-6.0) for 5 min followed by blocking with 3% bovine serum albumin in phosphate-buffered saline (PBS). The sections were probed with the respective primary antibodies for MUC2 and MUC5AC [Flowchart 1].

After an overnight incubation at 4°C, the tissues were washed in PBS and then incubated with Horseradish Peroxidase conjugated secondary antibody for 1 h at room temperature. The antigen-antibody reaction was visualized using 3,3'-diaminobenzidine chromogen in dim conditions. Counterstaining was done using hematoxylin. The slides were then dehydrated in an ascending series of ethanol (30%, 50%, 70%, 90%, and 100%), cleared in xylene and mounted. After drying, the sections were visualized in Axioscope Two Plus Microscope (Carl Zeiss).

The results of the staining were semi-quantitatively evaluated for the percentage and intensity of the positive cells. An intensity value of -, +, ++, and +++ were classified as negative, mild, moderate, and intense, respectively [Figure 1a-c].

Ethics committee of the institution approved the study.

Results

The mean age of the 25 patients with CRC was 51 years. Men outnumbered the women in a ratio of 3:1. All had proven adenocarcinoma.

Immunohistochemical analysis of MUC2 and MUC5AC expression

Among healthy controls, all five participants showed MUC2 expression, and none showed MUC5AC expression. MUC2 was uniformly expressed with near similar intensity while MUC5 was moderately (56%) to highly expressed (36%) in mucinous tumors. In nonmucinous tumors, MUC2 was least expressed (68%) with significant expression on MUC5AC (88%) [Figure 1 and Table 1].

MUC expression based on location and histology (mucinous versus nonmucinous)

Of the 25 patients with CRC, 13 (52%) were localized to the rectosigmoid region, and 24% each in proximal-caecum and ascending colon (6) and distal-transverse and descending colon (6). Irrespective of mucinous (28%) or nonmucinous (72%) nature of tumour, except for rectosigmoid growth which had greater expression of MUC5AC (31%), both proximal (100%) and distal carcinomas (50%–67%) had a significant MUC2 and MUC5AC expression [Table 2].

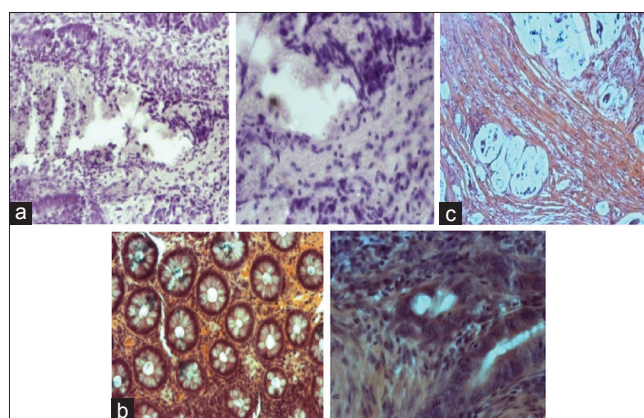


Figure 1: (a) Nonmucinous colorectal cancer probed for MUC2 and MUC5AC (b) Mucinous colorectal cancer showing MUC5AC expression (c) Mucinous colorectal cancer MUC 2 expression


Table 1: Mucin expression in mucinous and mucinous carcinomas

	Type	Intensity of expression			
		-	+	++	+++
Mucinous	MUC 2	None	7 (28)	8 (32)	10 (40)
	MUC 5AC	None	2 (8)	14 (56)	9 (36)
Nonmucinous	MUC 2	None	17 (68)	7 (28)	1 (4)
	MUC 5AC	None	3 (12)	14 (56)	8 (32)

-- Negative; + - mild; ++ - moderate; +++ - intense

Table 2: Mucin expression based on location and mucin production

	Proximal colon (6)	Distal colon (6)	Rectosigmoid (13)
MUC 2 (%)	6 (100)	4 (67)	3 (23)
MUC 5AC (%)	6 (100)	3 (50)	4 (31)
MUC2 + MUC5AC (%)	4 (67)	2 (33.3)	2 (15)



Flowchart 1: Flowchart for the data flow

Discussion

Most organs in our body seem to synthesize more than one type of mucin, although a particular mucin type may predominate in a particular organ. One common characteristic of gastrointestinal tumors is loss of this organ specificity. For example, there is an aberrant expression of gastric-type mucin (MUC5AC) in colorectal adenomas, a precursor of some colon cancers, and aberrant expression of colonie-type mucin (MUC2) in gastric intestinal metaplasia, a precursor of some gastric cancers. Immunohistochemistry is a widely accepted and well-documented method for characterizing patterns of protein expression while preserving tissue and cellular architecture.^[7]

In the present study, normal colonic specimens showed MUC2 expression. In colonic carcinoma, majority had mild-to-moderate expression and only one showed intense expression. In addition, MUC2 expression was decreased in nonmucinous colorectal adenocarcinoma, but preserved in mucinous carcinomas. This finding is consistent with other studies.^[9-12] A reduced MUC2 expression in colon cancer contributes to the prosurvival pathway in cells; MUC2 staining is inversely associated with p53 expression in mucinous carcinoma,^[13] the latter regulates MUC2 transcription.

None of the normal participants showed MUC5AC expression. Majority of the cases (88%) showed moderate-to- high expression, especially in mucinous carcinomas. MUC5AC is usually expressed in well-differentiated tumors^[9,14] and correlates with better survival.

Recent studies have correlated MUC expressions with the tumor invasion and location. Expression of MUC2, MUC5AC, and MUC6 was strongly associated with features associated with tumorigenesis through the serrated neoplasia pathway, proximal location, poor differentiation, lymphocytic response, and increased T stage (all $P < 0.001$).^[15]

Correlation of proximal location with MUC 2 and MUC5AC expression is noted in the present study too. Loss

of MUC2 expression has been reported to be a predictor of adverse outcome. Aberrant expression of MUC5AC and MUC6 have been associated with favorable outcome in CRC.^[16]

The present study highlights MUC protein with special reference of MUC2 and MUC5AC in colonic cancers, the former showing mild-to-moderate expression and the latter moderate-to-intense expression and more so in mucinous adenocarcinoma. The present study was essentially a cross-sectional study and did not aim at a serial follow-up of our patients. Future studies can enlighten on its role as a marker in predicting invasiveness, prognostication, and survival benefits. Further, profiling of MUC expression may be helpful for histological subtyping and in the development of future targeted therapies.

Financial support and sponsorship

Nil.

Conflicts of interest

There are no conflicts of interest

References

- Byrd JC, Bresalier RS. Mucins and mucin binding proteins in colorectal cancer. *Cancer Metastasis Rev* 2004;23:77-99.
- Aksoy N, Corfield AP, Sheehan JK. Preliminary study pointing out a significant alteration in the biochemical composition of MUC2 in colorectal mucinous carcinoma. *Clin Biochem* 2000;33:167-73.
- Gendler SJ, Lancaster CA, Taylor-Papadimitriou J, Duhig T, Peat N, Burchell J, et al. Molecular cloning and expression of human tumor-associated polymorphic epithelial mucin. *J Biol Chem* 1990;265:15286-93.
- Lan MS, Batra SK, Qi WN, Metzgar RS, Hollingsworth MA. Cloning and sequencing of a human pancreatic tumor mucin cDNA. *J Biol Chem* 1990;265:15294-9.
- Ligtenberg MJ, Vos HL, Gennissen AM, Hilkens J. Episialin, a carcinoma-associated mucin, is generated by a polymorphic gene encoding splice variants with alternative amino termini. *J Biol Chem* 1990;265:5573-8.
- Gum JR, Byrd JC, Hicks JW, Toribara NW, Lampert DT, Kim YS, et al. Molecular cloning of human intestinal mucin cDNAs. Sequence analysis and evidence for genetic polymorphism. *J Biol Chem* 1989;264:6480-7.
- Taylor CR. Standardization in immunohistochemistry: The role of antigen retrieval in molecular morphology. *Biotech Histochem* 2006;81:3-12.
- Velcich A, Yang W, Heyer J, Fragale A, Nicholas C, Viani S, et al. Colorectal cancer in mice genetically deficient in the mucin muc2. *Science* 2002;295:1726-9.
- Bu XD, Li N, Tian XQ, Li L, Wang JS, Yu XJ, et al. Altered expression of MUC2 and MUC5AC in progression of colorectal carcinoma. *World J Gastroenterol* 2010;16:4089-94.
- Farhat MH, Barada KA, Tawil AN, Itani DM, Hatoum HA, Shamseddine AI, et al. Effect of mucin production on survival in colorectal cancer: A case-control study. *World J Gastroenterol* 2008;14:6981-5.
- Voloshanenko O, Erdmann G, Dubash TD, Augustin I, Metzigg M, Moffa G, et al. Wnt secretion is required to maintain high levels of Wnt activity in colon cancer cells. *Nat Commun*

- 2013;4:2610.
12. Ookawa K, Kudo T, Aizawa S, Saito H, Tsuchida S. Transcriptional activation of the MUC2 gene by p53. *J Biol Chem* 2002;277:48270-5.
 13. Lugli A, Zlobec I, Baker K, Minoo P, Tornillo L, Terracciano L, *et al.* Prognostic significance of mucins in colorectal cancer with different DNA mismatch-repair status. *J Clin Pathol* 2007;60:534-9.
 14. Kocer B, Soran A, Erdogan S, Karabeyoglu M, Yildirim O, Eroglu A, *et al.* Expression of MUC5AC in colorectal carcinoma and relationship with prognosis. *Pathol Int* 2002;52:470-7.
 15. Walsh MD, Clendenning M, Williamson E, Pearson SA, Walters RJ, Nagler B, *et al.* Expression of MUC2, MUC5AC, MUC5B, and MUC6 mucins in colorectal cancers and their association with the cpG island methylator phenotype. *Mod Pathol* 2013;26:1642-56.
 16. Betge J, Schneider NI, Harbaum L, Pollheimer MJ, Lindtner RA, Komprat P, *et al.* MUC1, MUC2, MUC5AC, and MUC6 in colorectal cancer: Expression profiles and clinical significance. *Virchows Arch* 2016;469:255-65.