

## Case Report

# Nasal reconstruction with pre-laminated forehead flap

**Prasanna N. S.**

Tanvi Plastic Surgery Centre, Shimoga, Karnataka, India

**Address for correspondence:** Dr. Prasanna N. S, Tanvi Plastic Surgery Centre, Kuvempu Road, Mission Compound, Shimoga - 577 201, Karnataka, India. E-mail: drprasannans@gmail.com

### ABSTRACT

Loss of nasal skin as well as loss of both lateral alar cartilages and vestibular lining with exposure of septum presents a grotesque deformity by itself, with further danger of loss of nasal bones and other cartilaginous structures leading to total loss of nose. The Goal of the treatment is to restore the skin cover as well as lining and cartilage support, restoring nose while avoiding the deformity. In an elderly patient with Spiritual restrictions, with diabetes and Hypertension, the treatment was needed to be carried out under local anesthesia as a daycare procedure. Forehead flap was pre-Laminated on forehead before the transfer to have all the three layers of nasal covering. Next the flap was transferred, customizing to recipient site. Finally pedicle was divided retaining the supratrochlear vessels, ensuring the vascularity of the reconstruction and retaining the ability to debulk/manipulate the flap later.

### KEY WORDS

Ala support with cartilage graft; forehead flap nose; nasal lining; pre-laminated flap; supratrochlear vessels

### INTRODUCTION

Loss of nasal skin, as well as the loss of both lateral alar cartilages and vestibular lining with exposure of septum, presents a grotesque deformity by itself, with danger of further loss of nasal bones and other cartilaginous structures, leading to total loss of nose. Such a situation in an elderly patient with comorbid conditions will make reconstruction challenging.

Goal is to restore the skin cover as well as lining and cartilage support in the region of both the alae restoring the nose.

### CASE REPORT

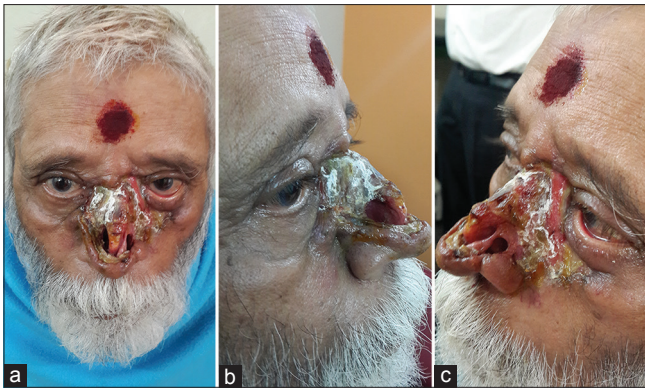About 78-year-old male, diabetic, hypertensive apparently used native application to nose for unknown skin ailment, leading to necrosis of most of the skin over the nose extending onto the adjacent cheeks and loss of both lateral alar cartilages and vestibular lining with exposure of septum [Figure 1a-c]. On presentation, there was pus discharge from the wound with slough covering the upper laterals and nasal bones. Remnant of left alar cartilage, about to slough, was present which was debrided later during flap transfer.

This is an open access article distributed under the terms of the Creative Commons Attribution-NonCommercial-ShareAlike 3.0 License, which allows others to remix, tweak, and build upon the work non-commercially, as long as the author is credited and the new creations are licensed under the identical terms.

**For reprints contact:** reprints@medknow.com

**How to cite this article:** Prasanna NS. Nasal reconstruction with pre-laminated forehead flap. Indian J Plast Surg 2017;50:306-9.

Access this article online	
Quick Response Code:	Website: www.ijps.org
	DOI: 10.4103/ijps.IJPS_165_17

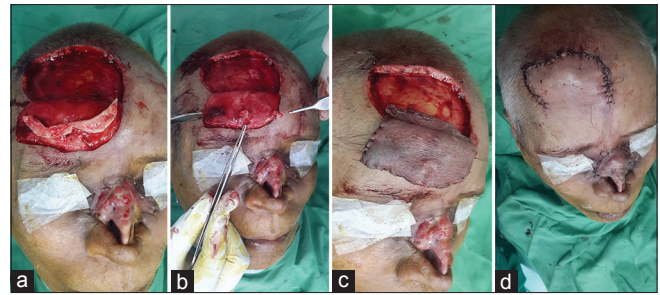


**Figure 1:** (a-c) On presentation, loss of skin and lining and alar cartilages with slough and pus

Forehead flap based on right supratrochlear artery was elevated partially in the subaponeurotic areolar layer, laminated with conchal cartilage graft inserted immediately underneath the galea and lined with a thick split skin graft from the thigh. No effort was made to mimic the alar cartilages with flattened conchal cartilages; just the sharp edges were trimmed. This part of the flap, so laminated, was sutured back to its bed with split skin graft lining extending and sutured to flap donor edge, providing skin cover to flap donor site also. Furthermore, the raw area over upper nose was provided a temporary cover with split skin graft [Figure 2a-d].

After 14 days, flap was transferred to the nose. The split skin graft underneath the forehead flap was trimmed in the edges so as to fit and suture to the edges of nasal lining underneath the upper lateral cartilage; elevated mucoperichondrium of septum in the midline on both sides and to the vestibular lining of the alar rims inferiorly. Excess flap edges were trimmed such that laminated conchal cartilage grafts now occupied the region of lateral alars with their lateral ends resting on pyriform aperture. A strip of skin graft was removed in midline to receive septal cartilage whose mucoperichondrium was already elevated on both sides and sutured to skin graft edge underneath the flap [Figure 3a-c].

After 3 weeks, the flap was divided [Figures 4 and 5]. Pedicle of the flap dissected in subcutaneous plane returned to forehead correcting eyebrows. The Supratrochlear vessels were preserved in continuity with flap and buried in subcutaneous plane. The plan to cover the complete dorsal aesthetic unit of the nose with the flap could not be done due to the sudden rise of blood pressure causing bleeding. Hence, the excess flap was trimmed to fit the defect and sutured. After 5 days, with the wound healed,



**Figure 2:** (a) Forehead flap elevated partially in subaponeurotic layer. (b) Forehead flap elevated, conchal graft tunnelled under galea. (c) Forehead flap elevated partially in subaponeurotic layer, conchal graft tunnelled under galea and covered with split skin graft. (d) Forehead flap elevated partially in subaponeurotic layer, conchal graft tunnelled under galea and covered with split skin graft (both flap and its donor site) and sutured back

sutures were removed. Although both skin and nasal lining was provided with cartilage support in between, skin is bulky. It can be debulked later since the supratrochlear vessels were preserved, if the patient wishes [Figure 6a-c].

All the three surgeries were done under local anaesthesia without sedation as day care case under monitoring of anaesthesiologist.

## DISCUSSION

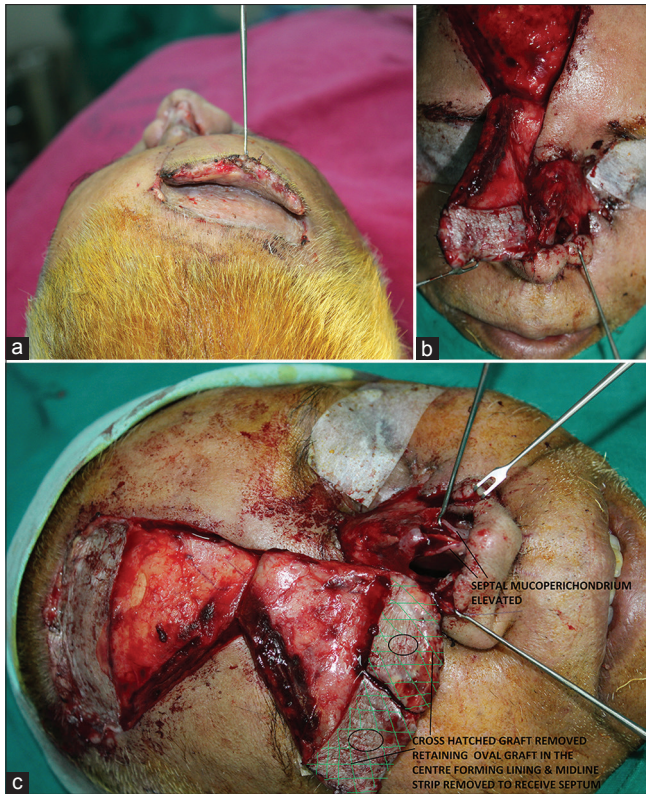
Loss of skin, cartilage and lining of nose can be encountered following infection, trauma, oncologic resections, etc.

Forehead flap<sup>[1]</sup> is a traditional workhorse used for such reconstructions. Sometimes, reconstruction requires the addition of lining with cartilage lamination to replace all elements as a preliminary procedure.<sup>[2,3]</sup>

In the present case, there was a need to replace all the three elements i.e., vestibular lining, supporting cartilage in lower part nose and the skin - both in lower and upper nose.

Alar rims were preserved to ease the reconstruction. No efforts were made to match the conchal cartilage grafts to alar cartilage; only sharp edges were trimmed as the purpose assigned them was to prevent the flap from buckling in during inspiration and to stent the skin graft to counter its contraction.<sup>[3,4]</sup> To achieve this, cartilage was placed just adjacent to mobile aponeurotic layer with thick subcut between the conchal graft and the covering skin.

After 14 days, forehead flap with split skin graft lining, and cartilage graft was matured with enough strength

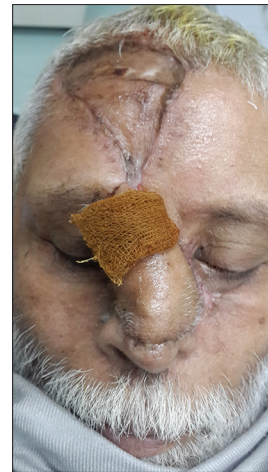

**Figure 3:** (a) Laminated Flap on day 14 ready for transfer to nose. (b) Flap transfer to nasal defect – Slot created in midline by excising strip of split-thickness skin graft to receive septum whose mucoperichondrium is already elevated to be sutured to split thickness skin graft edge medially. The split thickness skin graft trimmed in such a way that it acts like a plug to provide lining and sutured to nasal lining under upper laterals above, below to vestibular lining under remaining alar rims and medially to septal mucoperichondrium. (c) Flap transfer to nasal defect – Flap edge and lining skin graft trimmed such that conchal grafts support the alae and skin graft plug provides lining continuity with remaining surrounding epithelium

to allow its suturing to remaining lining in the nose. Furthermore, this worked as a delay.

Although it is known that split skin graft lining will contract,<sup>[1,3]</sup> still a thick split graft was used without significant effect on alar rims on both sides. Alar rim retraction on the left side was present even before the present incidence according to the patient. Although a composite skin graft from the ear was considered, separate split skin and cartilage graft provided the flexibility in flap design. Furthermore, it would take 4 weeks for chondrocutaneous graft to mature<sup>[5]</sup> delaying the reconstruction.

The supratrochlear vessels were preserved to ensure vascular supply.<sup>[5]</sup> It was only needed to connect upper part of defect on the nose to base of the flap, about 1 cm of extra scar, a small price for insuring the flap. Thus, preservation of the pedicle preserves the choice to debulk/manipulate



**Figure 4:** Well-settled flap after transfer to nose

the flap skin to intermediate stage described by Menick in three-stage nasal reconstruction.<sup>[1,4,6]</sup>

This preserves the ability to manipulate the flap any time after flap division which is advised to be done before flap transfer, on forehead, in two-stage reconstruction<sup>[4,5]</sup> and is not limited by the need to do the debulking before flap division as in three-stage reconstruction.<sup>[1,4]</sup>

Skin-grafted forehead donor site was patchy and was well accepted by the patient since he was a regular user of traditional headgear. Forehead raw area could have been closed partially and remaining could have been left to heal by secondary intention with better outcome.<sup>[4]</sup> However, patient wanted faster resolution, which was acceded to, considering his age and diabetic status.

## CONCLUSION

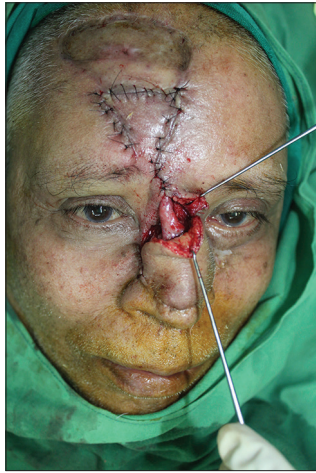Forehead flap is a robust vehicle to carry skin with cartilage and lining grafts to nose.

Pre-lamination of flap on forehead allows time for improving nasal wound and is easy compared to applying the grafts to flap on nose.

Preserving the supratrochlear vessels' continuity retains the choice of flap debulking/manipulation.

## Declaration of patient consent

The authors certify that they have obtained all appropriate patient consent forms. In the form the patient(s) has/have given his/her/their consent for his/her/their images and other clinical information to be reported in the journal.



**Figure 5:** Flap division. Supratrochlear pedicle preserved. Subcut part of the pedicle returned to forehead

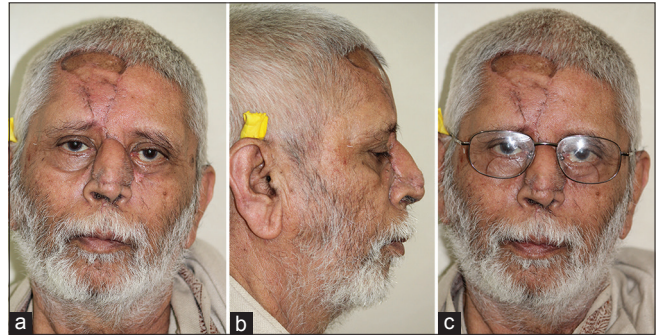The patients understand that their names and initials will not be published and due efforts will be made to conceal their identity, but anonymity cannot be guaranteed.

**Financial support and sponsorship**

Nil.

**Conflicts of interest**

There are no conflicts of interest.



**Figure 6:** (a-c) Postreconstruction – 2 months

**REFERENCES**

1. Menick FJ. A 10-year experience in nasal reconstruction with the three-stage forehead flap. *Plast Reconstr Surg* 2002;109:1839-55.
2. Menick FJ. Lining options in nasal reconstruction. *Plast Reconstr Surg* 1998;5:65-75.
3. Adigun IA, Oladele AO, Olabanji JK. The Naso-labial and lateral forehead flaps as a single stage: A case report and review of literature. *Indian J Plast Surg* 2008;41:171-4.
4. Menick FJ. Nasal reconstruction with a forehead flap. *Clin Plast Surg* 2009;36:443-59.
5. Barton FE Jr., Byrd HS. Acquired deformities of nose. *Plastic Surgery*. 3<sup>rd</sup> ed. Ch. 37. Philadelphia, PA19106: W.B. Saunders Company; 1990. p. 1945-87.
6. Burget GC, Menick FJ. *Aesthetic Reconstruction of the Nose*. St. Louis: Mosby; 1994.