

Case Report

'Sausage finger' with 'Rice bodies'

Guru Prasad Reddy, Divya Narain Upadhyaya, Riddhi Jaiswal¹, Madhu Mati Goel¹

Departments of Plastic and Reconstructive Surgery and ¹Pathology, King George Medical University, Lucknow, Uttar Pradesh, India

Address for correspondence: Dr. Divya Narain Upadhyaya, B-2/128, Sector-F, Jankipuram, Lucknow, Uttar Pradesh India.
E-mail: dnu1@hotmail.com

ABSTRACT

Although both pulmonary and extrapulmonary tuberculosis (TB) are commonly encountered in developing countries, tenosynovitis is an uncommon presentation of musculoskeletal TB. TB mimics a lot of other conditions and causes diagnostic dilemma in day-to-day practice. We present the case of a 30-year-old male who presented with the complaints of swelling of right index finger which was initially suspected to be giant cell tumour of the flexor tendon sheath but on histological examination turned out to be tuberculous tenosynovitis.

KEY WORDS

Flexor; tendon; tenosynovitis; tuberculosis osteoarticular

INTRODUCTION

With the rise of immunodeficiency secondary to human immunodeficiency virus infection, the incidence of tuberculosis (TB) is on the rise. Soft-tissue TB is an uncommon presentation of musculoskeletal TB. Tubercular tenosynovitis most commonly involves the flexor tendons of the dominant hand^[1]. Hand involvement is seen in 10% of patients with musculoskeletal disease, and dominant hand of the male population is affected commonly.

The protean manifestations of TB make it a diagnostic dilemma in clinical practice.

We report a case of flexor tenosynovitis affecting the right index finger, which was treated by synovectomy, and the

rice bodies found intra-operatively were subjected to histopathological examination and revealed caseation and epithelioid giant cells suggesting the possibility of TB.

CASE REPORT

A 30-year-old teacher presented to the outpatient department with the complaints of swelling of the right index finger for the past 2 years. This swelling was slowly progressive in size and was associated with dull pain and difficulty in flexing the affected digit. There was no history of trauma or drug abuse. He had no history of TB or other systemic diseases.

On evaluation, the swelling was found to involve the flexor aspect of the index finger extending onto the

This is an open access article distributed under the terms of the Creative Commons Attribution-NonCommercial-ShareAlike 3.0 License, which allows others to remix, tweak, and build upon the work non-commercially, as long as the author is credited and the new creations are licensed under the identical terms.

For reprints contact: reprints@medknow.com

How to cite this article: Reddy GP, Upadhyaya DN, Jaiswal R, Goel MM. 'Sausage finger' with 'Rice bodies'. Indian J Plast Surg 2018;51:93-7.

Access this article online	
Quick Response Code: 	Website: www.ijps.org
	DOI: 10.4103/ijps.IJPS_202_16

palm [Figures 1 and 2]. Fine-needle aspiration cytology of the swelling revealed giant cells suggesting the possibility of giant cell tumour (GCT) of the tendon sheath. A plain radiograph [Figure 3] of the finger was done, and the phalanges and the second metacarpal were found to be free from any visible lesions. The patient was not affordable for any further workup, and hence, MRI was not included in the pre-operative planning.

A provisional diagnosis of GCT of flexor tendon sheath and a differential diagnosis of compound palmar ganglion and tendinous xanthoma was kept, and the patient was planned for exploration/excision after taking consent for amputation of the digit.

The exploration was done under brachial block and tourniquet control. Brunner's zig-zag incision was used to expose the tumour over the flexor aspect of the digit and palm. A lobulated swelling was found extending from the distal interphalangeal joint to the proximal palm of the concerned digit. The swelling was covered by a tough, thickened, fascia-like structure. This covering was gingerly opened at several places to reveal a synovial sac full of small, shiny rice-bodies, which spilled out from the sac due to the excessive pressure inside the sac [Figure 4].

All the rice bodies were evacuated, and the sac was excised. We were unable to differentiate the synovial sheath of the flexor tendon as separate from this thickened sac-like structure, and hence concluded that this sac-like structure was indeed the synovial sheath of the tendon.

The rice bodies along with the excised thickened synovial sheath were sent for the histopathological examination. Flexor tendon pulley was reconstructed by palmar fascia. The wound was closed in layers over a suction drain. The limb was dressed with mild compressive bandage and splinted with a plaster of paris dorsal slab.

On histopathological examination, sections from the intra-lesional content showed acellular, proteinaceous material with mild inflammatory infiltrate [Figure 5] and sections from the cyst wall showed fibrocollagenous tissue diffusely infiltrated by confluent granulomas [Figures 6 and 7] comprising of epithelioid cells, lymphocytes, plasma cells and Langhan's type giant cells suggesting TB.

After the histopathology report suggested the possibility of TB, the patient was investigated and found to have

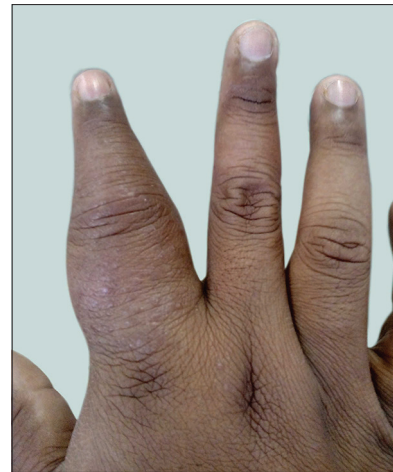

Figure 1: Pre-operative photograph (right hand - dorsal aspect)

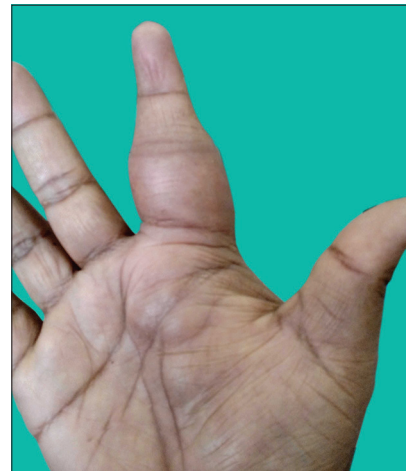

Figure 2: Pre-operative photograph (right hand - volar aspect)

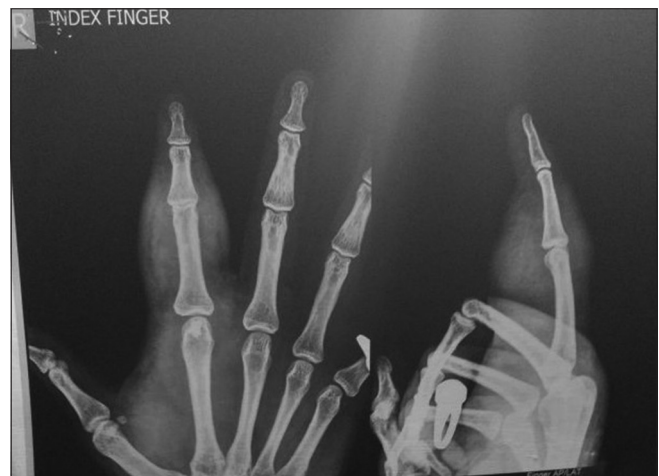

Figure 3: Pre-operative radiograph of the affected finger (right index)

elevated erythrocyte sedimentation rate (ESR) of 32 (Normal range in males below 50 years of age is <15) and a positive Mantoux test (>10 mm). Polymerase chain reaction for *Mycobacterium tuberculosis* (PCR-Tb) was

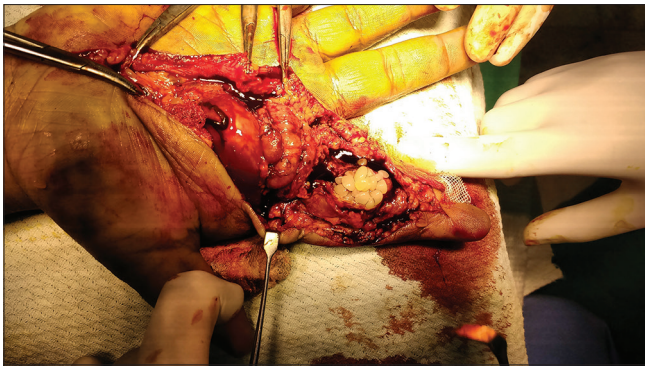


Figure 4: Intra-operative photograph showing rice bodies in the flexor tendon sheath

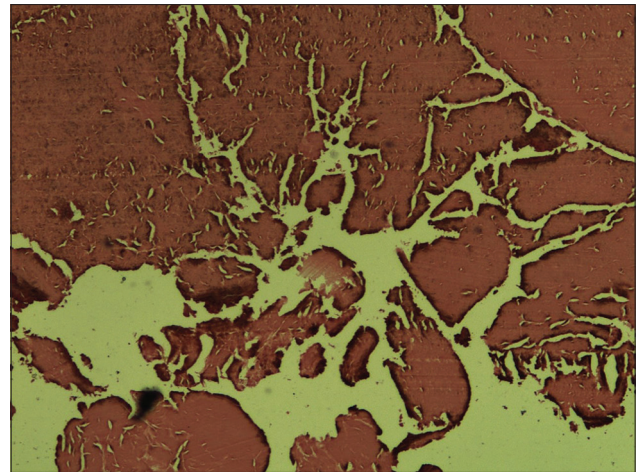


Figure 5: Rice bodies in histological section showing well-circumscribed homogenous amorphous deposits of fibrin

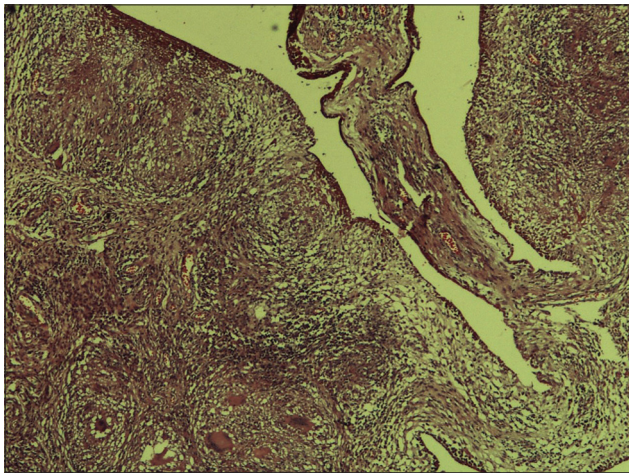


Figure 6: Synovial tissue thrown in papillary folds with formation of multiple epithelioid granulomas in the subepithelial zone with minimal necrosis

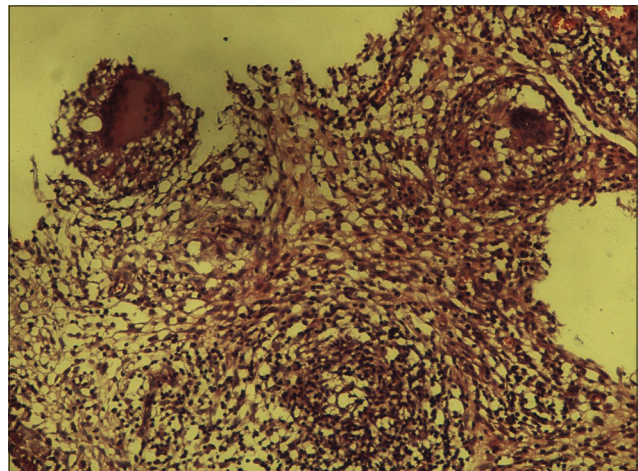


Figure 7: Multiple epithelioid granulomas in another area (H and E, ×10)

negative. Chest radiography showed minimal pleural effusion on the left side, and pulmonary physician opinion was sought for the same. Sputum examination by Ziehl–Neelsen staining was positive for acid-fast bacilli (reported 1+). The patient was started on empirical anti-tuberculosis therapy (ATT) and showed improvement of pleural effusion and hand swelling. After regular follow-up, at the end of 9 months of ATT, the patient had no clinical or radiological evidence of the disease.

DISCUSSION

Soft-tissue TB is among the less frequently encountered form of musculoskeletal TB. It comprises myositis with abscess formation, tenosynovitis and bursitis. TB tenosynovitis usually involves flexor tendons of the dominant side with thickening of tendon/synovial sheath and minimal fluid collection.^[2] Hand involvement is seen in 10% of patients with musculoskeletal TB and the male population is more commonly affected.^[3]

The chief causative organism is *M. tuberculosis*, and the usual primary infection is in the lung. Extrapulmonary TB is due to reactivation of the primary foci and secondarily spread by haematogenous route. In the musculoskeletal system, the bacilli are ingested by macrophages that later coalesce into epithelioid cells. Caseation occurs in the centre of the tubercle.^[4] Atypical *Mycobacterium* infections of the hand (such as *Mycobacterium marinum*) form granulomas without associated caseation. Our patient had a primary focus of TB (pleural effusion with positive Mantoux test and raised ESR) suggesting a possibility of secondary spread to the musculoskeletal system from the lung.

The pathophysiology of ‘rice bodies’ associated with TB synovitis is interesting. Pimm and Waugh^[2] reviewed the history of rice bodies. They were initially thought to be detachments of the synovial membrane or collection of fibrin exudates. In 1927, Rogers^[3] proved they are

composed of tubercular material. The bodies are formed from the centre of each synovial tubercle and are attached to the wall of the tubercular sac. Later, they detach from the wall and appear similar to polished white rice and contain an inner amorphous core of acidophilic material and an outer layer composed of collagen and fibrin.^[4-7] Rice bodies are also seen in other synovial disorders such as rheumatoid arthritis, and fungal infections such as sporotrichosis, seronegative inflammatory arthritis and synovial chondromatosis.^[8]

Symptoms and signs in the hand vary and include pain, swelling, joint effusion, stiffness, digital enlargements, carpal tunnel syndrome and chronic discharging sinuses. The ESR is almost always elevated. Although this is not specific, it is an important test because patients with atypical mycobacterial infections of the hand have a normal ESR. Our patient had an elevated ESR which was one against a diagnosis of atypical mycobacterial infection. An enzyme-linked immunosorbent assay has a sensitivity of 70%.^[9]

A sausage-shaped swelling of the digit is usually seen with isolated tenosynovial involvement of the index, middle, or ring fingers. This presentation is commonly seen as single-digit involvement in adults, although multiple digits can also be involved.^[10-14] Common aetiologies include gout, sarcoidosis, atypical mycobacterial infection, chronic fungal infection and leukaemia.

Biopsy shows caseous necrosis with granulomas, giant cells and lymphocytes. Smears, Ziehl–Neelsen staining and culture are frequently negative as hand TB is a paucibacillary lesion. PCR may be used in equivocal cases where cultures are positive for *Mycobacterium*.

Operative treatment is aimed at getting a biopsy and performing debridement and synovectomy.^[9] However, in our patient, we considered operative treatment first due to the suspicion of GCT.

Patel^[10] advised to vary the duration of chemotherapy based on the tissue involved – 6 months for cutaneous infections, 9 months for tenosynovial involvement and 1 year when bone is infected. In endemic areas, an empirical course of ATT is started in the presence of typical clinical features and a positive smear or culture is not required in all cases.^[8] We started empirical ATT comprising isoniazid, rifampicin, ethambutol and pyrazinamide after getting pulmonologist opinion.

Molecular diagnostic tests such as PCR are not undertaken routinely in our setup as public insurance cover is not a regular practice, and our patient was not affordable for further workup. In an endemic country like ours, even PCR can be false positive and in a patient with signs of active TB with positive Mantoux test and acid-fast bacilli on smear, empirical treatment is initiated to avoid further delay,^[8] and culture of the specimen is not routinely indicated.

CONCLUSION

Our intention to publish this article was to highlight the importance of TB as a differential diagnosis in the presence of atypical lesions of tendon sheath. Although the lack of adequate workup is a drawback in our patient, excellent clinical response is proof enough to support our diagnosis in an endemic country.

Declaration of patient consent

The authors certify that they have obtained all appropriate patient consent forms. In the form the patient(s) has/have given his/her/their consent for his/her/their images and other clinical information to be reported in the journal. The patients understand that their names and initials will not be published and due efforts will be made to conceal their identity, but anonymity cannot be guaranteed.

Financial support and sponsorship

Nil.

Conflicts of interest

There are no conflicts of interest.

REFERENCES

1. Martini M, Benkeddache Y, Medjani Y, Gottesman H. Tuberculosis of the upper limb joints. *Int Orthop* 1986;10:17-23.
2. Pimm LH, Waugh W. Tuberculous tenosynovitis. *J Bone Joint Surg Br* 1957;39-B:91-101.
3. Rogers MH. The formation of rice bodies in tuberculosis. *J Bone Joint Surg* 1927;9A:636-8.
4. Oğüt T, Gökçe A, Kesmezacar H, Durak H, Botanlioğlu H, Erginer R, *et al.* Isolated tuberculous tenosynovitis of the achilles tendon: A report of two cases. *Acta Orthop Traumatol Turc* 2007;41:314-20.
5. Barn R, Turner DE, Rafferty D, Sturrock RD, Woodburn J. Tibialis posterior tenosynovitis and associated pesplano valgus in rheumatoid arthritis: EMG, multi-segment foot kinematics and ultrasound features. *Arthritis Care Res (Hoboken)* 2013;65:495-502.
6. Watts HG, Lifeso RM. Current concepts review: Tuberculosis of bones and joints. *J Bone Joint Surg* 1996;78A:288-98.

7. Visuthikosol V, Kruavit A, Nitiyanant P, Siriwongpairat P. Tuberculous infection of the hand and wrist. *Ann Plast Surg* 1996;37:55-9.
8. Skoll PJ, Hudson DA. Tuberculosis of the upper extremity. *Ann Plast Surg* 1999;43:374-8.
9. Kotwal PP, Khan SA. Tuberculosis of the hand: Clinical presentation and functional outcome in 32 patients. *J Bone Joint Surg Br* 2009;91:1054-7.
10. Patel MR. Chronic infections. In: Green DP, Hotchkiss RN, Pederson WC, editors. *Green's Operative Hand Surgery*. 4th ed. Philadelphia: Churchill Livingstone; 1999. p. 1048-94.
11. Visuthikosol V, Navykarn T, Sae-Aung P. Tuberculous infection of the hand and wrist. *J Med Assoc Thai* 1992;75:45-51.
12. Jaovisidha S, Chen C, Ryu KN, Siriwongpairat P, Peksanan P, Sartoris DJ, *et al.* Tuberculous tenosynovitis and bursitis: Imaging findings in 21 cases. *Radiology* 1996;201:507-13.
13. Chrispal A, Prabhakar T, Booruga HK. A bizarre appearance of a common disease, tuberculous dactylitis, involving multiple digits in an adult. *Trop Doct* 2009;39:51-2.
14. Dumontier C, Maylin V, Sautet A. Rupture a la paume des tendons flechisseurs d origine tuberculeuse. *Rev Chir Orthop* 1996;82:668-71.