

## Original Article

# Modified Cantwell–Ransley repair for isolated continent epispadias in adult: Our experience

Venkat Arjunrao Gite, Hitesh Mahendra Jain, Sachin M. Bote, Jayant Vijay Nikose

Department of Urology, J. J. Hospital, Mumbai, Maharashtra, India

**Address for correspondence:** Dr. Venkat Arjunrao Gite, "Sai Krupa," H-21, Tirupati Supreme Enclave, Jalan Nagar, Aurangabad - 431 005, Maharashtra, India. E-mail: balagigite@yahoo.com

### ABSTRACT

**Purpose:** We evaluate here our experience with modified Cantwell–Ransley technique described by Gearhart for correction of isolated continent epispadias in adults with respect to its long-term functional outcome and complications. **Introduction:** Isolated male epispadias is a rare anomaly with a reported incidence of 1 in 11,700 males. Many surgical techniques with various modifications described to correct epispadias as treatment are debatable and challenging. The majority of the cases are treated at childhood as clinical presentation is striking at birth; hence, presentation in adulthood is extremely rare. **Materials and Methods:** During the past 5 years, modified Cantwell–Ransley technique described by Gearhart was performed in five cases of isolated continent epispadias which includes two cases of proximal penile, two distal penile and one penopubic. All cases were fresh except one had prior failed repair. Corporal rotation was done by delayed absorbable sutures without incision and anastomosis and suprapubic diversions placed in all the cases. **Results:** All cases followed up ranging from 6 months to 5 years and were having horizontal and downwards angled penis. No case had urethrocutaneous fistula or stricture. One case had superficial skin infection which healed by secondary intention did not require any secondary procedure. All cases maintained erection post-operatively too. Catheterisation with soft tube revealed easily negotiable channel in all cases on follow-up. **Conclusion:** Modified Cantwell–Ransley repair described by Gearhart has excellent cosmetic, functional and anatomical results in isolated continent epispadias in the adult.

### KEYWORDS

Cantwell–Ransley repair; epispadias in adult; repair

### INTRODUCTION

Isolated epispadias with continence is very rare entity comprising <10% of all epispadias cases<sup>[1]</sup> and that to in adult is extremely rare since such anomalies are

usually treated surgically in early childhood.<sup>[2]</sup> Epispadias repair remains challenge to reconstructive surgeons. Challenges in adult patients include long-term changes affecting the urethral mucosa and surrounding tissue

This is an open access article distributed under the terms of the Creative Commons Attribution-NonCommercial-ShareAlike 3.0 License, which allows others to remix, tweak, and build upon the work non-commercially, as long as the author is credited and the new creations are licensed under the identical terms.

**For reprints contact:** reprints@medknow.com

**How to cite this article:** Gite VA, Jain HM, Bote SM, Nikose JV. Modified cantwell–ransley repair for isolated continent epispadias in adult: Our experience. Indian J Plast Surg 2017;50:68-73.

Access this article online	
Quick Response Code: 	Website: www.ijps.org
	DOI: 10.4103/ijps.IJPS_243_16

as well as concern about the sexual potential.<sup>[2,3]</sup> Many surgical techniques have been described for the repair of the male epispadias of which modified Cantwell–Ransley has become the procedure of choice.<sup>[4]</sup>

We are presenting results of our experience in performing modified Cantwell–Ransley repair in five continent adult males having various types of isolated epispadias and for its rarity.

## MATERIALS AND METHODS

Isolated epispadias repair was performed in five male adult patients (age ranged from 15 to 25 years) from 2011 to 2016 by a single surgeon. Among them two were in 15–20 years and three were in 20–25 years age group.

All five cases had isolated continent epispadias with one patient had a history of repair in childhood, but exact surgical details were not known. Out of five patients, two were mid-penile, two cases of proximal penile and one were penopubic [Figure 1]. All five cases were continent. In all cases, exposed ventral urethral plate was of adequate width and having mild dorsal chordee and scrotal examination revealed normal tests in all cases. None of the patients had vesicoureteric reflux. All cases had fused symphysis pubis. Kidneys and other intra-abdominal organs were normal on ultrasonography or non-contrast computerised tomogram [Figure 2]. Basic biochemical tests were normal in all the cases. All cases underwent examination under anaesthesia on cystourethroscopy posterior urethra and verumontanum seen and bladder capacity was adequate. Pre-operative testosterone was not used for increasing the penile length. All patients underwent repair under general anaesthesia by modified Cantwell–Ransley technique as described in detail by Gearhart. Traction suture placed into each hemiglans in transverse orientation. Circumcising incision with urethral strip extension on lateral edges of urethral plate and around the hypospadiac meatus. Degloving of penis correction of chordee was checked by intra-operative Gittes test. The urethral plate was dissected away from the corpora except for the distal most 1–1.5 cm so as to get the urethra deeper under the corpora at the glans level [Figure 3]. Urethra is tubularised using Vicryl 5-0 continuous subcuticular fashion over 12 Fr foleys catheter. Medial rotation of corpora over urethra is done using delayed absorbable sutures in an interrupted fashion without incision and anastomosis [Figure 4].

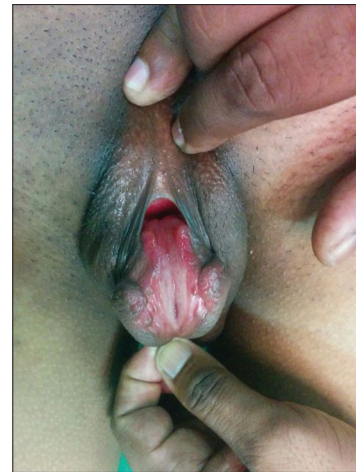

Figure 1: Clinical photograph of penopubic epispadias

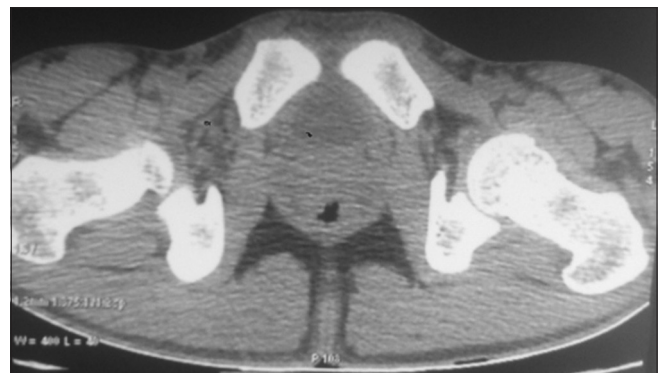


Figure 2: Non-contrast computerised tomogram showing fused symphysis pubis

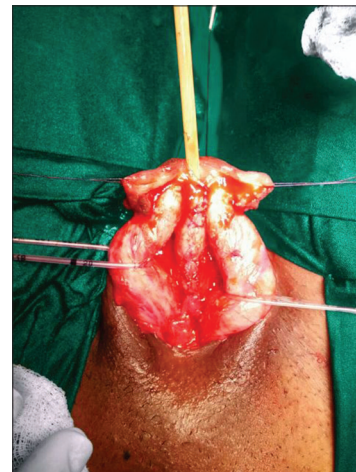

Figure 3: Both corporal bodies dissected away from corpora

Glanuloplasty was done. Skin closed with reversed Byar's flap. The erection was suppressed in post-operative period for 10 days by giving tablet Calmpose 5 mg at bedtime. In all cases, suprapubic cystostomy was done as a proximal diversion. Anticholinergic was started immediately after the surgery till catheter removal to decrease bladder

spasm and to enhance patients comfort. The dressing was opened on the 7<sup>th</sup> post-operative day. The per-urethral catheter was removed on the 14<sup>th</sup> post-operative day, and suprapubic catheter was clamped. All patients voided with a good stream and maintained continence post-operatively [Figure 5]. After 48 h, the suprapubic catheter was removed. All patients were followed up at 1, 3, 6 months and yearly thereafter for outcome. On follow-up, patients were assessed by physical evaluation and gentle placing of the catheter at 3 months and 6 months to check the patency. We assessed flaccid unstretched penile length from penopubic junction to the tip of the penis in standing position pre-operatively and at 3 months post-operatively.

## RESULTS

Follow-up ranges from 6 months to 5 years. All patients had satisfactory cosmetic appearance with conical orthotopic meatus with penile direction downwards on standing position. The post-operative penile length was unchanged except insignificant gain in two cases (approximately 1 cm), and there was complete correction of dorsal chordee.

None of the patients developed meatal stenosis, diverticulum, stricture, fistula or incontinence post-operatively. One patient had superficial skin infection dorsally which was healed by secondary intention without the need for resuturing or grafting. All patients were able to achieve a straight erection. Urethral catheterisation with the smooth urethral tube at 3 months and 6 months was easy in all five patients.

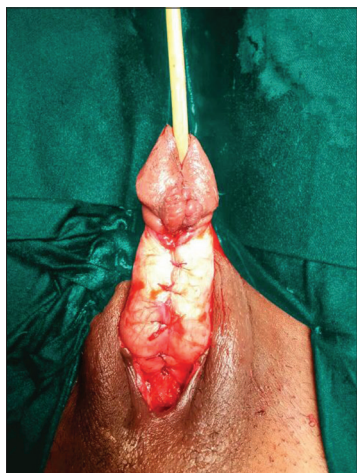


Figure 4: Medial rotation and dorsal approximation of corporal bodies

## DISCUSSION

Epispadias is a rare congenital anomaly usually present at one end of the spectrum of bladder exstrophy-epispadias complex.<sup>[1,2]</sup> It is very unusual for patients with isolated epispadias to present for the first time in adult.<sup>[5]</sup> Braga *et al.* reported mean patient age at epispadias surgery using Cantwell–Ransley repair to be 16.8 months.<sup>[6]</sup> Delayed presentation of all of our patients may be due to poverty and ignorance as all of them from remote villages however one case had prior history of repair. In a series of Hafez and Helmy, all cases presented in post-pubertal life with the prior history of failed repair.<sup>[7]</sup>

Several surgical procedures have been described till date but treatment for this anomaly is far from trivial and repair can be challenging.<sup>[4]</sup> The goal of surgery is to achieve functionally and cosmetically acceptable penis.<sup>[8]</sup> The first description of epispadias repair is by Cantwell in 1895 till then techniques evolved through various modification. Finally, there are two popular techniques described in literature, that is, modified Cantwell–Ransley which involves partial penile disassembly of penis and placement of urethra in more normal position and the second most recent evolution is complete penile disassembly.<sup>[4]</sup>

Despite the versatility of Mitchell technique, it may lead to ischaemic changes to distal glans, loss of glans or corpora and the shortening of urethral plate with resultant hypospadias have been reported.<sup>[9]</sup> The Cantwell–Ransley repair is an excellent, most popular and widely used approach to treat epispadias compared to other standard methods. However, this technique has drawback, the most distal portion of corpora cavernosa

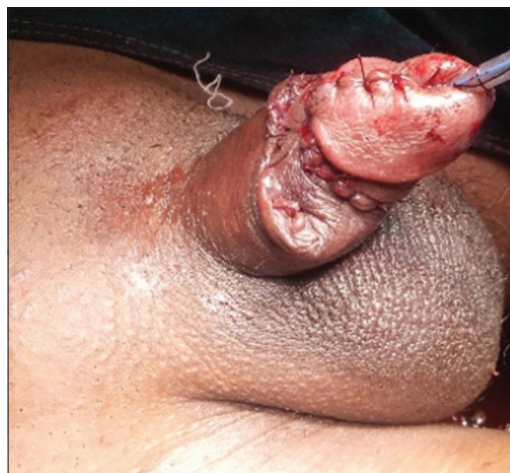

Figure 5: Epispadias repair completed

and urethral plate also not dissected and mobilised leads to inadequate ventralisation of meatus and formation of fistula at coronal sulcus level.<sup>[3,8]</sup>

To avoid drawbacks of both techniques, various modifications have been described. Perovic *et al.* described to leave the distal end of urethral plate attached to both hemiglans to circumvent the problem of shortening to avoid the drawback of Mitchell technique.<sup>[3]</sup>

To avoid drawbacks of Cantwell–Ransley repair, Gearhart described modification as the urethral mucosal plate was dissected away from the corpora except for the distal most 1–1.5 cm so as to get urethra deeper under the corpora at glans level.<sup>[8,10]</sup> Mitchell technique is more ideal for epispadias cases associated with bladder exstrophy and incontinent penopubic epispadias.<sup>[11]</sup>

Considering isolated continent epispadias, surgeons preference and expertise, we used modified Cantwell–Ransley technique described by Gearhart in all five cases including the one who had a history of repair in childhood. By this method, all five cases achieved orthotopic conical meatus, and none had ischaemic changes in glans.

Modified Cantwell–Ransley technique can also be used as salvage procedure as successfully used by Surer *et al.* in his six cases who had prior failed urethroplasty.<sup>[10,12]</sup>

We also feel that in treating the case of isolated epispadias complete penile disassembly with dissection of corpora proximal to penopubic region will not add any real advantage as also reported by Mokhless *et al.*<sup>[11]</sup>

In cases of isolated epispadias, only the urethra gets affected; however, the involvement of bladder neck occurs in few cases. Urinary incontinence may thus result if the defect is proximal enough to affect the sphincter mechanism.<sup>[13]</sup> As all our cases had isolated epispadias continence which was maintained after surgery also. Bansal *et al.* treated two cases of epispadias by modified Cantwell–Ransley technique and continence was maintained in both of his cases post-operatively.<sup>[1]</sup> Up to 70% males with penopubic epispadias had widely separated bones of pelvis affecting bladder neck and external sphincter leading to incontinence or stress urinary incontinence.<sup>[14]</sup> However, in our series, only one patient had penopubic epispadias who had fused symphysis pubis and not having incontinence.

Technique to improve dorsal chordee before urethroplasty is ventral shortening of corpora or medial rotation of ventral corpora described by Koff and Eakins.<sup>[15]</sup> Corporal rotation can be done either by incision and anastomosis where the dissection of neurovascular bundle is necessary or without incision and anastomosis with an approximation of corpora by delayed absorbable sutures.<sup>[10]</sup> Whether simple rotation of corpora is adequate or corporal incision and anastomosis are really required a judgement call at the time of surgery.<sup>[12]</sup> For cases with severe chordee and older patients, incision and anastomosis technique of rotation are required.<sup>[10]</sup>

In our series, all cases had mild dorsal chordee which was corrected by medial rotation without incision and anastomosis and achieved a direction of penis either downwards or horizontal in standing position post-operatively. Proximal diversion is used for several weeks, which will lower fistula formation.<sup>[12]</sup> We also place suprapubic cystostomy as proximal diversion as an additional safety and to avoid fistula formation in all cases.

None of the current epispadias repair offers any significant gain in penile length by removing entire urethral plate from glans or even using free graft.<sup>[10]</sup> Gain in penile length is achieved by straightening the penis and not by adding the length to corporal bodies.<sup>[16]</sup> The claim that penile length may be affected using modified rather than the complete penile disassembly technique is incorrect.<sup>[9]</sup> El-Sherbiny and Hafez found no significant difference in mean penile length between the two techniques.<sup>[17]</sup>

In our series, also, unstretched length of the penis before and after surgery is either unchanged or within significant gain in length post-operatively.

Complications following epispadias repair include the development of urethrocutaneous fistula, persistent chordee, difficulty in urethral catheterisation and erectile dysfunction.<sup>[8]</sup> Reported fistula rate for Cantwell–Ransley repair ranges from 5% to 20%.<sup>[10]</sup> Nerli *et al.* treated 43 cases of epispadias by modified Cantwell–Ransley technique and had 16.27% fistula rate.<sup>[8]</sup> Fistula rate of 4% and urethral stricture rate of 5.3% reported by Gearhart and Mathews.<sup>[14]</sup> In our series, no patient developed fistula or stricture (although our series comprises of five cases only) similar to findings of Pippi Salle *et al.*<sup>[18]</sup> In the report of two cases of epispadias repair by modified

Cantwell–Ransley by Lodh *et al.*, there is no fistula or need for any dilatation post-operatively.<sup>[4]</sup>

Only one patient had superficial infection of dorsal penile skin which healed by secondary intention and did not require a secondary procedure in our series. In series of Nerli *et al.* of 43 cases treated by similar technique found dorsal skin infection or incision separation in three children and none required a secondary procedure in his series.<sup>[8]</sup>

Pippi Salle *et al.* used ventral rotational skin flap in nine patients for dorsal skin closure found improved cosmesis and decreased recurrence of chordee secondary to midline dorsal scarring.<sup>[18]</sup>

No impotence, due to Cantwell–Ransley procedure, has been reported in literature as dissection is not carried out too far under the pubic bone. There is no risk of injury to cavernosal artery or erectile nerves.<sup>[19]</sup> Atim and Mustapha reported a case of penopubic epispadias treated by modified Cantwell–Ransley technique, and in his single case, erection was maintained post-operatively.<sup>[2]</sup> Reddy *et al.* in their assessment of sexual health outcome in adults with complete male epispadias post-reconstruction noted 80% of their patients had overall satisfactory sexual intercourse.<sup>[20]</sup> In our series of five cases, all were able to achieve and maintain erection up to 5 years follow-up. Out of five cases, only one was married who had satisfactory sexual life post-operative.

Penile cosmesis following repair is subjective measurement and differs for surgeon and patients.<sup>[1]</sup> Lottmann *et al.* in series of forty patients reported 90% successful anatomic and functional results following repair at a mean follow-up of 3 years.<sup>[19]</sup> In our series at the end of maximum 5 years follow-up and a minimum follow-up of 6 months, all five cases had satisfactory cosmesis with successful anatomic and functional results [Figures 6-8].

All our patients were adults having isolated epispadias with adequate penile length. No one has pubic diastasis, so the approximation of corpora is easier. All cases are continent, so there is no peri-catheter leak which increases the chances of infection and fistula formation. Hence, meticulous dissection, perfect hemostasis, proximal urinary diversion and proper approximation of corpora to cover urethral suture site is key for success.

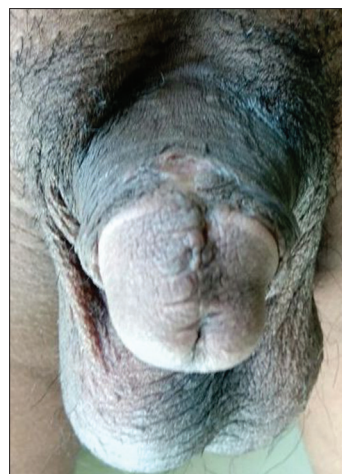


Figure 6: Clinical photograph showing excellent cosmetic results taken at 4 years follow-up




Figure 7: Clinical photograph showing excellent functional results taken at 4 years follow-up

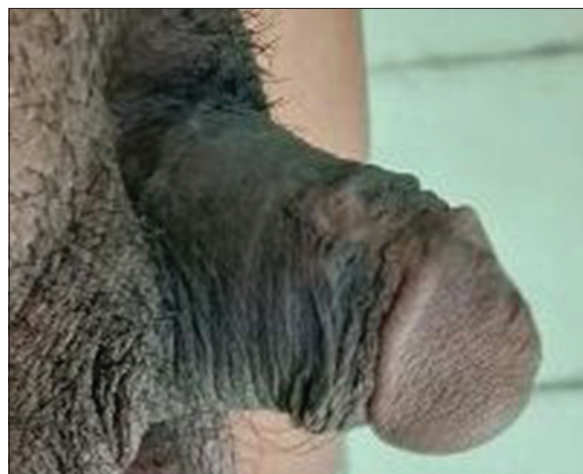

Figure 8: Clinical photograph showing good stream post-operatively

## CONCLUSION

Isolated continent epispadias in adults is extremely rare but not uncommon. Modified Cantwell–Ransley repair is well suited for primary as well as failed cases in adults with isolated epispadias and provide excellent

anatomical, functional results with good cosmesis and improves the quality of life of patients.

### Financial support and sponsorship

Nil.

### Conflicts of interest

There are no conflicts of interest.

### REFERENCES

1. Bansal D, Rathore RS, Eillai B, Krishnamoorthy H. Modified Cantwell-Ransley repair in peno-pubic epispadias with continent bladder. *Astrocyte* 2015;2:49-51.
2. Atim T, Mustapha A. Penopubic epispadias repair in adulthood: Surgical and functional outcome with modified Cantwell-Ransley procedure. *Sub Saharan Afr J Med* 2015;2:179-83.
3. Perovic SV, Vukadinovic V, Djordjevic ML, Djakovic NG. Penile disassembly technique for epispadias repair: Variants of technique. *J Urol* 1999;162(3 Pt 2):1181-4.
4. Lodh B, Khumukcham S, Amer B, Kaku AS. Modified Cantwell-Ransley repair of male penopubic epispadias: Report of two cases and review of the literature. *J Case Rep* 2013;3:344-8.
5. Wittmeyer V, Aubry E, Liard-Zmuda A, Grise P, Ravasse P, Ricard J, *et al.* Quality of life in adults with bladder exstrophy-epispadias complex. *J Urol* 2010;184:2389-94.
6. Braga LH, Lorenzo AJ, Bägli DJ, Khoury AE, Pippi Salle JL. Outcome analysis of isolated male epispadias: Single center experience with 33 cases. *J Urol* 2008;179:1107-12.
7. Hafez AT, Helmy T. Complete penile disassembly for epispadias repair in postpubertal patients. *Urology* 2011;78:1407-10.
8. Nerli RB, Pujar VC, Patil RA, Jali SM. Modified Cantwell-Ransley epispadias repair in children our experience. *J Sci Soc* 2015;42:7-11.
9. Anwar AZ, Mohamed MA, Hussein A, Shaaban AM. Response to editorial comment to modified penile disassembly technique for boys with epispadias and those undergoing complete primary repair of exstrophy: Long-term outcomes. *Int J Urol* 2014;21:941.
10. Surer I, Baker LA, Jeffs RD, Gearhart JP. The modified Cantwell-Ransley repair for exstrophy and epispadias: 10-year experience. *J Urol* 2000;164(3 Pt 2):1040-2.
11. Mokhless I, Youssif M, Ismail HR, Higazy H. Partial penile disassembly for isolated epispadias repair. *Urology* 2008;71:235-8.
12. Gearhart JP, Sciortino C, Ben-Chaim J, Peppas DS, Jeffs RD. The Cantwell-Ransley epispadias repair in exstrophy and epispadias: Lessons learned. *Urology* 1995;46:92-5.
13. Grady RW, Mitchell ME. Management of epispadias. *Urol Clin North Am* 2002;29:349-60, vi.
14. Gearhart JP, Mathews RI. Exstrophy-epispadias complex. In: Wein AJ, editor. *Campbell-Walsh Urology*. 10<sup>th</sup> ed. Philadelphia: Elsevier Saunders; 2010. p. 3325-78.
15. Koff SA, Eakins M. The treatment of penile chordee using corporeal rotation. *J Urol* 1984;131:931-2.
16. Silver RI, Yang A, Ben-Chaim J, Jeffs RD, Gearhart JP. Penile length in adulthood after exstrophy reconstruction. *J Urol* 1997;157:999-1003.
17. El-Sherbiny MT, Hafez AT. Complete repair of bladder exstrophy in boys: Can hypospadias be avoided? *Eur Urol* 2005;47:691-4.
18. Pippi Salle JL, Jednak R, Capolicchio JP, França IM, Labbie A, Gosalbez R. A ventral rotational skin flap to improve cosmesis and avoid chordee recurrence in epispadias repair. *BJU Int* 2002;90:918-23.
19. Lottmann HB, Yaqouti M, Melin Y. Male epispadias repair: Surgical and functional results with the Cantwell-Ransley procedure in 40 patients. *J Urol* 1999;162(3 Pt 2):1176-80.
20. Reddy SS, Inouye BM, Anele UA, Abdelwahab M, Le B, Gearhart JP, *et al.* Sexual health outcomes in adults with complete male epispadias. *J Urol* 2015;194:1091-5.