

defect over right thigh with exposed femoral artery pseudoaneurysm in a 23-year-old male who suffered electric burn with 1100 V alternating current and was referred to our centre after 40 days. Due to high voltage electric current injury, local tissue was deficient as donor, with debried and fibrosed gracilis, tensor fascia lata and sartorius muscles and surrounding raw area. Options to cover the exposed femoral artery [Figure 1] which had a history of blowout were either a complicated microvascular free flap or morbid inferiorly based rectus abdominis muscle/myocutaneous flap.

We used this flap as a simple alternative in given scenario against complex tissue transfer. A femoral angiography was done to confirm the diagnosis of pseudoaneurysm [Figure 2], which was repaired with venous patch and subsequently covered it with a preputial flap. The arterial supply reaching the outer preputial layer fold by 180° to supply the inner layer and it ultimately terminates at the corona. Blood supply to the prepuce reaches via 4 to 5 minute vessels, distributed both ventrally and dorsally.^[1,2]

Unfurling of the prepuce can be easily done by giving an incision on the inner layer, near the corona circumferentially, and carefully dissecting the 2 layers of the prepuce without damaging the blood supply to either.

A dorsal slit was given up to the base of glans. Incision was then turned perpendicular and was taken all around, leaving 1 cm skin attached on each side of the frenulum [Figure 3]. This unfurled prepuce was then used to cover the raw area above the freshly repaired artery. Base of flap was attached in a manner that almost

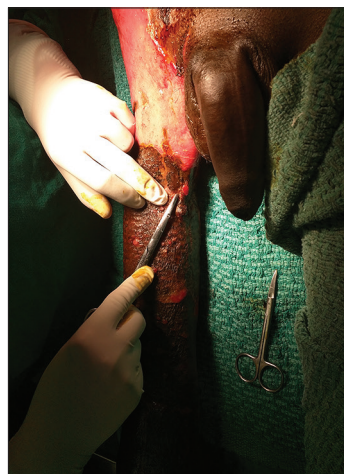


Figure 1: Exposed femoral artery pseudoaneurysm with grafted surrounding skin and raw areas. Deficient local tissues for cover

Novel use of preputial flap

Sir,
The novel use of prepuce as a regional flap to cover a

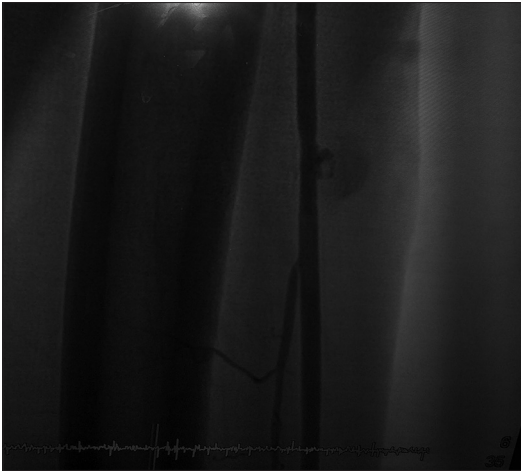


Figure 2: Arteriography showing the pseudoaneurysm pre-operatively

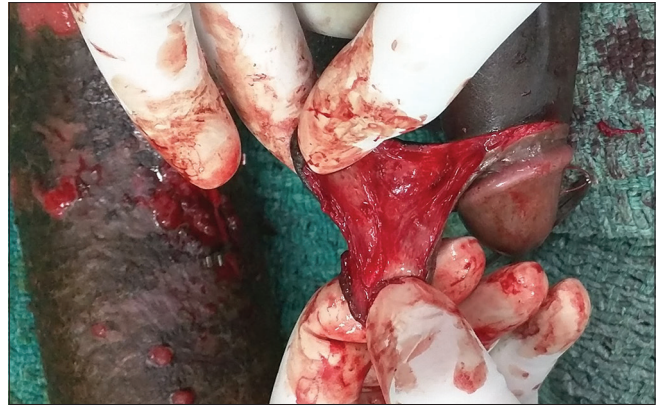

Figure 3: Preputial flap raised

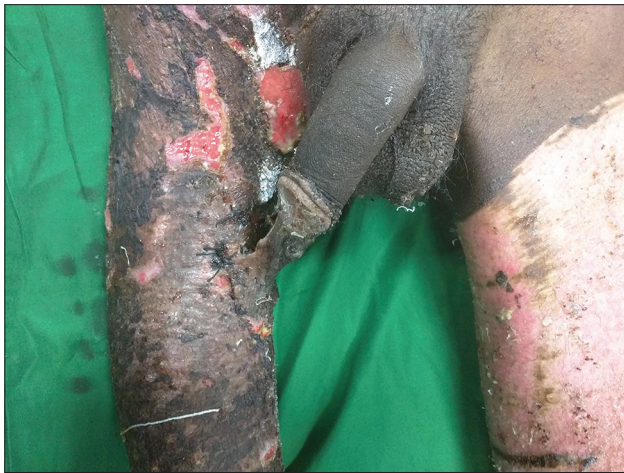

Figure 4: Attached preputial flap covering the repaired femoral artery

100% cover was achieved [Figure 4]. Post-operatively, the patient was kept sedated to avoid erection. Flap was detached on 21st post-operative day [Figure 5].

Special care is taken in preputial flap to prevent acute kinking and detachment during penile erection as pedicle of flap is attached with the corona. Dimensions possible with this flap are up to 8 cm × 10 cm, but it will vary with the amount of prepuce available with the individual.^[3] It can be used as a distant flap to cover fingers and wrist or as an adjunct to a groin flap.^[3,4] In the areas in the radius of penile length, it can be used as a regional flap as shown in this article.

Financial support and sponsorship

Nil.

Conflicts of interest

There are no conflicts of interest.

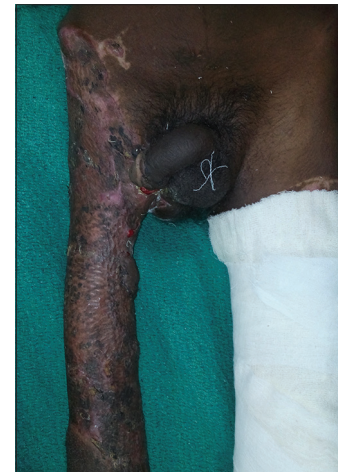

Figure 5: Post-operative after detachment of flap and inset

**Ankit Gupta, Shyam Gupta, Akhil Kumar,
Manoj Kumar Jha, Sameek Bhattacharaya,
Vinay Kumar Tiwari**

Department of Burns, Plastic and Maxillofacial Surgery,
PGIMER and RML Hospital,
New Delhi, India

Address for correspondence:

Dr. Ankit Gupta,
Department of Burns, Plastic and Maxillofacial Surgery, PGIMER
and RML Hospital,
New Delhi, India.
E-mail: drankit1612@yahoo.com

REFERENCES

1. Hinman F Jr. The blood supply to preputial island flaps. *J Urol* 1991;145:1232-5.
2. Juskiwenski S, Vaysse PH, Moscovici J, Hammoudi S, Bouissou E. A study of the arterial blood supply to the penis. *Anat Clin* 1982; 4: 101 – 7.
3. Tiwari VK, Sarabahi S, Chauhan S. Preputial flap as an adjunct to groin flap for the coverage of electrical burns in the hand. *Burns* 2014;40:e4-7.
4. Sharma D, Tiwari VK. Preputial flap to hand and forearm. *Br J Plast Surg* 2000;53:635-6.

This is an open access article distributed under the terms of the Creative Commons Attribution-NonCommercial-ShareAlike 3.0 License, which allows others to remix, tweak, and build upon the work non-commercially, as long as the author is credited and the new creations are licensed under the identical terms.

Access this article online	
Quick Response Code: 	Website: www.ijps.org
	DOI: 10.4103/ijps.IJPS_2_16

How to cite this article: Gupta A, Gupta S, Kumar A, Jha MK, Bhattacharaya S, Tiwari VK. Novel use of preputial flap. Indian J Plast Surg 2017;50:112-4.