

# Comparing the diagnostic efficacy of full field digital mammography with digital breast tomosynthesis using BIRADS score in a tertiary cancer care hospital

Divya Singla, Arvind K. Chaturvedi<sup>1</sup>, Abhinav Aggarwal<sup>2</sup>, S. A. Rao<sup>1</sup>, Dibyamohan Hazarika<sup>1</sup>, Vivek Mahawar<sup>1</sup>

Department of Radiology, Dr. B.R. Ambedkar Hospital, Rohini, <sup>1</sup>Department of Radiology, Rajiv Gandhi Cancer Institute and Research Centre, Rohini, New Delhi, <sup>2</sup>Department of Radiology, City X-Ray and Scan Clinic, Dwarka, India

**Correspondence:** Dr. Abhinav Aggarwal, City X-ray and Scan Clinic, Sector 12A, Opposite Bal Bharati Public School, Dwarka, New Delhi - 110 075, India. E-mail: abhinavagg@gmail.com

## Abstract

**Introduction:** Breast cancer is one of the leading cancers in females worldwide, and its incidence has been rising at an exponential pace in the last 10 years even in India. Mammography has been the mainstay for detection of breast cancer over decades and has gradually advanced from screen film to full-field digital mammography. Recently, tomosynthesis has evolved as an advanced imaging investigation for early diagnosis of breast lesions in both diagnostic and screening settings. **Aim of Study:** To compare and evaluate the impact of digital breast tomosynthesis (DBT) compared to full-field digital mammography (FFDM) in the interpretation of BIRADS score in both diagnostic and screening settings. **Settings and Design:** A 1-year prospective longitudinal study was conducted in the Department of Radio-diagnosis in our institute using Hologic Selenia Dimensions for mammography as well as tomosynthesis. **Materials and Methods:** One hundred women known or suspected (opportunistic screening) for breast cancer were evaluated either with FFDM alone or both FFDM and DBT. Sensitivity, specificity, positive predictive value, negative predictive value, and *P* value were used to assess the various diagnostic criteria in our study. **Results:** Addition of DBT to FFDM results in a statistically significant increase in the sensitivity, specificity, and positive predictive value, and a statistically significant decrease in the false positive rates. Similar results were noted in both diagnostic and screening cases. It was observed that, in most cases, i.e. a total of 47, DBT did not change the BIRADS scoring; however, its addition increased the diagnostic confidence. BIRADS was upgraded and downgraded in 14 and 31 cases, respectively, with the addition of DBT to FFDM. New lesions were seen with addition of DBT to FFDM in 8 cases. **Conclusion:** Addition of DBT to FFDM results in increase in sensitivity, specificity, positive predictive value, and a statistically significant decrease in false positive rates in both diagnostic and screening cases. As addition of tomosynthesis results in a significant decrease in recall rate, it should be added, at least, in all screening mammography programs.

**Key words:** Breast cancer; mammography; opportunistic screening; tomosynthesis

### Access this article online

#### Quick Response Code:



**Website:**  
www.ijri.org

**DOI:**  
10.4103/ijri.IJRI\_107\_17

This is an open access journal, and articles are distributed under the terms of the Creative Commons Attribution-NonCommercial-ShareAlike 4.0 License, which allows others to remix, tweak, and build upon the work non-commercially, as long as appropriate credit is given and the new creations are licensed under the identical terms.

**For reprints contact:** reprints@medknow.com

**Cite this article as:** Singla D, Chaturvedi AK, Aggarwal A, Rao SA, Hazarika D, Mahawar V. Comparing the diagnostic efficacy of full field digital mammography with digital breast tomosynthesis using BIRADS score in a tertiary cancer care hospital. Indian J Radiol Imaging 2018;28:115-22.

## Introduction

Breast cancer is one of the leading cancers in females worldwide.<sup>[1]</sup> According to GLOBACON 2012, over the last 10 years, breast cancer has been rising steadily; and for the first time now, breast cancer is the most common cancer among women in India in metropolitan cities, way ahead of cervical cancer. Both the incidence and deaths caused by breast cancer are more than cervical cancer in metropolitan cities.

In India, the average age of developing breast cancer has undergone a significant shift over the last few decades. At present, 4% are in the 20–30-years age group, 16% are in 30–40, and 28% are in 40–50 years age group. Hence, almost 48% patients are below 50 years of age. An increasing number of patients are in the 25–40 years of age, which is a very disturbing trend.<sup>[1,2]</sup>

Mammography is one of the initial investigations for imaging the breast and comprises two views (medial lateral oblique and craniocaudal). We look for any mass, architectural distortion, or calcification, and then accordingly give BIRADS score (Breast imaging reporting and data system). Initially, screen film mammography was done, but at present full-field digital mammography (FFDM) is gradually replacing film screen mammography.<sup>[2]</sup> Screening mammography is the most important screening tool for breast cancer. It has been shown to reduce the rate of death from breast cancer among age group of 40 years of age or older.<sup>[3]</sup> Reduction in mortality caused by breast cancer has been seen in various studies where screening mammography was used.<sup>[3,4]</sup>

Advances in FFDM led to the development of digital breast tomosynthesis, which is basically a three-dimensional breast examination.<sup>[5,6]</sup> Tomosynthesis is similar to a low-dose computed tomography (CT) as well as to conventional mammography with regard to breast positioning and compression; however, unlike conventional mammography, the X-ray tube is not stationary and moves through a limited angle, e.g., -7.5 degrees to +7.5 degrees. The resulting data is reconstructed into thin sections through the breast in the orientation of acquisition, e.g. craniocaudal, mediolateral oblique.

Several investigations have shown that DBT has potential in both screening and diagnostic settings.<sup>[7-9]</sup>

### Aims and objectives

To compare and evaluate the impact of DBT compared to FFDM in the interpretation of BIRADS score.

## Materials and Methods

A 1-year prospective longitudinal study was conducted in the Department of Radio-diagnosis in our institute using Hologic Selenia Dimensions for mammography as well as tomosynthesis. One hundred women who reported to our hospital for opportunistic breast cancer screening or were suspected for breast cancer were evaluated either with FFDM alone or both FFDM and DBT. Pregnant and lactating females and those with open wounds were excluded from the study.

The study population was divided into two groups – screening and diagnostic age groups. Screening cases included women above the age of 40 years presenting for breast cancer screening along with women who had already undergone treatment for breast cancer and were on yearly follow-up. Diagnostic cases included women presenting with breast complaints such as nipple discharge, palpable lump, or pain in breast.

Cases were also evaluated on the basis of breast density (according to ACR guidelines edition 2013) and age.

Both mediolateral oblique (MLO) and craniocaudal (CC) views were obtained for FFDM, while for tomosynthesis only MLO view was used. The images were interpreted at Barco 5.0 megapixel monitors. BIRADS score was assigned to each breast.

All lesions with a BIRADS score of IV or more under any arm, i.e. either FFDM alone or FFDM plus DBT were considered as test positive on that particular imaging, i.e. FFDM or FFDM plus DBT, respectively. Similarly, all lesions with BIRADS score of III or less under any arm, i.e., either FFDM alone or FFDM plus DBT, were considered as test negative on that particular imaging, i.e., FFDM or FFDM plus DBT, respectively.

True positives and true negatives were decided on the basis of further diagnostic work-up, which included histopathological examination, other imaging studies such as ultrasonography, magnetic resonance mammography, follow-up, or any one of the above.

Fine needle aspiration cytology (FNAC) and/or biopsy were advised only in patients with BIRADS IV or more on FFDM plus DBT as a part of hospital practice. Patients with positive score on FFDM but negative score on FFDM plus DBT were assessed by further imaging studies such as ultrasonography and magnetic resonance mammography. Patients with negative scoring on both FFDM and FFDM plus DBT were followed for 6 months for any evidence of malignancy by regular medical and self-examination. Imaging was done wherever required.

Prior approval was taken from the Institutional Review Board. Informed consent was taken from all the patients.

## Results

Out of the total 100 cases, 59 were diagnostic and 41 were screening cases [Table 1]. Maximum cases (49) were in the age group of 41–50 years, among which 21 came for diagnostic imaging and 28 came for screening. Mean age was 49.85 years. Only 4 cases belonged to age group of >70 years [Table 2].

On FFDM, 49% patients were given BIRADS score IV and 24% patients were given BIRADS score V. Hence, 73% patients were labeled as test positive (BIRADS score IV or more) on FFDM [Table 3].

Among diagnostic setup, 28 and 24 cases (47.4% and 40.7%) were given score of BIRADS IV and V, respectively, i.e. 87.4% cases were test positive on FFDM in the diagnostic setup. Among screening setup, 21 (51.2%) cases were given score of BIRADS IV. No case was given BIRADS core of V in screening on FFDM. So, 51.2% cases were test positive on FFDM in the screening setup.

On FFDM plus DBT, 30% patients were given BIRADS score IV, 31% patients were given BIRADS score V. Hence, 61% patients were labeled as test positive (BIRADS score IV or more) [Table 4].

In the diagnostic setup 20 and 29 cases (33.8% and 49.2%) were given score of BIRADS IV and V, respectively, i.e. 83% cases were test positive on FFDM plus DBT in diagnostic setup. Among screening setup 10 and 2 cases (24.4% and 4.9%) were given a score of BIRADS IV and V, respectively. So, 29.3% cases were test positive on FFDM plus DBT in the screening setup.

Among 59 patients who underwent diagnostic mammography, 49 underwent FNAC and/or biopsy; and out of these 49 cases, 43 were malignant and 6 were found to be benign on histopathological examination. Among 41 screening cases, 12 patients were advised for histopathological correlation, out of which 6 were malignant and 6 were benign.

Out of the total 100 cases, 49 proved to be malignant (all proven on HPE), 37 were benign, and 14 were normal [Table 5].

It was observed that, in most of the cases (47), DBT did not change the BIRADS scoring but its addition increased the diagnostic confidence. BIRADS was upgraded [Figures 1 and 2] and downgraded [Figures 3 and 4] in 14 and 31 cases, respectively, with the addition of DBT to FFDM. New lesions were seen with addition of DBT to FFDM in 8 cases [Figures 1, 5 and 6]. In diagnostic setup, 66.1% cases had no change in BIRADS scoring with addition

**Table 1: Proportion of screening and diagnostic cases**

Screening/diagnostic	Frequency	Percentage
Diagnostic	59	59
Screening	41	41
Total	100	100

**Table 2: Age-wise distribution of the study population**

Age groups	Frequency	Percentage
≤40 years	14	14
41-50 years	49	49
51-60 years	23	23
61-70 years	10	10
>70 years	4	4
Total	100	100
Mean±SD		49.85±9.74
Min-Max		29-78

**Table 3: Percentage of BIRADS scoring of breast lesions on FFDM in diagnostic and screening groups**

BIRADS on FFDM	Diagnostic		Screening	
	Frequency	Percentage	Frequency	Percentage
0	3	5.1	2	4.9
I	2	3.4	5	12.2
II	0	0.0	2	4.9
III	2	3.4	11	26.8
IV	28	47.4	21	51.2
V	24	40.7	0	0.0
Total	59	100	41	100

**Table 4: Percentage of BIRADS scoring of breast lesions on FFDM plus DBT in diagnostic and screening groups**

BIRADS on FFDM + DBT	Diagnostic		Screening	
	Frequency	Percentage	Frequency	Percentage
I	0	0.0	13	31.7
II	5	8.5	10	24.4
III	5	8.5	6	14.6
IV	20	33.8	10	24.4
V	29	49.2	2	4.9
Total	59	100	41	100

**Table 5: Results of HPE in both diagnostic and screening setups**

HPE (if available)	Diagnostic (n=59)		Screening (n=41)	
	Frequency	Percentage	Frequency	Percentage
Benign	6	10.2	6	14.6
Malignant	43	72.9	6	14.6

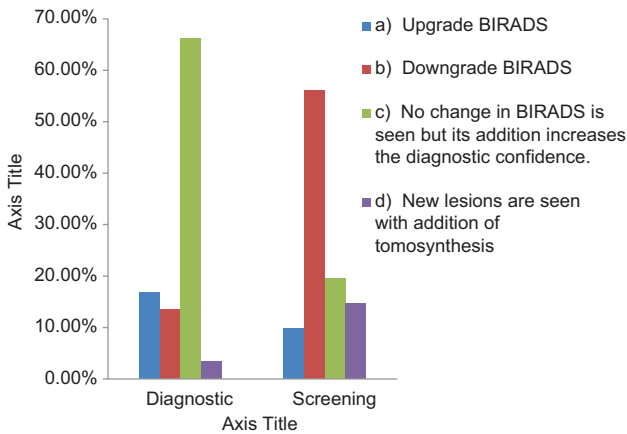
of tomosynthesis but increased diagnostic confidence was noted. In screening setup, tomosynthesis downgraded the BIRADS in 56.1% cases [Table 6].

According to breast density, patients were divided into four groups: almost entirely fatty breast (type a; n = 4; 4%),

scattered areas of fibroglandular density (type b;  $n = 32$ ; 32%), heterogeneously dense breast parenchyma (type c;  $n = 56$ ; 56%), and extremely dense breast parenchyma (type d;  $n = 8$ ; 8%) [Table 7].

Improvement in sensitivity, specificity, false positive rates, and positive predictive values was seen with addition of DBT to FFDM in patients with breast densities b, c and d [Tables 8-11].

**Table 6: Effect of addition of DBT to FFDM on BIRADS in diagnostic and screening setup**



**Table 7: Breast density wise distribution of study population**

Breast density	Frequency	Percentage
Almost entirely fatty	4	4
Scattered areas of fibroglandular density	32	32
Heterogeneously dense	56	56
Extremely dense	8	8
Total	100	100

**Table 8: Comparison of sensitivity of FFDM versus FFDM plus DBT in different breast densities**

	Sensitivity		P
	FFDM	FFDM + DBT	
a	100.0%	100.0%	-
b	100.0%	100.0%	-
c	76.2%	100.0%	0.017
d	50.0%	100.0%	0.046

**Table 9: Comparison of specificity of FFDM versus FFDM plus DBT in different breast densities**

	Specificity		P
	FFDM	FFDM + DBT	
a	0%	0%	-
b	35.7%	85.7%	0.006
c	37.1%	71.4%	0.004
d	50.0%	100.0%	0.248

Patients were divided into five groups according to age distribution: <40, 41–50, 51–60, 61–70, and >70 years. With addition of DBT to FFDM, statistically significant increase in sensitivity was seen in <40 years and 41–50 years age groups, with  $P$  values of 0.047 and 0.035, respectively.

Statistically significant increase in specificity was seen with the addition of DBT to FFDM in 41-50 years ( $P = 0.003$ ) and 61-70 years age group ( $P = 0.014$ ). Similarly, significant decrease in false positive rate was seen in 41–50 and 61–70 years age groups with  $P$  values of 0.01 and 0.06, respectively. Statistically significant increase in positive predictive value was seen with the addition of DBT to FFDM in 41–50 years group ( $P = 0.03$ ) [Tables 12-15].

**Table 10: Comparison of false positive rates of FFDM versus FFDM plus DBT in different breast densities**

	False positive rate		P
	FFDM	FFDM + DBT	
a	0.0%	0.0%	-
b	28.1%	6.3%	0.02
c	39.3%	17.9%	0.01
d	12.5%	0.0%	0.3

**Table 11: Comparison of positive predictive value of FFDM versus FFDM plus DBT in different breast densities**

	Positive predictive value		P
	FFDM	FFDM + DBT	
a	100.0%	100.0%	-
b	66.7%	90.0%	0.06
c	42.1%	67.7%	0.03
d	75.0%	100.0%	0.19

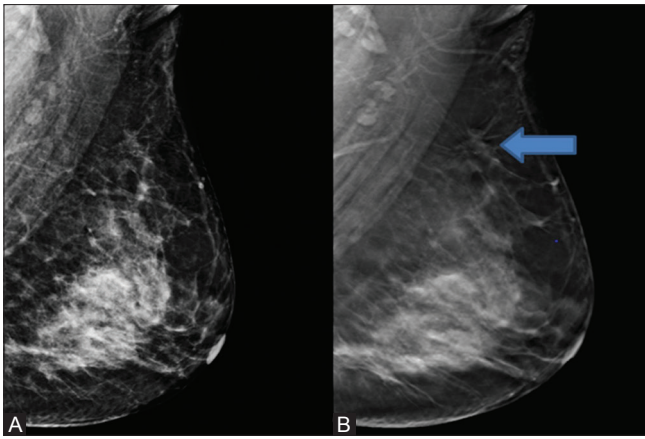
**Table 12: Comparison of sensitivity of FFDM versus FFDM plus DBT in different age groups**

	Sensitivity		P
	FFDM	FFDM + DBT	
<40 years	50.0%	100.0%	0.047
41-50 years	80.0%	100.0%	0.035
51-60 years	92.9%	100.0%	0.309
61-70 years	100.0%	100.0%	-
>70 years	100.0%	100.0%	-

**Table 13: Comparison of specificity of FFDM versus FFDM plus DBT in different age groups**

	Specificity		P
	FFDM	FFDM + DBT	
<40 years	50.0%	75.0%	0.301
41-50 years	37.9%	75.9%	0.003
51-60 years	33.3%	66.7%	0.157
61-70 years	0%	100.0%	0.014
>70 years	50.0%	100.0%	0.248





**Figure 1 (A and B):** Patient came for screening: On FFDM MLO view (A), left breast shows heterogeneously dense parenchyma (ACR Category c). No spiculated mass or suspicious calcifications are seen. BIRADS I. On FFDM plus DBT MLO view (B), left upper quadrant shows an irregular, ill-defined, spiculated mass. BIRADS IV. HPE done later confirmed it to be malignant

**Table 14: Comparison of false positive rates of FFDM versus FFDM plus DBT in different age groups**

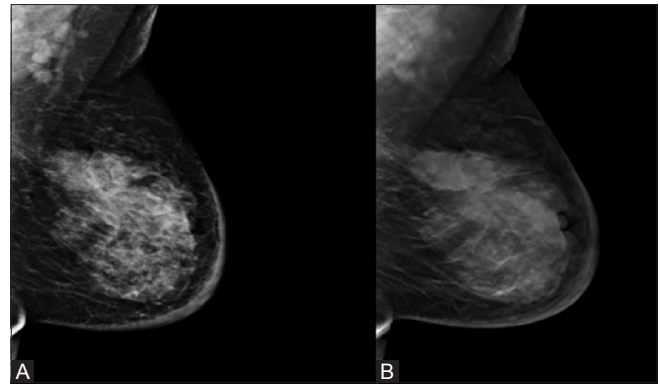
Age group	False positive rate		P
	FFDM	FFDM + DBT	
<40 years	28.6%	14.2%	0.35
41-50 years	36.7%	14.2%	0.01
51-60 years	26.1%	8.7%	0.12
61-70 years	30.0%	0.0%	0.06
>70 years	25%	0%	0.28

**Table 15: Comparison of positive predictive value by FFDM versus FFDM plus DBT in different age groups**

Age group	Positive predictive value		P
	FFDM	FFDM + DBT	
<40 years	42.8%	75.0%	0.2
41-50 years	47.1%	74.1%	0.03
51-60 years	68.4%	82.4%	0.33
61-70 years	70.0%	100.0%	0.11
>70 years	67%	100%	0.36

Significant increase in sensitivity ( $P = 0.003$ ), specificity ( $P = 0.0001$ ), positive predictive value ( $P = 0.003$ ), and decrease in false positive rates ( $P = 0.0006$ ) was seen with the addition of DBT to FFDM in the study group. Increase in cancer detection rates by addition of DBT to FFDM was not statistically significant ( $P = 0.25$ ) [Table 16].

In both diagnostic and screening groups, significant increase in sensitivity, specificity, positive predictive value, and decrease in false positive rates ( $P < 0.05$ ) were seen with the addition of DBT to FFDM. Increase in cancer detection rates by addition of DBT to FFDM was not statistically significant [Tables 17 and 18].



**Figure 2 (A and B):** Patient presented with left breast mass. On FFDM MLO view (A): Left breast shows heterogeneously dense parenchyma (ACR Category c). Left upper quadrant shows an oval, lobulated mass with obscured margins. No suspicious calcifications are seen. BIRADS IV. On FFDM plus DBT MLO view (B), left upper quadrant shows an oval, lobulated mass with spiculated margins. BIRADS V. Spiculations are more clearly visible with DBT

**Table 16: Comparative evaluation of diagnostic measurements of FFDM versus FFDM plus DBT**

	FFDM	FFDM + DBT	P
Sensitivity	83.6%	100.0%	0.003
Specificity	38.78%	76.4%	0.0001
False positive rate	32.00%	12.00%	0.0006
Positive predictive value	56.10%	80.30%	0.003
Cancer detection rate	41%	49%	0.25

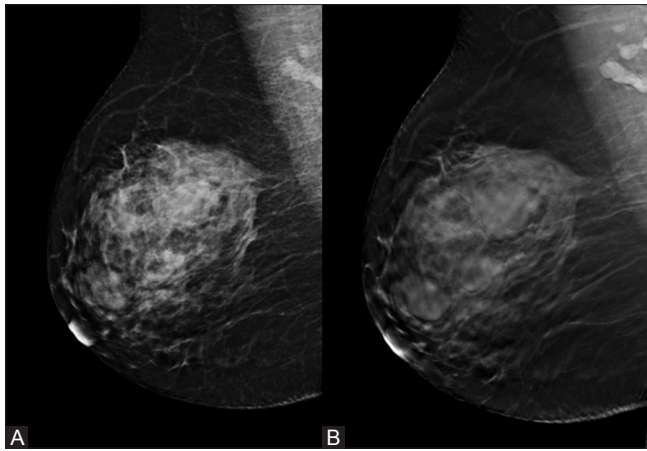
**Table 17: Comparative evaluation of diagnostic measurements of FFDM versus FFDM plus DBT in diagnostic setup**

	FFDM	FFDM + DBT	P
Sensitivity	88.4%	100.0%	0.021
Specificity	12.5%	68.8%	0.001
False positive rate	23.70%	8.40%	0.02
Positive predictive value	73.10%	89.50%	0.03
Cancer detection rate	64.40%	72.80%	0.32

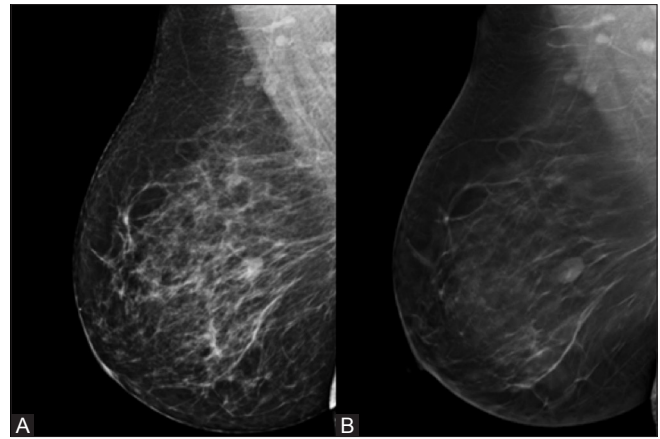
## Discussion

Tomosynthesis reconstruction from limited two-dimensional datasets has become possible only with the advent of fast reading digital detectors.<sup>[10-13]</sup> Mammographic spot compression views are additional views used in breast imaging for mass characterization. They reduce superimposition of overlapping tissue and improve tissue contrast, margin visibility, and image details.

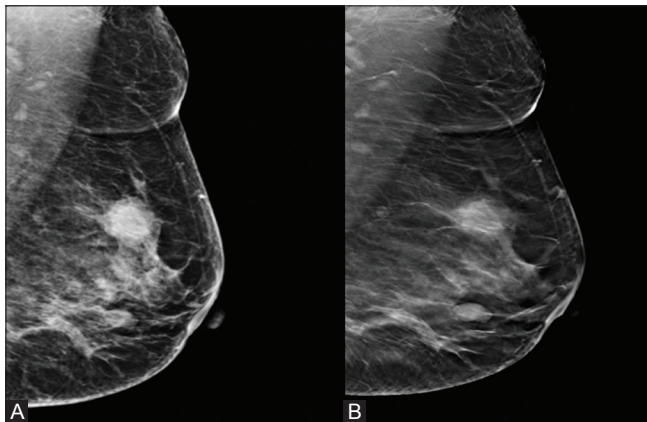
Combining digital mammography with tomosynthesis offers many advantages. The presence of mammogram allows comparison with prior examinations and provides a comprehensive view of the breast while the addition of tomosynthesis minimizes the effect of tissue overlap and allows better visualization of breast lesions. Thus,



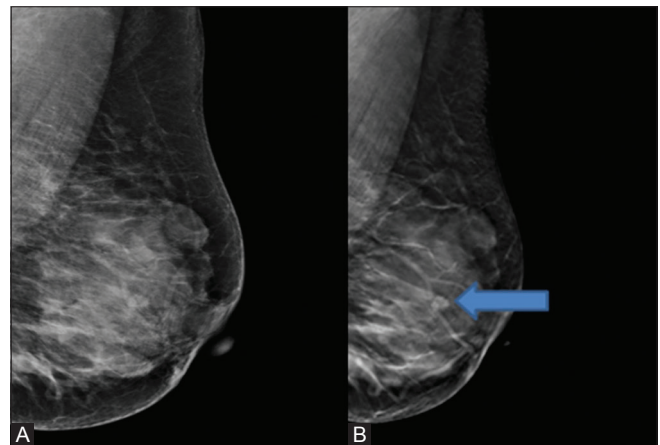
**Figure 3 (A and B):** Patient presented with right breast lump. On FFDM MLO view (A): right breast shows heterogeneously dense breast (ACR Category c). Right upper quadrant shows multiple round to oval masses with partly obscured margins. No suspicious calcifications are seen. BIRADS IV. On FFDM plus DBT MLO view (B), Right upper quadrant shows multiple round to oval masses with well-defined margins. BIRADS III



**Figure 4 (A and B):** Patient presented for screening: On FFDM MLO view (A), scattered fibroglandular parenchyma (ACR Category b) is seen. Right central quadrant shows an oval mass with partly obscured margins. No suspicious calcifications are seen. BIRADS IV. On FFDM plus DBT MLO view (B), Right central quadrant shows an oval mass with well-defined margins. BIRADS III



**Figure 5 (A and B):** Patient presented with left breast mass. On FFDM MLO view (A): left breast shows scattered fibroglandular parenchyma (ACR Category b). Left upper quadrant shows a round mass with partly spiculated, obscured margins. No suspicious calcifications are seen. BIRADS IV. On FFDM plus DBT MLO view (B), left upper quadrant shows a round mass with spiculated, microlobulated margins (BIRADS IV) with an additional well-defined oval nodule seen in the left central quadrant, likely benign (BIRADS III)



**Figure 6 (A and B):** Patient presented for screening. On FFDM MLO view (A): Left breast shows heterogeneously dense parenchyma (ACR Category c). Left upper quadrant shows an oval well-defined mass, likely benign. No suspicious calcifications are seen. BIRADS III. On FFDM plus DBT MLO view (B), left breast shows well-defined oval mass (BIRADS III) in upper quadrant along with another well-defined round mass in central quadrant. BIRADS III

**Table 18: Comparative evaluation of diagnostic measurements of FFDM versus FFDM plus DBT in screening setup**

	FFDM	FFDM + DBT	P
Sensitivity	50.0%	100.0%	0.046
Specificity	48.6%	80%	0.006
False positive rate	43.90%	17.10%	0.008
Positive predictive value	14.20%	46.10%	0.04
Cancer detection rate	7.30%	14.60%	0.28

the relative strengths of the two modalities are retained with the combined approach. Although there is increased radiation exposure by use of tomosynthesis along with mammography compared to mammography alone, this

exposure is below the limits set by the United States FDA and constitutes an acceptable risk.<sup>[14,15]</sup>

Tomosynthesis was found to have comparable or superior image quality to that of film-screen mammography in the diagnostic setting, and recall rates decreased significantly when tomosynthesis was used along with digital screening mammography. The image quality of tomosynthesis was found to be equivalent or superior to diagnostic mammography in a majority of cases.<sup>[7-9,16,17]</sup>

In our study, we found that the most significant decrease was in recall rates due to reduction in false positive patients. A combination of the two modalities led to reduction in

BIRADS in 31 patients. Similar results have been seen in various other studies in which there may not be much change in cancer detection, however, there was a decrease in a number of false-positives.<sup>[18-21]</sup>

In our study, it was seen that FFDM plus DBT had better sensitivity, specificity, positive predictive value, and reduced false positive rates compared to FFDM alone in the overall study population as well as in diagnostic and screening setup. The results were similar to a previous study by Gennaro *et al.* who found that performance of tomosynthesis in one view at the same total dose as standard screen film mammography was not inferior to digital mammography in two views.<sup>[22]</sup> A study done by Rafferty revealed that diagnostic sensitivity and positive predictive values increased with addition of tomosynthesis.<sup>[23]</sup>

Nonsignificant increase in cancer detection rates of 8% ( $P = 0.25$ ) was seen in our study with the addition of digital breast tomosynthesis. This was in accordance with the previous studies. In our study, significant increase in positive predictive value was noted in both diagnostic and screening population and overall population, which was similar to a study done previously by Rose *et al.*<sup>[19]</sup>

Calcifications are depicted well with FFDM. Some authors have suggested that DBT may not depict calcifications as well as traditional mammography.<sup>[7,24]</sup>

Significant decrease in recall rates with addition of DBT to FFDM was also seen in ACR categories b, c, d and age groups <40 years due to improved sensitivity, specificity, positive predictive value, and reduced false positive value. Our results are in concordance with the study done by Haas *et al.* who reported decreased recall rates in those with dense breasts and patients aged <50 years.

In conclusion, addition of DBT to FFDM results in statistically significant increase in sensitivity, specificity, and positive predictive value, and statistically significant decrease in false positive rates in both diagnostic and screening cases. Cancer detection rate also increases with addition of DBT to FFDM.

#### Learning points

- Mammography alone has low sensitivity and high false-positive rates
- Tomosynthesis may be added to FFDM to increase the diagnostic accuracy in both diagnostic and screening patients
- Improvement in diagnostic accuracy is seen in younger population and dense breasts
- Advances in breast cancer screening are regularly required to increase early detection of breast cancer
- Calcifications may not be seen that well on DBT.

#### Ethical approval

Ethical committee approval was taken from hospital ethical committee.

#### Financial support and sponsorship

No funding was received from any company whatsoever.

#### Conflicts of interest

Authors declare no conflicts of interest.

#### References

1. International Agency for Research on Cancer. GLOBOCAN 2012: estimated cancer incidence, mortality and prevalence worldwide [Internet]. 2012 [Accessed on June 2015]. Available from: [http://globocan.iarc.fr/Pages/fact\\_sheets\\_cancer.aspx](http://globocan.iarc.fr/Pages/fact_sheets_cancer.aspx).
2. Shtern F. Digital mammography and related technologies: A perspective from the National Cancer Institute. *Radiology* 1992;183:629-30.
3. Humphrey LL, Helfand M, Chan BK, Woolf SH. Breast cancer screening: A summary of the evidence for the U.S. Preventive Services Task Force. *Ann Intern Med* 2002;137:347-60.
4. Fletcher SW, Elmore JG. Clinical practice. Mammographic screening for breast cancer. *N Engl J Med* 2003;348:1672-80.
5. Rafferty EA. Digital mammography: Novel applications. *Radiol Clin North Am* 2007;45:831-43.
6. Lewin JM, Niklason L. Advanced applications of digital mammography: Tomosynthesis and contrast-enhanced digital mammography. *Semin Roentgenol* 2007;42:243-52.
7. Poplack SP, Tosteson TD, Kogel CA, Nagy HM. Digital breast tomosynthesis: Initial experience in 98 women with abnormal digital screening mammography. *AJR Am J Roentgenol* 2007;189:616-23.
8. Andersson I, Ikeda DM, Zackrisson S, Ruschin M, Svahn T, Timberg P, *et al.* Breast tomosynthesis and digital mammography: A comparison of breast cancer visibility and BIRADS classification in a population of cancers with subtle mammographic findings. *Eur Radiol* 2008;18:2817-25.
9. Gur D, Abrams GS, Chough DM, Ganott MA, Hakim CM, Perrin RL, *et al.* Digital breast tomosynthesis: Observer performance study. *AJR Am J Roentgenol* 2009;193:586-91.
10. Baker JA, Lo JY. Breast tomosynthesis: State-of-the-art and review of the literature. *Acad Radiol* 2011;18:1298-310.
11. Diekmann F, Bick U. Breast tomosynthesis. *Semin Ultrasound CT MR* 2011;32:281-7.
12. Helvie MA. Digital mammography imaging: Breast tomosynthesis and advanced applications. *Radiol Clin North Am* 2010;48:917-29.
13. Rafferty EA. Breast tomosynthesis. *Semin Breast Dis* 2006;9:111-8.
14. Uematsu T. The emerging role of breast tomosynthesis. *Breast Cancer* 2013;20:204-12.
15. Feng SS, Sechopoulos I. Clinical digital breast tomosynthesis system: Dosimetric characterization. *Radiology* 2012;263:35-42.
16. Hakim CM, Chough DM, Ganott MA, Sumkin JH, Zuley ML, Gur D. Digital breast tomosynthesis in the diagnostic environment: A subjective side-by-side review. *AJR Am J Roentgenol* 2010;195:W172-6.
17. Noroozian M, Hadjiiski L, Rahnama-Moghadam S, Klein KA, Jeffries DO, Pinsky RW, *et al.* Digital breast tomosynthesis is comparable to mammographic spot views for mass characterization. *Radiology* 2012;262:61-8.
18. Haas BM, Kalra V, Geisel J, Raghu M, Durand M, Philpotts LE. Comparison of tomosynthesis plus digital mammography and

- digital mammography alone for breast cancer screening. *Radiology* 2013;269:694-700.
19. Rose SL, Tidwell AL, Bujnoch LJ, Kushwaha AC, Nordmann AS, Sexton R Jr. Implementation of breast tomosynthesis in a routine screening practice: An observational study. *AJR Am J Roentgenol* 2013;200:1401-8.
  20. Skaane P, Bandos AI, Gullien R, Eben EB, Ekseth U, Haakenaasen U, *et al.* Prospective trial comparing Full field digital mammography (FFDM) versus combined FFDM and tomosynthesis in a population based screening programme using independent double reading with arbitration. *Eur Radiol* 2013;23:2061-71.
  21. Gilbert FJ, Tucker L, Gillan MG, Willsher P, Cooke J, Duncan KA, *et al.* The TOMMY trial: a comparison of TOMosynthesis with digital MammographY in the UK NHS Breast Screening Programme-a multicentre retrospective reading study comparing the diagnostic performance of digital breast tomosynthesis and digital mammography with digital mammography alone. *Health Technol Assess* 2015;19:i-xxv.
  22. Gennaro G, Toledano A, di Maggio C, Baldan E, Bezzon E, La Grassa M, *et al.* Digital breast tomosynthesis versus digital mammography: A clinical performance study. *Eur Radiol* 2010;20:1545-53.
  23. Rafferty EA, Park JM, Philpotts LE, Poplack SP, Sumkin JH, Halpern EF, *et al.* Assessing radiologist performance using combined digital mammography and breast tomosynthesis compared with digital mammography alone: Results of a multicentre, multireader trial. *Radiology* 2013;266:104-13.
  24. Spangler ML, Zuley ML, Sumkin JH, Abrams G, Ganott MA, Hakim C, *et al.* Detection and classification of calcifications on digital breast tomosynthesis and 2D digital mammography: A comparison. *AJR Am J Roentgenol* 2011;196:320-4.