

Analysis of the time course of changes in imaging findings of small arteries embolized with the N-Butyl cyanoacrylate-lipiodol mixture

Hiroyuki Tokue^{1,2}, Azusa Tokue¹, Yoshito Tsushima¹

¹Department of Diagnostic and Interventional Radiology, Gunma University Hospital, ²Department of Radiology, Maebashi Red Cross Hospital, Gunma, Japan

Correspondence: Dr. Hiroyuki Tokue, Department of Diagnostic and Interventional Radiology, Gunma University Hospital, Gunma, Japan.
E-mail: tokue@s2.dion.ne.jp

Abstract

Background: There are no reports analyzing imaging findings of arteries embolized with N-butyl cyanoacrylate (NBCA)-Lipiodol. To evaluate the time course of changes in the imaging findings of small arteries embolized with NBCA-Lipiodol. **Materials and Methods:** Selective transcatheter arterial embolization procedures via the inferior phrenic artery (right IPA, $n = 25$; left IPA, $n = 5$) were performed in 30 patients (25 males, 5 females; mean age 63 years, range: 45–78) at our institution. The NBCA-Lipiodol mixture was used as an embolic agent. The ratio of NBCA to Lipiodol was 1:4 (Group-A, $n = 16$) or 1:8 (Group-B, $n = 14$). We retrospectively reviewed the computed tomography (CT) findings and outcomes of small arteries embolized with the NBCA-Lipiodol mixture. The residual lipiodol was compared between Group-A and Group-B. The Student's *t*-test and Chi-square test were used for statistical analyses. In addition, the residual lipiodol rate was calculated using the Kaplan–Meier method and compared using the log-rank test. **Results:** The mean observation period was 264 ± 84 days (range: 104–425). Lipiodol completely disappeared in 20 arteries (66%) during follow-up. Recanalization of arterial flow was not seen in CT images, even when Lipiodol disappeared. Group-B showed a shorter period of progression to disappearance of Lipiodol than Group-A ($P < 0.05$). On follow up, the rate of residual Lipiodol in Group-A was higher than that in Group-B ($P < 0.05$). **Conclusion:** Residual Lipiodol was expected to gradually disappear. Lipiodol disappeared early when the density of NBCA was low in the NBCA-Lipiodol mixture. Further evaluations of various arteries and ratios of NBCA to Lipiodol are needed.

Key words: Embolization; lipiodol; N-butyl cyanoacrylate; recanalization

Background

Transcatheter arterial embolization (TAE) with the N-butyl cyanoacrylate (NBCA)-Lipiodol mixture is widely used. NBCA is indicated for various conditions, including

vascular conditions (aneurysms and malformations), bleeding (iatrogenic damage, trauma, and inflammation), tumors, and venous disease (varices and portal vein system disease), regardless of the location of the target lesion. There have been many reports on the use of NBCA

This is an open access journal, and articles are distributed under the terms of the Creative Commons Attribution-NonCommercial-ShareAlike 4.0 License, which allows others to remix, tweak, and build upon the work non-commercially, as long as appropriate credit is given and the new creations are licensed under the identical terms.

For reprints contact: reprints@medknow.com

Cite this article as: Tokue H, Tokue A, Tsushima Y. Analysis of the time course of changes in imaging findings of small arteries embolized with the N-Butyl cyanoacrylate-lipiodol mixture. Indian J Radiol Imaging 2018;28:81-4.

Access this article online

Quick Response Code:



Website:
www.ijri.org

DOI:
10.4103/ijri.IJRI_112_17

for treating cerebral vascular malformations, and some prospective studies have examined its use for preoperative vascular embolization.^[1,2] However, there are no reports analyzing imaging findings of arteries embolized with the NBCA-Lipiodol mixture. In this study, we report the time course of the changes in imaging findings of small arteries embolized with the NBCA-Lipiodol mixture.

Materials and Methods

The protocol of this retrospective study was approved by our research ethics board without the need for informed consent. We retrospectively reviewed the computed tomography (CT) findings and outcomes of small arteries embolized with the NBCA-Lipiodol mixture. From January 2005 to September 2015, selective TAE via the inferior phrenic artery (right IPA, $n = 25$; left IPA, $n = 5$) with the NBCA-Lipiodol mixture was performed among 30 patients (25 males, 5 females; mean age, 63 years, range: 45–78) at our institution. All patients had successfully undergone placement of a percutaneous implantable port-catheter system for repeated hepatic arterial infusion chemotherapy (HAIC) for primary hepatocellular carcinoma (HCC) or liver metastasis from colon cancer at our institution. The IPA was embolized to allow distribution of anticancer drugs in the entire tumor-bearing liver. We performed embolization with the NBCA-Lipiodol mixture when hepatopetal flow from an IPA was confirmed by selective arteriography. A 1.9–2.1-Fr microcatheter was used for selective transarterial infusion into the IPA [Figure 1A]. The NBCA-Lipiodol mixture was used as an embolic agent. The ratio of NBCA to Lipiodol was 1:4 (Group-A, $n = 16$) or 1:8 (Group-B, $n = 14$). Redistribution of anticancer drugs in the entire tumor-bearing liver was achieved in all the cases.

In all 30 patients, unenhanced and contrast-enhanced (CE) CT of the entire abdomen was performed after TAE every 1 to 3 months. CT images were obtained using 64-slice

multidetector CT (MDCT) (Aquilion 64; Toshiba Medical Systems, Tokyo, Japan) with a 0.4-s rotation time and exposure parameters of 120 kV and 160 mA for all images. A total 100 ml of the contrast material (Iopamiron 370; Bayer Schering Pharma, Osaka, Japan) was injected into the antecubital vein at a rate of 3.3 ml/s using an automatic power injector. An iodine concentration of 370 mg I/ml (Iopamiron 370) was used. The examinations were performed in the cephalocaudal direction starting at the top of the liver, and each examination included nonenhanced and CE imaging. After nonenhanced imaging was performed in the transverse section, CE-CT was performed for 35 s (arterial phase), 70 s (portal phase), and 120 s (equilibrium phase) after intravenous administration of the contrast material. The following imaging parameters were used: collimation of 32×1 mm, pitch factor of 0.656, rotation time of 0.5 s, and 5-mm reconstruction interval (slice thickness). A standard algorithm was used for all image displays.

Arteries embolized with the NBCA-Lipiodol mixture were classified into four types based on CT findings according to the residual Lipiodol [Figure 1B]: Grade 1, good recognizable (residual Lipiodol was equal to the day when embolization was performed); Grade 2, fair recognizable; Grade 3, poor recognizable; and Grade 4, disappearance of Lipiodol. Recanalization of embolized arteries was defined as the presence of CE arteries in CT images. Image evaluations in the blinded reading for each patient (off-site assessment) were performed in random order by two investigators.

Residual Lipiodol was calculated from the day when embolization was performed until death or the last follow-up. The residual lipiodol was compared between Group-A and Group-B. Data were expressed by mean \pm standard deviation (SD). The Student's *t*-test and Chi-square test were used for statistical analyses, and a *P* value of 0.05 was considered significant. The residual lipiodol rate calculated using the Kaplan–Meier method and compared using the log-rank test. Data analysis was performed using SPSS for Windows, Version J15 (SPSS Inc., IL, USA).

Results

The mean observation period was 264 ± 84 days (range: 104–425). Lipiodol completely disappeared in 20 arteries (66%) during follow-up. Progression to Grade 2 required 99 ± 38 days, Grade 3 required 144 ± 53 days, and Grade 4 required 211 ± 71 days. Residual Lipiodol was expected to gradually disappear. Recanalization of arterial flow was not seen in CT images, even when Lipiodol disappeared. The presence of Lipiodol did not affect diagnostic or response evaluation.

Table 1 showed the required days of progression to each Grade in Group-A and Group-B. Group-B showed

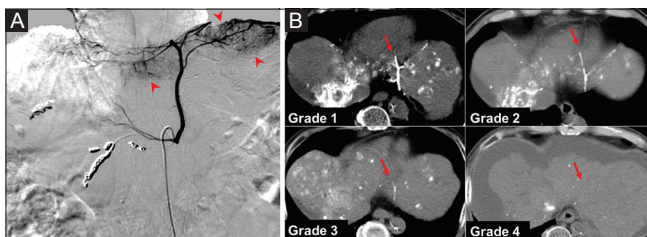


Figure 1 (A and B): (A) A 60-year-old-man underwent repeat hepatic arterial infusion chemotherapy (HAIC) for primary hepatocellular carcinoma (HCC). On follow-up, the left inferior phrenic artery (IPA) supplied the HCC of the left hepatic lobe (arrowheads). IPA was embolized with the NBCA-Lipiodol mixture to allow distribution of anticancer drugs. (B) Visual evaluation of residual Lipiodol. Residual Lipiodol was seen just after embolization with the NBCA-Lipiodol mixture (Grade 1). In follow-up CT, progression to Grade 2 required 62 days, Grade 3 required 120 days, and Grade 4 required 159 days after embolization. Residual Lipiodol was expected to gradually disappear (arrows)

significant shorter period of progression to each Grade than Group-A ($P < 0.05$). The rates of residual Lipiodol are shown in Figure 2. The rate of residual Lipiodol in Group-A was higher than that in Group-B ($P < 0.05$).

The absolute volumes of a mixture of NBCA and Lipiodol were 1.5–2.5 cc, and there was no significant difference within the two groups. In addition, there was no significant difference in the length of embolized segments or diameters of IPA.

Discussion

NBCA (Histoacryl; B. Braun, Melsungen, Germany) has been used in endoscopic sclerotherapy for esophageal varices and in the treatment of bleeding disorders and arteriovenous malformations (AVM); the liquid is mixed with an oily contrast medium that is mainly composed of the ethyl ester of iodinated poppy seed oil fatty acids (Lipiodol, Guerbet Japan, Tokyo, Japan) and injected into blood vessels.^[1]

In Japan, it has been used for hysterosalpingography and lymphangiography. When NBCA is mixed with Lipiodol, NBCA becomes radiopaque and its polymerization time is increased.^[2–4] It is necessary to change the NBCA-Lipiodol mixing ratio depending on the situation. The amount of

Lipiodol should be decreased when attempting to embolize short segments, and it should be increased when attempting to embolize long segments.^[1,5] We used 1:8 mixtures when the artery was a long segment, however, it depends on the operator.

For long-term HAIC, it is important to maintain anticancer drug infusion via a single indwelling catheter that allows distribution into the entire tumor-bearing region in the liver; this is done after conversion of multiple hepatic arteries into a single vascular supply and occlusion of a parasitic blood supply from extrahepatic arteries to liver segments in which tumors exist.

Interventional radiologic techniques that can be used to maintain these conditions require carefully planned TAE with embolic agents in addition to percutaneous placement of an indwelling port-catheter system.^[6]

The IPA is one of the extrahepatic arteries to liver segments in which tumors exist. The IPA is sometimes embolized with the NBCA-Lipiodol mixture for distribution of anticancer drugs to the entire tumor-bearing liver. In previous reports, the NBCA-Lipiodol mixture was useful in the embolization of long segmental arteries in a cast, as indicated by 14 right IPAs embolized successfully with the single use of the NBCA-Lipiodol mixture without recanalization.^[6] On the other hand, some cases of recanalization of arterial flow have been reported after TAE using NBCA.^[7,8]

There are no reports analyzing imaging findings of arteries embolized with NBCA-Lipiodol. In the present study, residual Lipiodol was expected to gradually disappear. Lipiodol disappeared early when the density of NBCA was low in the NBCA-Lipiodol mixture. Recanalization of arterial flow was not seen on CT images, even when Lipiodol disappeared.

Some papers have reported the mechanism of Lipiodol disappearance. Pathological findings of a mixture of NBCA and Lipiodol showed that Lipiodol localizes in the central regions of blood vessels, whereas NBCA is deposited in the peripheral regions of blood vessels.^[9]

After embolization with a mixture of NBCA and Lipiodol, histological finding showed polymorphonuclear cells and lymphocystic infiltration in the acute phase (during the first 24 hours). Transmural lymphocystic infiltration and foreign body giant cells were seen in the chronic phase (after 1 month). Through these processes, a mixture of NBCA and Lipiodol was phagocytosed and disappeared.^[10]

Our study has several limitations. The study population and observation time were small, and this was a nonprospective, nonrandomized, observational study. Hence, there was no control population for HAIC procedures at our institution.

Table 1: The required days of progression to each Grade in Group A and Group B

	Group A	Group B	P
N	16	14	
Male/female	13/3	12/2	0.743
Age (years)	61±8	64±8	0.330
Embolized artery			
Right IPA/left IPA	13/3	12/2	0.743
Progression to Grade 2 (days)	119±36	89±41	0.041*
Grade 3 (days)	167±52	133±36	0.046*
Grade 4 (days)	256±80	176±34	0.018*
Observation time (days)	282±92	243±66	0.194
Complete disappearance of lipiodol	9 (56%)	11 (79%)	0.196

* $P < 0.05$

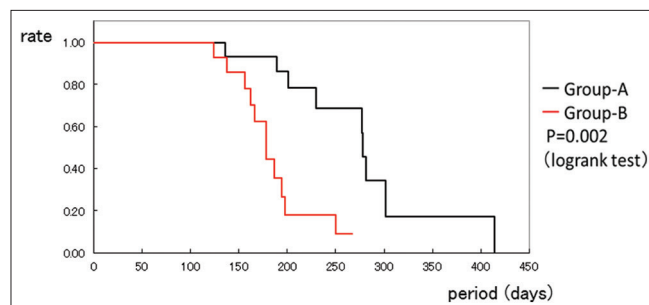


Figure 2: Residual rates of Lipiodol in arteries embolized with the NBCA-Lipiodol Mixture. Residual rate of Lipiodol was analyzed using the Kaplan-Meier method. The rate of residual Lipiodol in Group-A was higher than that in Group-B (P value = 0.002)

The residual and disappearance rates of Lipiodol alone were not evaluated. Moreover, we evaluated only IPA embolization. The method of embolization may have varied depending on the operator.

Conclusions

We evaluated the time course changes in imaging findings of small arteries embolized with the NBCA-Lipiodol mixture. Residual Lipiodol was expected to gradually disappear. Lipiodol disappearance does not necessarily mean recanalization. Further evaluations of various arteries and ratios of NBCA to Lipiodol were needed.

Authors' contributions

HT contributed to the writing of the manuscript. All authors read and approved the final manuscript.

Consent for publication

Written informed consent for publication was obtained from all patients and residents participating in the study.

Ethics approval and consent to participate

Written informed consent was obtained from all patients and residents participating in the study, as approved by the ethics committee of Maebashi Red Cross hospital.

Financial support and sponsorship

The authors received no financial support for research or for authorship of this article.

Conflicts of interest

The authors declare that they have no competing interests.

References

1. Takeuchi Y, Morishita H, Sato Y, Hamaguchi S, Sakamoto N, Tokue H, *et al.* Guidelines for the use of NBCA in vascular embolization devised by the Committee of Practice Guidelines of the Japanese Society of Interventional Radiology (CGJSIR), 2012 edition. *Jpn J Radiol* 2014;32:500-17.
2. The n-BCA Trial Investigators. N-butyl cyanoacrylate embolization of cerebral arteriovenous malformations: Results of a prospective, randomized, multi-center trial. *Am J Neuroradiol* 2002;23:748-55.
3. McConnell KA, Tjoumakaris SI, Allen J, Shapiro M, Bescke T, Jabbour PM, *et al.* Neuroendovascular management of dural arteriovenous malformations. *Neurosurg Clin N Am* 2009;20:431-9.
4. Turner WW Jr, Ellman BA. Transhepatic embolization in patients with acute variceal hemorrhage. *Am J Surg* 1981;142:731-4.
5. Pollak JS, White RI Jr. The use of cyanoacrylate adhesives in peripheral embolization. *J Vasc Interv Radiol* 2001;12:907-13.
6. Yamagami T, Kato T, Iida S, Tanaka O, Nishimura T. Value of transcatheter arterial embolization with coils and n-butyl cyanoacrylate for long-term hepatic arterial infusion chemotherapy. *Radiology* 2004;230:792-802.
7. Matsumoto K, Ushijima Y, Tajima T, Nishie A, Hirakawa M, Ishigami K, *et al.* Recanalization of splenic artery aneurysm after transcatheter arterial embolization using N-butyl cyanoacrylate. *Cardiovasc Intervent Radiol* 2010;33:187-90.
8. Ishikawa M, Kakizawa H, Yamasaki W, Date S, Hieda M, Kajiwara K, *et al.* Recanalization after successful occlusion by transcatheter arterial embolization with N-butyl cyanoacrylate for traumatic splenic artery injury. *Hiroshima J Med Sci* 2011;60:87-90.
9. Stoesslein F, Ditscherlein G, Romaniuk PA. Experimental studies on new liquid embolization mixtures (histoacryl-lipiodol, histoacryl-panthopaque). *Cardiovasc Intervent Radiol* 1982;5:264-7.
10. Gruber A, Mazal PR, Bavinski G, Killer M, Budka H, Richling B. Repermeation of partially embolized cerebral arteriovenous malformations: A clinical, radiologic, and histologic study. *Am J Neuroradiol* 1996;17:1323-31.