

CASE REPORT

Bilio-cutaneous fistula obliteration with NBCA

Antonio Bottari, Salvatore Silipigni, Alberto Stagno, Simona Caloggero¹

Department of Biomedical and Dental Sciences and Morphofunctional Imaging, University of Messina, ¹Department of Diagnostic Imaging and Radiotherapy, University Hospital "G. Martino", Messina, Italy

Correspondence: Dr. Antonio Bottari, Department of Biomedical and Dental Sciences and Morphofunctional Imaging, University of Messina, Viale Gazzi, Messina, Italy. E-mail: bottaria@unime.it

Abstract

Biliary fistula and bile leakage are complications that can occur during hepato-biliary surgery (both open and laparoscopic) and percutaneous biliary intervention. In some cases, spontaneous resolution is documented but more often re-intervention (surgical or percutaneous) is necessary. We present the case of a male patient who underwent right hepatectomy with bilio-digestive anastomosis for a cholangiocarcinoma which developed a bilo-cutaneous fistula through the path of a previously inserted percutaneous transhepatic drainage. Sealing of bilo-cutaneous fistula was obtained using N-butyl-Cyanoacrylate. This technique has already been reported in some papers as a useful tool for biliary tree obliteration; however, to our knowledge, no cases describing the use of glue to seal a sub-cutaneous route are available in literature.

Key words: Biliary tree; cholangiography; fistula; NBCA; obliteration

Case Report

A 72-year-old man affected by cholangiocarcinoma (Klatskin 3a) who underwent right hepatectomy with a biliodigestive anastomosis (Roux-en-Y), was referred to our Department to perform a 1-year follow-up MRI scan.

MRI showed intrahepatic biliary dilation caused by stenosed anastomosis. Multidisciplinary board decided for percutaneous bilioplasty. PTBD was positioned through left access.

A month later, biliary drainage revision was necessary because of bile leakage through cutaneous access of PTBD. Conservative treatment was chosen; therefore, replacement of biliary drainage with higher French scaling was successfully performed. PTBD was removed 3 months later after a normal cholangiogram.

Within 8 days from PTBD removal, biliary leakage of 150 cc/day re-appeared, compelling the placement of a new PTC under US guidance through left biliary system was performed.

Cholangiography showed a bilio-cutaneous fistula at the entry site of previous PTBD [Figure 1].

The point of leakage was then reached through biliary tree with a 0.035" hydrophilic guidewire (Radifocus® Guidewire M Standard type, Terumo, Tokyo, Japan) and a multipurpose 4F vascular catheter (Cordis, Fremont, California); a mixture of Lipiodol (Guerbet, Villepinte, France) and N-butyl-Cyanoacrylate (Glubran 2, GEM, Italy) was then injected [Figure 2].

This is an open access journal, and articles are distributed under the terms of the Creative Commons Attribution-NonCommercial-ShareAlike 4.0 License, which allows others to remix, tweak, and build upon the work non-commercially, as long as appropriate credit is given and the new creations are licensed under the identical terms.

For reprints contact: reprints@medknow.com

Cite this article as: Bottari A, Silipigni S, Stagno A, Caloggero S. Bilio-cutaneous fistula obliteration with NBCA. Indian J Radiol Imaging 2019;29:310-2.

Received: 29-Jan-2019

Revision: 03-Apr-2019

Accepted: 05-Jun-2019

Published: 30-Oct-2019

Access this article online

Quick Response Code:



Website:
www.ijri.org

DOI:
10.4103/ijri.IJRI_16_19

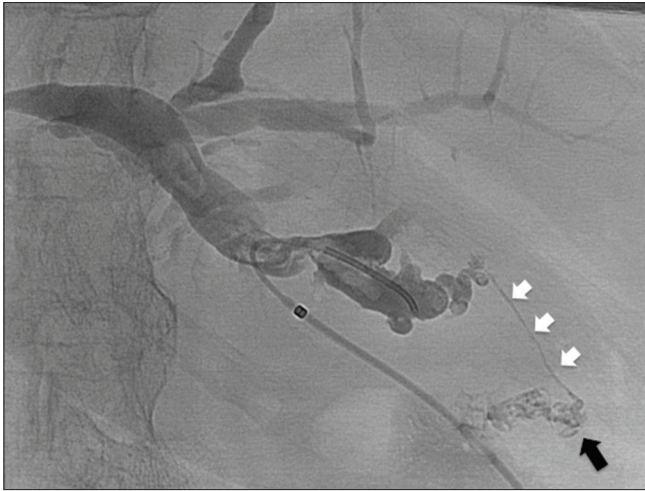


Figure 1: Cholangiography made through an angiographic catheter show the fistula (white arrows) and the leakage (black arrow) at the entry site of previous PTBD

The final cholangiography demonstrated complete obliteration of the fistula and no more bile leakage was observed [Figure 3A and B].

Patient was discharged after 3 days and no recurrence was documented during the 3 months follow-up.

Discussion

Biliary fistula and bile leakage are complications that may occur during hepato-biliary surgery (both open and laparoscopic) and percutaneous biliary interventions.^[1-3]

Variations in biliary anatomy can increase the risk of ductal injuries.

Adequate pre-operative imaging evaluation (CT and/or MRCP) may reduce the incidence of bile duct injury with occurrence of leakage.^[4,5]

Damaged bile ducts (isolated or communicating with the main biliary tree) may leak directly into the abdomen from the time of intervention or develop fistulas through thoracic wall to the skin, along percutaneous transhepatic drainage (PTBD).^[1]

Acute injuries may not be detected immediately during procedures, enduring silently, resolve spontaneously or they can reveal as bile peritonitis, prolonged time of wound healing and lately with malabsorption.^[6,7]

The high rate of morbidity and mortality related to surgical reoperation in such delicate patients making endoscopic and interventional radiology techniques the best choice treatments.^[8-10]

Development of cutaneous biliary leakage is a well-known and frequent complication that occurs in patients who keep

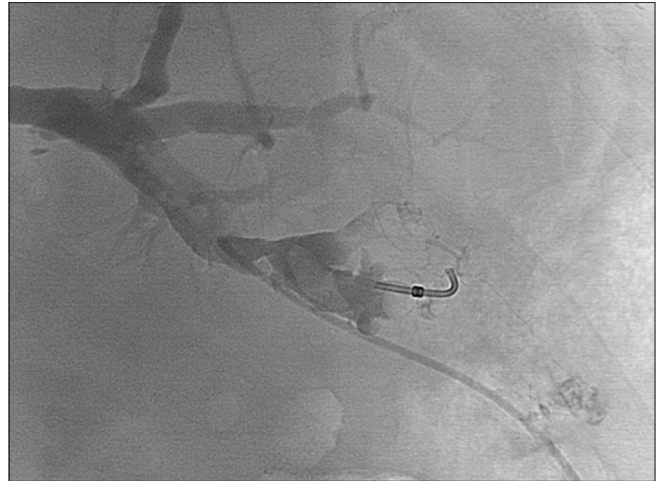


Figure 2: Selective catheterization of the fistula followed by injection of a mixture of Lipiodol and NBCA

PTBD catheters in place for a long time. The occurrence of secondary obstructions to bile discharge (e.g., debris, malignant stenosis) represent a constant cause of bile spreading in the space between the catheter and surrounding tissues.

Usually this condition is solved by removing the cause of obstruction, but in many cases bile leakage persist or, more often, no clear evidence of a possible cause is found, with a good antegrade bile drainage to duodenum at percutaneous cholangiography (PTC).

In other conditions a normal cholangiogram would suggest PTBD removal and patient discharge but in the presence of a cutaneous leakage the first option is the insertion of a larger PTBD with more discomfort and longer time of hospitalization for the patient.

Different materials have already been studied and tested to seal the biliary tract, in particular fibrin,^[11] ethanol,^[12] and NBCA.^[1,2,13-16]

These studies, based on case reports or small series, demonstrated that the latter is safer and more effective.

Due to its efficacy on biliary tree, in addition on its established role as embolic agent in different endovascular procedures,^[17-19] we decided to use NBCA to treat our patient.

We have found no literature cases in which the glue was used to seal a sub-cutaneous route; in conclusion we find that NBCA can be successfully employed in this field in order to improve patient comfort and shorten hospital stay.

Declaration of patient consent

The authors certify that they have obtained all appropriate patient consent forms. In the form the patient(s) has/have

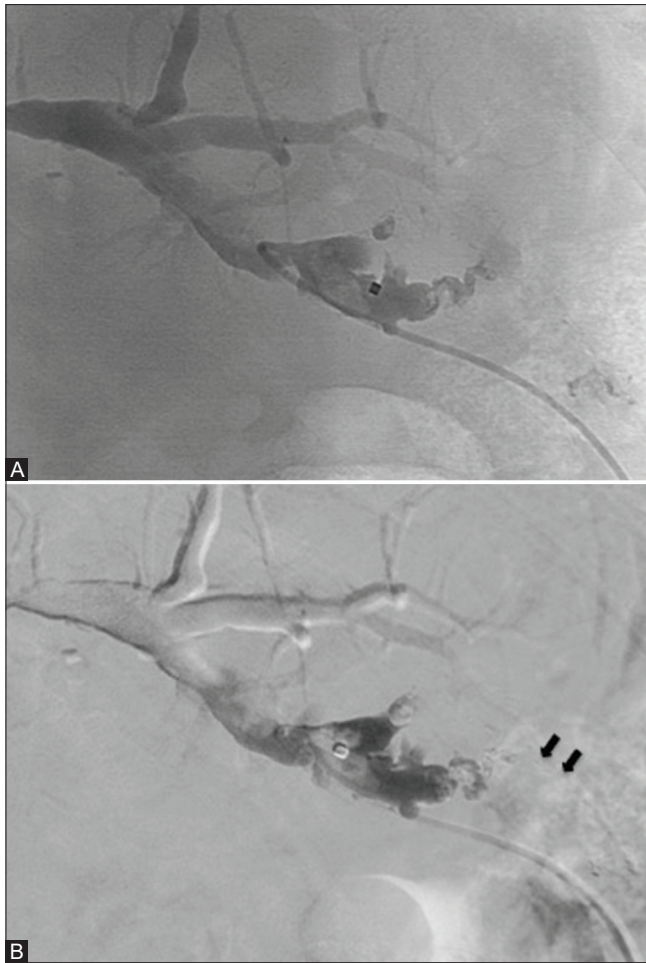


Figure 3 (A and B): The final cholangiography shows complete sealing of the fistula (A); with digital subtraction the mold of glue (black arrows) along the path is better appreciable (B)

given his/her/their consent for his/her/their images and other clinical information to be reported in the journal. The patients understand that their names and initials will not be published and due efforts will be made to conceal their identity, but anonymity cannot be guaranteed.

Financial support and sponsorship

Nil.

Conflicts of interest

There are no conflicts of interest.

References

1. Vu DN, Strub WM, Nguyen PM. Biliary duct ablation with N-butyl cyanoacrylate. *J Vasc Interv Radiol* 2006;17:63-9.
2. Görlich J, Rilinger N, Sokiranski R, Siech M, Vogel J, Wikström M, *et al.* Percutaneous transhepatic embolization of bile duct fistulas. *J Vasc Interv Radiol* 1996;7:435-8.

3. Seewald S, Groth S, Sriram PVJ, Xikun H, Akaraviputh T, Mendoza G, *et al.* Endoscopic treatment of biliary leakage with n-butyl-2 cyanoacrylate. *Gastrointest Endosc* 2002;56:916-9.
4. Sharif K, de Ville de Goyet J, Bile duct of Luschka leading to bile leak after cholecystectomy--revisiting the biliary anatomy. *J Pediatr Surg* 2003;38:E21-3.
5. Minutoli F, Naso S, Visalli C, Iannelli D, Silipigni S, Pitrone A, *et al.* A new variant of cholecystohepatic duct: MR cholangiography demonstration. *Surg Radiol Anat* 2015;37:539-41.
6. Smith AC, Schapiro RH, Kelsey PB, Warshaw AL. Successful treatment of nonhealing biliary-cutaneous fistulas with biliary stents. *Gastroenterology* 1986;90:764-9.
7. Lichtenstein S, Moorman DW, Malatesta JQ, Martin MF. The role of hepatic resection in the management of bile duct injuries following laparoscopic cholecystectomy. *Am Surg* 2000;66:372-6; discussion 377.
8. Ryan ME, Geenen JE, Lehman GA, Aliperti G, Freeman ML, Silverman WB, *et al.* Endoscopic intervention for biliary leaks after laparoscopic cholecystectomy: A multicenter review. *Gastrointest Endosc* 1998;47:261-6.
9. Kumar N, Thompson CC. Endoscopic therapy for postoperative leaks and fistulae. *Gastrointest Endosc Clin N Am* 2013;23:123-36.
10. Crinò SF, Novel endoscopic management for pancreatic pseudocyst with fistula to the common bile duct. *World J Gastrointest Endosc* 2014;6:620.
11. Brady AP, Malone DE, Deignan RW, O'Donovan N, McGrath FP. Fibrin sealant in interventional radiology: A preliminary evaluation. *Radiology* 1995;196:573-8.
12. Matsumoto T, Iwaki K, Hagino Y, Kawano K, Kitano S, Tomonari KI, *et al.* Ethanol injection therapy of an isolated bile duct associated with a biliary-cutaneous fistula. *J Gastroenterol Hepatol* 2002;17:807-10.
13. Lauterio A, Slim A, Aseni P, Giacomoni A, Di Sandro S, Corso R, *et al.* Percutaneous transhepatic bile duct ablation with n-Butyl cyanoacrylate in the treatment of a biliary complication after split liver transplantation. *J Transplant* 2009;2009:1-3.
14. Carrafiello G, Piacentino F, Ierardi A, Cardim L. Percutaneous transhepatic embolization of biliary leakage with N-butyl cyanoacrylate. *Indian J Radiol Imaging* 2012;22:19.
15. Mauri G, Pescatori LC, Mattiuz C, Poretti D, Pedicini V, Melchiorre F, *et al.* Non-healing post-surgical fistulae: Treatment with image-guided percutaneous injection of cyanoacrylic glue. *Radiol Med* 2017;122:88-94.
16. Kuran S, Disibeyaz S, Parlak E, Arhan M, Kacar S, Sahin B. Biliocutaneous fistula following alveolar hydatid disease surgery treated successfully with percutaneous cyanoacrylate. *Dig Dis Sci* 2006;51:18-20.
17. Wajswol E, Jazmati T, Contractor S, Kumar A. Portal vein embolization utilizing N-Butyl cyanoacrylate for contralateral lobe hypertrophy prior to liver resection: A systematic review and meta-analysis. *Cardiovasc Intervent Radiol* 2018;41:1302-12.
18. Caloggero S, Catanzariti F, Stagno A, Silipigni S, Bottari A. Use of a mixture of lipiodol and cyanoacrylate in percutaneous embolization treatment of symptomatic renal Angiomyolipomas: Our experience. *Radiol Case Rep* 2019;14:343-7.
19. Kim PH, Tsauo J, Shin JH, Yun S-C. Transcatheter arterial embolization of gastrointestinal bleeding with N -butyl cyanoacrylate: A systematic review and meta-analysis of safety and efficacy. *J Vasc Interv Radiol* 2017;28:522-531.e5.