

Primary presentation of Jeune's syndrome as gastric motility disorder in an infant: A case report

Amit Katyan, Shabnam Bhandari Grover, Heena Rajani, Deepak Bagga¹, Neha Antil

Departments of Radiology and Imaging, and ¹Pediatric Surgery, Vardhman Mahavir Medical College and Safdarjung Hospital, New Delhi, India

Correspondence: Dr. Shabnam Bhandari Grover, Department of Radiology and Imaging, Vardhman Mahavir Medical College and Safdarjung Hospital, New Delhi, India. E-mail: shabnamgrover@yahoo.com

Abstract

We report a case of a 4-week-old female neonate with Jeune's asphyxiating thoracic dystrophy (JATD) and coexistent situs anomaly, primarily presenting as gastric motility disorder. The child presented with abdominal distension and nonbilious vomiting since birth with failure to thrive. However, skeletal survey revealed JATD. Upper gastrointestinal contrast study showed situs inversus with delayed gastric emptying. Pyloric biopsy and intraoperative antro-duodenal manometry confirmed association of gastric motility disorder. Awareness of the unusual possibility of primary presentation of Jeune syndrome as gastric motility disorder will improve the management approach in such infants.

Key words: Gastrointestinal motility disorder; Jeune's asphyxiating thoracic dystrophy; situs inversus; skeletal survey; upper gastro-intestinal contrast study

Introduction

We report an infant presenting with clinical symptoms suspicious of gastric outlet obstruction, in which the radiographs and the gastrointestinal contrast series revealed underlying Jeune asphyxiating thoracic dystrophy (JATD) with motility disorder. Exploratory laparotomy failed to reveal any structural cause for obstruction. A recent report has proposed that JATD may present with foregut dysmotility.^[1] We report a new patient of JATD with an extremely rare constellation of associated anomalies comprising gastric motility disorder and situs inversus totalis. To the best of our knowledge and PubMed review, our report is the second case of such a syndromic association of JATD with gastric motility disorder and situs inversus.

Case Report

A female neonate of 4 weeks first presented to us in the emergency department with abdominal distension and recurrent non-bilious vomiting since birth, along-with failure to thrive. The baby, an offspring of non-consanguineous parents, was born at full term, by normal vaginal route, with no significant perinatal event or family history. However, no relevant antenatal records were available with the parents.

A thoraco-abdominal radiograph obtained in the emergency department revealed dextrocardia with a right sided over-distended stomach, narrow thoracic cage, and short horizontal ribs [Figure 1]. These observations suggested

This is an open access journal, and articles are distributed under the terms of the Creative Commons Attribution-NonCommercial-ShareAlike 4.0 License, which allows others to remix, tweak, and build upon the work non-commercially, as long as appropriate credit is given and the new creations are licensed under the identical terms.

For reprints contact: reprints@medknow.com

Cite this article as: Katyan A, Grover SB, Rajani H, Bagga D, Antil N. Primary presentation of Jeune's syndrome as gastric motility disorder in an infant: A case report. Indian J Radiol Imaging 2018;28:65-9.

Access this article online

Quick Response Code:



Website:
www.ijri.org

DOI:
10.4103/ijri.IJRI_303_17

a radiological diagnosis of Jeune's syndrome with situs inversus totalis. Skeletal survey and barium study were conducted for further evaluation.

On skeletal survey, the chest radiograph revealed narrow thorax, short, horizontally oriented ribs with expanded anterior ends, "handle-bar" appearance of clavicles along with dextrocardia [Figure 2]. The abdomino-pelvic radiograph revealed right-sided gastric lucency with curving of nasogastric tube along right side. Additionally, short iliac wings, sharp sacro-sciatic notches, spiky spur-like protrusions of iliac bone (resulting in trident appearance of the acetabula) were seen [Figure 3]. The findings on radiography were characteristic of JATD with situs inversus totalis. There was no polydactyly.

The barium series study revealed a right-sided over-distended stomach without any radiological signs of hypertrophic pyloric stenosis [Figure 4]. Subsequent radiographs showed significantly delayed gastric emptying till 5h, along-with dextroposition of the duodeno-jejunal junction and the duodenal loop [Figure 5]. On 24 h delayed radiographs, the "picture frame" appearance of large bowel was absent and the large bowel loops were seen in the midline of the abdomen [Figure 6]. These appearances further confirmed

situs inversus totalis along-with functional gastric outlet obstruction.

The kidneys and the urinary bladder were normal on ultrasound. Ocular examination was normal. Blood laboratory parameters were normal. In view of the characteristic radiological appearances, *IFT80* gene study was conducted, which further confirmed the diagnosis of JATD. At this stage, on further questioning of the parents regarding the antenatal records, they volunteered that the records were at a remote village and could not be easily retrieved. The parents also denied detection of any anomaly by the physician who had performed antenatal ultrasound examinations.

Exploratory laparotomy was undertaken, which did not reveal any mechanical cause of obstruction and a pyloric biopsy showed no evidence of pyloric stenosis. Intra-operative antro-duodenal manometry confirmed the radiological diagnosis of a motility disorder as a cause of gastric outlet obstruction and feeding jejunostomy was performed. However, in the early postoperative period, the parents took the child away from the hospital despite adequate medical counseling.

Discussion

JATD, which was first described by Jeune *et al.* (1955), has a reported incidence of 1 in 100,000–130,000 live births and is popularly recognized as a skeletal dysplasia.^[2,3] The diagnosis of JATD is primarily based on classical clinical

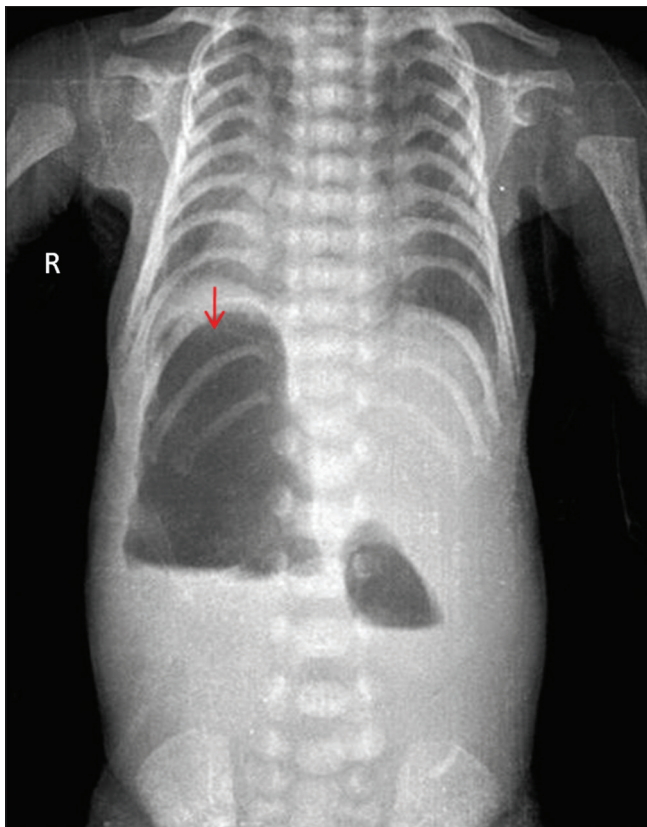


Figure 1: Thoraco-abdominal radiograph showing over-distended, right-sided stomach (red arrow) with narrow thoracic cage and short horizontally oriented ribs

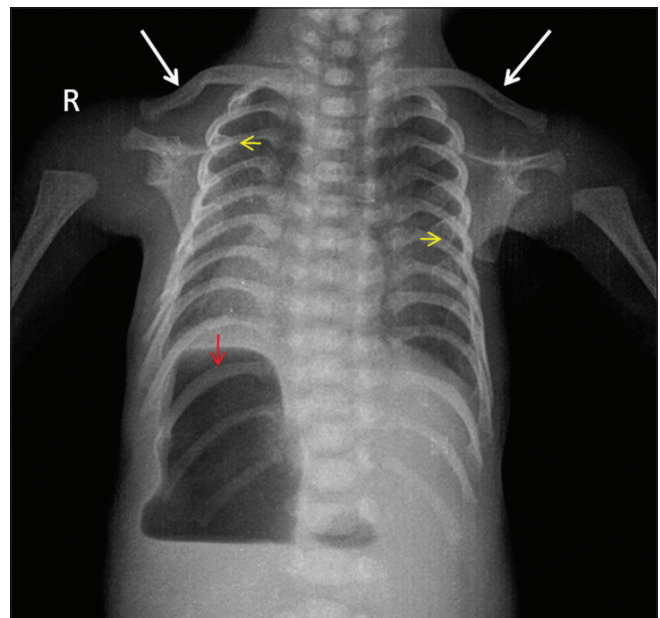


Figure 2: Plain radiograph of the thorax shows a narrow thorax, short, horizontally oriented ribs with expanded anterior ends (yellow arrows), "handle-bar" appearance of clavicles (white arrows) along with dextrocardia. Over-distended stomach is seen on the right side of the abdomen (red arrow)

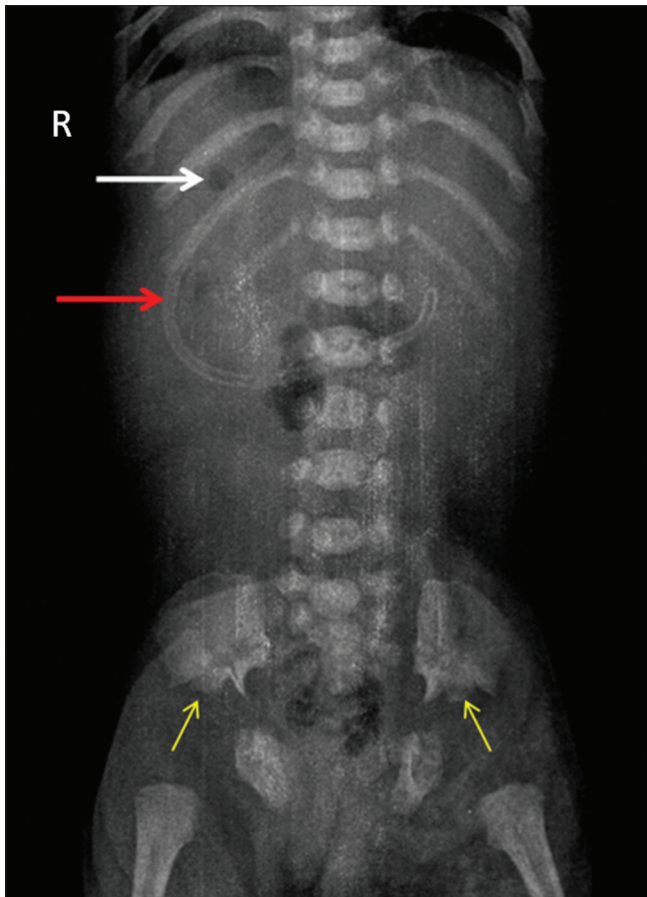


Figure 3: Plain radiograph of the abdomen shows gastric air lucency on the right side of the abdomen (*white arrow*) and the nasogastric tube (*red arrow*) curving along the right side of the abdomen indicating a situs disorder. Short iliac wings with sharp sacro-sciatic notches and “trident” appearance of acetabulae (*yellow arrows*) are seen. There is paucity of large bowel loops in their normal peripheral location

and radiological features.^[3] Patients present with severe respiratory impairment immediately at birth.^[3] The characteristic radiological features are narrow thorax, horizontally oriented ribs having expanded anterior ends, horizontally elevated clavicles (“handle-bar” clavicles), and pelvic changes in the form of short iliac wings, and trident appearance of acetabula.^[2,3] All these radiological features were present in our patient, although respiratory distress was not seen. Atypical cases with absent or minimal respiratory and renal involvement have been sporadically reported in the literature.^[3] Similar atypical presentation of the syndrome was seen in our patient, who primarily presented with symptoms mimicking gastric outlet obstruction, which distracted from the primary diagnosis of JATD.

Barium examination with fluoroscopy remains the preferred radiological modality for functional assessment of the gastrointestinal tract in the pediatric population.^[4] In our patient, malrotation of the stomach and small bowel was seen with delayed gastric emptying

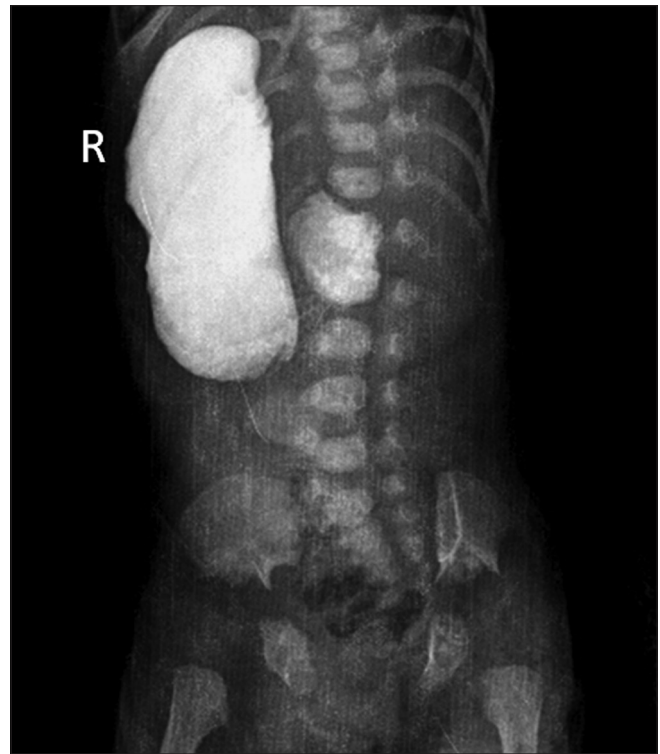


Figure 4: Upper gastrointestinal contrast radiograph obtained at 5 min shows an over-distended stomach located on the right side with a normal pyloric canal

due to a gastric motility disorder. Other modalities for assessment of foregut dysmotility include antro-duodenal manometry, surface electrogastrigraphy, and radionuclide imaging.^[5,6] Antro-duodenal manometry can be performed intra-operatively, as was done in our patient.

In 2015, the Nosology Group of the International Skeletal Dysplasia Society, placed JATD in the short rib dysplasia (with or without polydactyly) category [OMIM: 208500]. However, recent literature on genetic studies has recognized JATD as an autosomal recessive, non-motile ciliopathy with skeletal and multisystem organ involvement.^[7] Organ involvement other than the skeletal system includes renal, gastrointestinal, hepatic, pancreatic, and ocular.^[7] Our patient had skeletal and gastrointestinal involvement in the form of malrotation and motility disorder which is hypothesized to occur secondary to dysfunctional embryonal nodal cilia.^[8] Foregut dysmotility has recently been speculated to be extended spectrum of JATD by Hall *et al.*^[1] Our patient and the one reported by Hall *et al.*^[1] are both cases of JATD with situs anomalies and gastric motility disorder. However, the situs anomalies and gastrointestinal dysmotility were documented more emphatically in our case, both radiologically and by manometric studies.

Antenatal diagnosis of this entity has been reported by Mistry *et al.* and few other investigators, who have

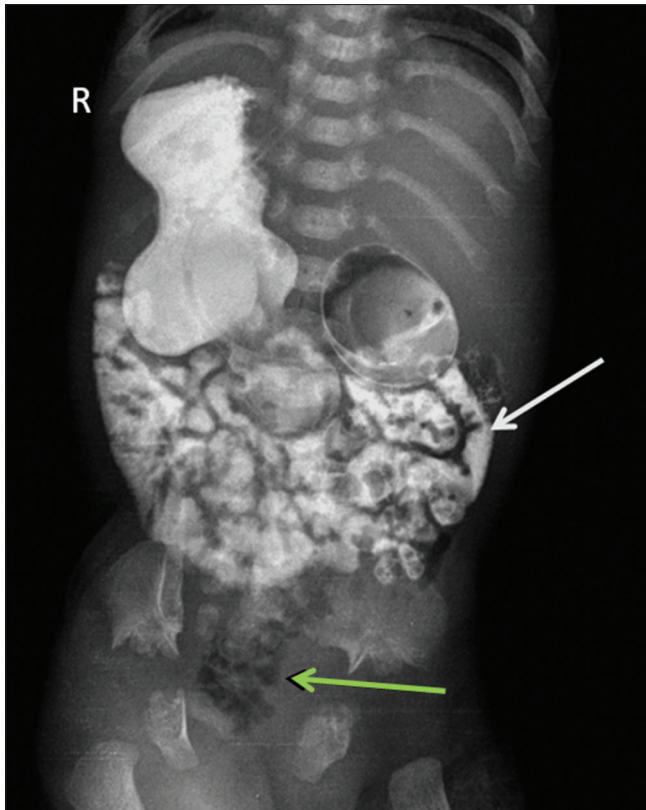


Figure 5: Upper gastrointestinal contrast radiograph obtained at 5 h shows delayed gastric emptying. The duodenal loop (*white arrow*) is seen in a mirror configuration. Opacified jejunal loops are seen on the right side of the abdomen. Air-filled large bowel is seen in the midline of the abdomen (*green arrow*)

documented thoracic hypoplasia and short ribs on antenatal ultrasound scan. The antenatal detection of a short rib anomaly warrants counseling of parents of the inevitable, recurrent respiratory complications and poor prognosis despite recent surgical treatment options.^[2] The recurrence risk of this autosomal recessive condition in future offspring should be explained to the parents, who should also be advised genetic evaluation.

The differential diagnosis of Jeune's syndrome (JATD) in the antenatal and postnatal period includes other short-rib dysplasias, namely Ellis-van Creveld syndrome, and short rib-polydactyly syndrome. Other differential diagnosis of JATD includes cranio-ectodermal dysplasia and nephronophthisis. Ellis-van Creveld syndrome is characterized by finger nail dysplasia, polydactyly and heart defects. These features were conspicuous by their absence in our patient. Absence of polydactyly further excluded short-rib polydactyly syndrome. Cranio-ectodermal dysplasia is a ciliopathy with skeletal involvement along with the presence of characteristic facial and ectodermal features. There was no cranio-facial involvement in our patient excluding cranio-ectodermal dysplasia.

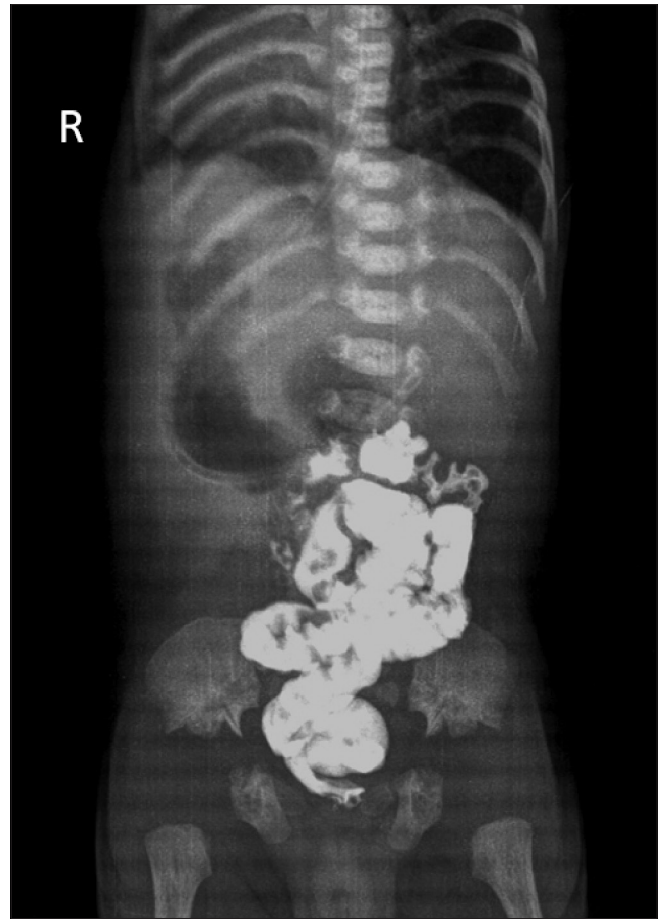


Figure 6: Delayed radiograph obtained 24 h after contrast administration shows large bowel loops appear to be located entirely in the midline of the abdomen

Nephronophthisis was excluded as there was no renal involvement in our patient.^[2,6]

To the best of author's knowledge, this is the second case report with an extremely rare manifestation of JATD as gastric motility disorder with a coexistent situs inversus totalis. A high index of clinical suspicion and a vigilant radiologist are both vital for an accurate diagnosis and successful management of these patients.

Declaration of patient consent

The authors certify that they have obtained all appropriate patient consent forms. In the form the patient(s) has/have given his/her/their consent for his/her/their images and other clinical information to be reported in the journal. The patients understand that their names and initials will not be published and due efforts will be made to conceal their identity, but anonymity cannot be guaranteed.

Financial support and sponsorship

Nil.

Conflicts of interest

There are no conflicts of interest.

References

1. Hall T, Bush A, Fell J, Offiah A, Smith V, Abel R. Ciliopathy spectrum expanded? Jeune syndrome associated with foregut dysmotility and malrotation. *PediatrPulmonol*2009;44:198-201.
2. Mistry KA, Suthar PP, Bhesania SR, Patel A. Antenatal diagnosis of Jeune syndrome (asphyxiating thoracic dysplasia) with micromelia and facial dysmorphism on second-trimester ultrasound. *Pol J Radiol* 2015;80:296-9.
3. DeVries J, Yntema JL, van Die CE, Crama N, Cornelissen EA, Hamel BC. Jeune syndrome: Description of 13 cases and a proposal for follow-up protocol. *Eur J Pediatr* 2010;169:77-88.
4. Lim-Dunham JE, Gore RM. Diseases of the pediatric stomach and duodenum. In: Gore RM, Levine MS. 4th ed, Vol 2. *Textbook of Gastrointestinal Radiology*. Philadelphia: WB Saunders; 2015. p. 2141-57.
5. Venkatasubramani N, Sood MR. Motility disorders of the gastrointestinal tract. *Indian J Pediatr* 2006;73:927-30.
6. Chumpitazi B, Nurko S. Pediatric Gastrointestinal Motility Disorders: Challenges and Clinical Update. *Gastroenterology & Hepatology* 2008;4:141-48.
7. Bonafe L, Cormier-Daire V, Hall C, Lachman R, Mortier G, Mundlos S, *et al.* Nosology and classification of genetic skeletal disorders: 2015 Revision. *Am J Med Genet A*2015;167A: 2869-92.
8. Tobin JL, Beales PL. The non-motile ciliopathies. *Genet Med* 2009;11:386-402.