

Venous reflux into renal and spinal veins on MDCT in a surviving patient

Sumana Bingi, Sahaja Kanugula, Swarupa Keerthipati, Kalyani Bankupalli, Balakrishna Gowdu Thimmoji¹, Rajanikanth Rao Vedula

Departments of Radiodiagnosis and ¹Medicine, Great Eastern Medical School and Hospital, Srikakulam, Andhra Pradesh, India

Correspondence: Dr. Rajanikanth Rao Vedula, Department of Radiodiagnosis, Great Eastern Medical School, Srikakulam - 532 001, Andhra Pradesh, India. E-mail: vedula@gmail.com

Abstract

In patients of cardiac arrest or near death, opacification of inferior vena cava and renal veins during the arterial phase of intravenous contrast administration at computed tomography (CT) examination is well known. We present a case of extensive reflux into renal and spinal veins in a patient who survived for 1 week following multidetector computed tomography (MDCT) examination without any life supporting devices.

Key words: Cardiac arrest; computed tomography; contrast pooling; CT contrast media

Introduction

Following intravenous contrast injection during a multidetector computed tomography (MDCT) examination of stable patients, triphasic timeline technique is performed routinely. Accordingly, the early arterial phase demonstrates arterial tree of the desired area, based on the placement of the bolus tracking region of interest. However, in patients with cardiac arrest or impending cardiac failure, opacification of hepatic veins and layering of contrast medium in the inferior vena cava and renal veins has been described in the literature. We present a case of hemodynamically stable patient in whom extensive reflux of contrast medium into the hepatic, renal, and spinal veins was observed in addition to a densely opacified inferior vena cava.

Case Report

An 80-year-old female patient presented with signs and symptoms of acute left ventricular dysfunction and severe

pulmonary edema 1 month ago which was managed by mechanical ventilation and decongestant therapy and discharged from the hospital after full recovery. She returned to emergency room with history of pain in the left iliac fossa and burning micturition for 1 week, vomiting and watery stools since 4 days, and shortness of breath since 1 day. There was no history of hypertension or diabetes. On examination, patient was conscious and breathless (NYHA class IV). Pitting edema of both lower limbs was noted. Her blood pressure was 130/80 mm Hg. She had tachypnea (97/mnt) and breathing at a rate of 29/min. Basal crepitations and pansystolic murmur were appreciated on auscultation. ECG showed V1 to V5 ST segment elevation. Chest radiography revealed cardiomegaly. Echocardiography demonstrated diameters of aorta and left atrium 33 and 40 mm, respectively. Left ventricular end diastolic diameter was 54 mm and end systolic diameter was 38 mm. Posterior wall measured 9 mm with an ejection fraction of 20%. Pressure in the right ventricle was 36

Access this article online

Quick Response Code:



Website:
www.ijri.org

DOI:
10.4103/ijri.IJRI_353_18

This is an open access journal, and articles are distributed under the terms of the Creative Commons Attribution-NonCommercial-ShareAlike 4.0 License, which allows others to remix, tweak, and build upon the work non-commercially, as long as appropriate credit is given and the new creations are licensed under the identical terms.

For reprints contact: reprints@medknow.com

Cite this article as: Bingi S, Kanugula S, Keerthipati S, Bankupalli K, Gowdu Thimmoji B, Vedula RR. Venous reflux into renal and spinal veins on MDCT in a surviving patient. Indian J Radiol Imaging 2019;29:223-5.

mm Hg. Dilated left ventricle with akinesia of distal septum, apex, and apicolateral segment were noted. Moderate mitral, aortic, tricuspid, and pulmonary regurgitation were observed. Both atria did not show any abnormality. Her oxygen saturation, serum electrolytes, and arterial blood gases were noncontributory. Diagnosis of severe left ventricular dysfunction associated with pulmonary edema was considered. Ultrasonography of abdomen revealed prominent inferior vena cava and peripherally calcified round mass lesion in left suprarenal region. Pleural effusion was noted on both sides. After obtaining informed consent, contrast enhanced CT Scan (GE Revolution 16 slice) was performed using nonionic iodinated contrast medium (Omnipaque 350 mgI/ml) at a rate of 4 ml/s into the right femoral vein because of unavailable veins in the upper extremities. Severe reflux of contrast medium was noted into the hepatic, renal, and spinal veins while right atrium and inferior vena cava were opacified densely, indicating severely raised pressure in the right atrium [Figures 1 and 2]. Her vital conditions were stable during and immediately after the CT scanning. She was treated by diuretics, bronchodilator nebulization therapy and broad spectrum antibiotics for 1 week. Inotropes were not used during the treatment. Her breathlessness gradually improved and was free of symptoms at the time of discharge from the hospital on the 6th day of admission. At home, the patient suddenly became unconsciousness and succumbed.

Discussion

Velocity of flow of fluid particles (blood) in concentric laminae varies progressively from zero to maximal near

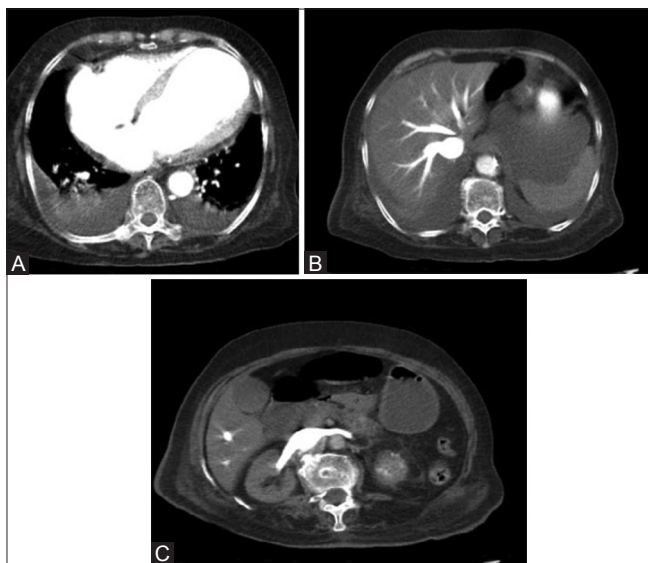


Figure 1 (A-C): (A) Contrast enhanced CT of abdomen. Most cranial axial section demonstrates uniformly enhancing cardiac chambers. (B) Axial image shows densely filled hepatic segment of inferior vena cava. Branching hepatic veins are also seen due to retrograde reflux. (C) Axial view demonstrates significant reflux into both renal veins from the inferior vena cava

to the wall in the axial stream without mixing in the lumen. From Reynolds's formula, it is assumed that all venous flow is laminar unlike in a turbulent flow where thorough mixing occurs.^[1-3] During contrast-enhanced MDCT examination for routine indications, triphasic bolus tracking technique is performed to demonstrate arterial tree effectively in the early arterial phase. It is widely known that severely increased right ventricular pressure and acute right heart failure impede the forward flow of contrast medium, resulting in reflux into inferior vena cava, the path of least resistance. Intense enhancement of abdominal veins is accompanied by faint opacification of abdominal aorta and arteries. In hemodynamically stable patients, even mixing of cardiac output does not affect the differential specific gravities of blood and injected contrast medium at the clinical rate of delivery. In the event of severely impaired cardiac function with cessation of cardiac pulsations and electrical activity, layering and stagnation of contrast medium in the dependent portion of inferior vena cava and abdominal veins are observed.^[4,5] Besides the inferior vena cava, hepatic veins and renal veins are also visualized densely. Reflux into the portal, lumbar, and iliac veins is also described.^[6,7] Cardiogenic shock following acute myocardial infarction and acute dissection of aorta were described to result in dependent venous contrast pooling and hypostasis in two different patients who were alive during the CT examination and died within hours.^[8] Dependent contrast pooling has been recognized as a sign of cardiac arrest.^[9,10] Constrictive pericarditis and ischemic cardiomyopathy also may result in acute cardiac failure causing venous contrast pooling on CT examination. Route of injection via the femoral vein is not a contributory factor for the gross reflux observed in our patient as venography through femoral vein for many other indications does not result in retrograde flow into the tributaries. Even a direct selective catheter delivery of contrast medium into renal vein ostium against the antegrade flow does not opacify the renal vein. It requires sufficiently high injection pressure to delineate the main renal vein. Also vena cavography does

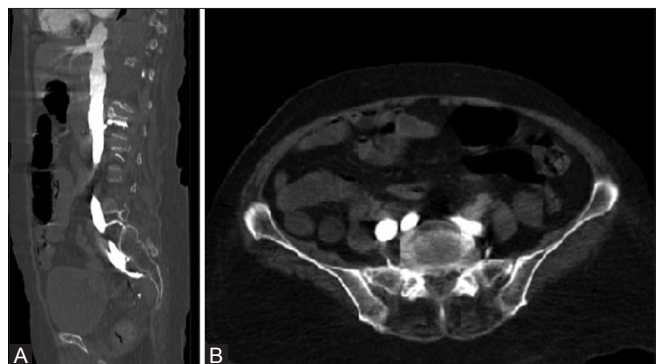


Figure 2 (A and B): (A) CT scan of abdomen with contrast enhancement. A. Sagittal reformatted image demonstrates severe reflux into inferior vena cava, iliac and epidural veins. Regurgitation into renal veins is appreciated. (B) Axial view shows reflux into iliac and epidural veins on both sides

not show the spinal veins. Even in the case of venacaval obstruction, injected contrast medium finds the antegrade direction through collateral pathways, but not towards end organs such as kidneys or spinal cord. According to the reviewed literature, this phenomenon is observed during terminal event such as cardiac arrest or acute heart failure just before death, but not in patients with stable vital parameters as in our patient who lived for a week following the examination.

Conclusion

The patient described here had stable vital signs during the CT scanning and for the next 7 days. Reflux of contrast medium into the inferior vena cava, hepatic, renal, and lumbar epidural veins otherwise observed on MDCT examination in patients with cardiac arrest or acute right heart failure as a terminal event is described in this surviving patient, a novel feature not described in the literature.

Declaration of patient consent

The authors certify that they have obtained all appropriate patient consent forms. In the form the patient(s) has/have given his/her/their consent for his/her/their images and other clinical information to be reported in the journal. The patients understand that their names and initials will not be published and due efforts will be made to conceal their identity, but anonymity cannot be guaranteed.

Financial support and sponsorship

Nil.

Conflicts of interest

There are no conflicts of interest.

References

1. Reynolds O An experimental investigation of the circumstances which determine whether the motion of water shall be direct or sinuous, and of the law of resistance in parallel channels. *Phil Trans* 1883;174:935-82.
2. Burton AC. Laws of physics and flow in blood vessels. In: Wolstenholme GEW. editors. *Visceral Circulation*. London: Churchill; 1952. p. 70-84.
3. Green HD. Circulation: physical principles. In: Glasser O. editors. *Medical Physics*. Chicago: Year Book Publishers; 1994.
4. Sami KA, Alaaddin N, Osman T, Emine U, Ozbek S. Cardiac arrest during computed tomography scanning: Imaging findings. *J Radiol Radiat Ther* 2013;1:1018-9.
5. Clark TJ, Suby-Long T. Computed tomography of acute heart failure: A novel case and literature review. *Radiol Case Rep* 2015;10:1065. DOI: 10.2484/rcr.v10i1.1065.
6. Singh AK, Gervais D, Mueller P, Shirkhoda A, Sagar P, McCarroll K (2004) Cardiac arrest: abdominal CT imaging features. *Abdominal Imaging*. 29:177-9. doi: 10.1007/s00261-003-0120-0. PubMed [PubMed]
7. Jana M, Gamanagatti SR, Kumar A. Case series: CT scan in cardiac arrest and imminent cardiogenic shock. *Indian J Radiol Imaging* 2010;20:150-3.
8. Roth C, Sneider M, Bogot N, Todd M, Cronin P. Dependent venous contrast pooling and layering: A sign of imminent cardiogenic shock. *AJR Am J Roentgenol* 2006;186:1116-9.
9. Tsai PP, Chen JH, Huang JL, Shen WC. Dependent pooling: A contrast-enhanced sign of cardiac arrest during CT. *AJR Am J Roentgenol* 2002;178:1095-
10. Ko SF, Ng SH, Chen MC, Lee TY, Huang CC, Wan YL. Sudden cardiac arrest during computed tomography examination: Clinical findings and "dense abdominal veins" on computed tomography. *J Comput Assist Tomogr* 2003;27:93-7.