

Characteristic changes of the ablation zone on contrast-enhanced computed tomography after radiofrequency ablation of hepatic metastases

Markus Zimmermann, Christiane Kuhl, Sebastian Keil

Department of Diagnostic and Interventional Radiology, University Hospital RWTH, Aachen, Germany

Correspondence: Dr. Markus Zimmermann, Department of Diagnostic and Interventional Radiology, University Hospital RWTH, Aachen, Germany. E-mail: mzimmermann@ukaachen.de

Abstract

Purpose: Size and density measurements of the ablation zones on contrast-enhanced computed tomography (CT) after radiofrequency ablation (RFA) of hepatic metastases of primary breast or colorectal cancer were acquired over time. **Materials and Methods:** Twenty-five liver metastases [colorectal cancer (CRC): $n = 16$; mean size: 19.6 ± 8.5 mm; breast cancer (BC): $n = 9$; 27.9 ± 13.6 mm] in 15 patients (CRC: $n = 11$; age: 65.4 ± 6.5 years; BC: $n = 4$; 62.0 ± 13.8 years) treated by RFA were included in this retrospective study. All patients had undergone postinterventional serial follow-up using multidetector CT (MDCT) (1 day/1/4/7/10/14/18/23/>24 months) without evidence of local tumor recurrence during the follow-up. The ablation zones were evaluated using a commercial software tool (Syngo CT Oncology) in order to determine volumetric, RECIST-, WHO- and density changes over the course of time. Results were compared by applying repeated measures analysis of variance and displayed graphically. **Results:** The RF ablation zones demonstrated significant shrinkage ($P \leq 0.05$) over the first 7 months (volume, RECIST, WHO) of the follow-up. Follow-up after 7 months did not show any significant changes in size ($P > 0.05$) (mean volume (ml): 55.2/34.7/26.3/16.5/12.7/10.0/8.9/8.1/7.5; RECIST (mm): 58.7/49.3/43.7/37.8/34.2/31.3/29.1/27.3/24.8; WHO (mm²): 2458.3/1769.3/1341.8/1027.1/870.1/720.2/649.0/570.4/511.3). Mean density values decreased significantly between 1 day (58.9 HU) and 1 month (47.5 HU) after the procedure. **Conclusion:** Typical changes in size and density values of RF-induced, recurrence-free ablation zones after RFA of hepatic metastases of colorectal and breast cancer were acquired, showing a significant decrease in density of the ablation zone within the first month and significant shrinkage within the first 7 months after RFA.

Key words: Ablation zone; automated evaluation; hepatic metastases; radiofrequency ablation

Introduction

Colorectal cancer (CRC) and breast cancer (BC) are two of the three most common types of cancer in Europe^[1] and frequently metastasize to the liver.^[2-4] Radiofrequency

ablation (RFA) is a viable, minimally invasive treatment alternative to surgical resection in the treatment of hepatic metastases of CRC and BC.^[4-7] However, long-term follow-up examinations are necessary to monitor changes in the ablation

This is an open access journal, and articles are distributed under the terms of the Creative Commons Attribution-NonCommercial-ShareAlike 4.0 License, which allows others to remix, tweak, and build upon the work non-commercially, as long as appropriate credit is given and the new creations are licensed under the identical terms.

For reprints contact: reprints@medknow.com

Cite this article as: Zimmermann M, Kuhl C, Keil S. Characteristic changes of the ablation zone on contrast-enhanced computed tomography after radiofrequency ablation of hepatic metastases. Indian J Radiol Imaging 2018;28:320-6.

Access this article online

Quick Response Code:



Website:
www.ijri.org

DOI:
10.4103/ijri.IJRI_391_17

zone, assess treatment efficacy, and detect early signs of local tumor recurrence.^[8] Contrast-enhanced multidetector computed tomography (MDCT) scans at standardized time points after the procedure are usually used for this purpose.^[9]

Successfully ablated hepatic tumors typically appear as a nonenhancing area of low attenuation that gradually decreases in size on postinterventional contrast-enhanced CT studies. Increasing size or changes of the shape of the ablation zone as well as nodular or rim-like areas of contrast enhancement suggest local tumor recurrence.^[10]

To improve the postinterventional assessment of treatment efficacy, software-assisted evaluation tools could be helpful: In a previously published feasibility study, a software tool has been successfully applied to semi-automatically measure density values and volume of the necrotic ablation zones after RFA of hepatic metastases.^[11]

In order to develop an advanced prototype of this software tool for assessment of the ablation zones and early detection of local recurrence after RFA, CT data sets containing typical characteristics of long-term recurrence-free ablation zones are needed as baseline information. So far, these data exist for hepatocellular carcinoma (HCC),^[12] but are not yet available for hepatic metastases.

Thus, the purpose of the present study was to assess the typical volumetric, RECIST-, WHO- and density changes of the recurrence-free ablation zones after RFA of hepatic metastases in patients with primary CRC and BC.

Materials and Methods

Due to the retrospective design of this study, approval for this study was waived by the institutional review board.

Patients [Table 1]

Fifteen patients with a total of 25 hepatic metastases of either primary CRC or BC that were successfully treated by means of RFA were included in this retrospective study. Only patients with metastases of <3 cm were included, as local tumor recurrence and/or insufficient ablation is significantly more

common in metastases larger than 3 cm.^[13] Additionally, none of the patients developed local tumor recurrence in and around the ablation zones during the follow-up period of at least 2 years. Each patient received serial contrast-enhanced CT scans for follow-up according to the standard postablation imaging schedule at our institution:

1 day and subsequently 1/4/7/10/14/18/23/>24 months after treatment by means of RFA.

Radiofrequency ablation procedures

All patients were treated using an expandable, multitined RF-probe (LeVeen, Boston Scientific Corp, Marlborough, MA, USA) in combination with a generator that delivers a variable output between 2 and 200 Watt at a frequency of 461 ± 5 kHz. The diameter of the electrode array was adapted to the size and shape of the hepatic lesion and ranged between 2.0 and 5.0 cm. As per our standard protocol, RFA procedures were performed under general anesthesia with continuous monitoring of ECG, blood pressure, body temperature, and gas exchange.

All ablations were strictly performed under CT guidance and according to the ablation protocol recommended by the manufacturer (LeVeen, Boston Scientific Corp.) The procedure was finished when the tissue impedance exceeded 500Ω ("roll-off"). As recommended by the manufacturer, a second ablation cycle was performed after a 30 s interval until a second "roll-off" was reached.

Before removal of the RF probe, another contrast-enhanced CT was obtained to assess whether the ablation was complete as well as potential complications such as active bleeding. A lack of contrast-enhancement within the ablation zone was considered to represent coagulation necrosis. In case of an incomplete ablation, the RFA probe was repositioned and a second ablation was conducted. Finally, the puncture tract was ablated during removal of the RF probe (track ablation).

Follow-up computed tomography examination

Imaging data were acquired using a 64-slice MDCT (SOMATOM Definition; Siemens Healthcare,

Table 1: Participants' characteristics

Cancer	Colorectal liver metastases (n=16)	Liver metastases of breast cancer (n=9)
Mean age (a)	65.4±6.5	62.0±13.8
Sex (male/female)	7/4	0/4
Size of metastases (RECIST; longest diameter)	19.6±8.5 mm [min: 11.0; max: 41.3]	27.9±13.6 mm [min: 8.3; max: 53.5]
Location of metastases (liver segment)	II/III: n=2 IV: n=2 V: n=1 VI: n=4 VII: n=3 VIII: n=4	II/III: n=2 IV: n=1 VI: n=2 VII: n=1 VIII: n=3

Forchheim, Germany). Triphasic contrast-enhanced CT scans were performed in cranio-caudal direction under inspiratory breath-hold according to the following protocol:

For the arterial phase, the scan delay was adapted on an individual basis using the bolus tracking method; contrast enhancement in the abdominal aorta was monitored with a series of axial low-dose CT images (2 s interval) (threshold: 140 Hounsfield Units (HU)); effective tube current-time product: 20 mAs; tube voltage: 120 kV; reconstruction kernel: Siemens B30f). The arterial phase scan of the abdomen was started 14 s after the threshold level had been reached in each case. The portal venous phase scan was started 45 s after the arterial phase scan.

Software data analysis

The ablation zones were analyzed using a commercially available software tool (Oncology, Syngo MMWP VE 31H, Siemens Healthcare, Forchheim, Germany). Semi-automated measurements were initiated either by drawing an approximate diameter of the lesion or by a mouse click into the ablation zone for smaller lesions, either in axial, coronal, or sagittal view. Software results were represented graphically to the user [Figure 1]. The following parameters of each ablation zone were measured by the software:

- Volume
- RECIST diameter (longest axial diameter)
- Longest orthogonal diameter to RECIST
- WHO area (Product of RECIST and its longest orthogonal diameter)
- Maximum three-dimensional diameter
- Mean density (HU) including the standard deviation.

All measurements were made based on the images of the portal venous phase and were visually reviewed by

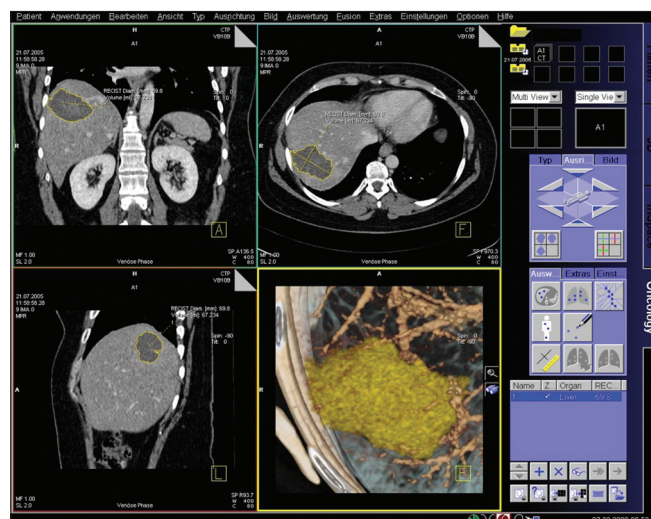


Figure 1: Computer-aided design software screenshot. Screenshot applying the oncology software tool to a patient with a hepatic metastasis of BC treated by RFA (4 weeks post-RFA)

an experienced radiologist (>4 years of experience in abdominal radiology) to ensure the appropriateness of the measurements. Manual editing of the measurements would have been possible, but was not allowed in our study.

Statistics

Results of each investigated parameter (volume, RECIST, WHO, density) were summarized by arithmetic mean and corresponding standard deviation as well as minimum and maximum values. Additionally, the arithmetic mean of each parameter during each time point during follow-up was compared with the initial values at postinterventional day 1 and expressed as a percentage.

Finally, repeated-measures analysis of variance was conducted in order to investigate whether the differences in size and density values of the RFA ablation zones over the time course of the follow-up were statistically significant. For this purpose, the mean values of each parameter at each time point during the follow-up were compared with the immediately preceding study using *post hoc t*-tests. The pre-chosen significance level was $\alpha = 5\%$; thus *P* values of ≤ 0.05 were considered to be statistically significant.

All statistical analyses were performed using the SAS statistical analysis software package (SAS Version 9.1.3, Service Pack 4; SAS Institute, Cary, NC, USA) and diagrams were created using R statistical software (www.R-project.org).

Results

The software correctly segmented all hepatic metastases before and all ablation zones after RFA without the need for any manual correction. Mean values (\pm standard deviation) of the initial hepatic metastases before RFA were as follows:

- Volume [ml]: 6.8 ± 11.0 mm; range: 0.1–45.8 mm
- RECIST [mm]: 22.6 ± 11.1 mm; range: 8.3–53.5 mm
- WHO [mm²]: 454.9 ± 452.1 mm²; range: 34.8–1701.2 mm²
- Density [HU]: 17.7 ± 12.6 HU; range: 7.0–75.0 HU.

Tables 2–5 summarize the results for each parameter at each point in time over the course of the follow-up. Figure 2 displays mean values and standard deviation for volume, RECIST, WHO, and density values over time. A typical course of the changes to the ablation zone on MDCT follow-up is depicted in Figure 3.

The ablation zones shrank significantly ($P \leq 0.05$ for volume, RECIST, and WHO) between the follow-up MDCT studies 1 day, 4 weeks, 4 months, and 7 months after treatment. Beyond the first 7 months, however, the size of the ablation zones did not change significantly over the further course of the follow-up ($P > 0.05$ for comparison of size of the ablation zone at 7 and 10 months after treatment,

Table 2: Volumetric changes (ml) of the 25 ablation zones over time

	1 d	1 mo	4 mo	7 mo	10 mo	14 mo	18 mo	23 mo	>24 mo
Mean±SD	55.2±40.5	34.7±29.0	26.3±25.7	16.5±14.1	12.7±12.6	10.0±10.7	8.9±9.9	8.1±9.3	7.5±8.7
Minimum	12.0	3.7	2.1	1.5	1.0	0.2	0.2	0.1	0.1
Maximum	155.0	131.3	121.3	51.3	49.0	41.2	41.7	38.7	37.6
<i>P</i> -values for difference of mean and mean of the immediate preceding study (t_{x-1}/t_x) ($\alpha=5\%$)		<0.0001	0.0002	0.0002	0.5109	0.8518	0.9998	1.0000	1.0000
Percentage of mean on day 1 after treatment ($t_x/t_{1d} \times 100$)		62.9%	47.6%	29.9%	23.0%	18.1%	16.1%	14.7%	13.6%

Table 3: RECIST changes (mm) of the 25 ablation zones over time

	1 d	1 mo	4 mo	7 mo	10 mo	14 mo	18 mo	23 mo	>24 mo
Mean±SD	58.7±16.7	49.3±15.9	43.7±14.4	37.8±12.3	34.2±11.6	31.3±11.3	29.1±12.0	27.3±12.3	24.8±11.7
Minimum	33.7	22.8	20.3	16.7	15.6	8.5	7.7	6.6	5.9
Maximum	95.2	91.6	80.0	56.1	57.2	54.7	53.9	58.9	55.3
<i>P</i> -values for difference of mean and mean of the immediate preceding study (t_{x-1}/t_x) ($\alpha=5\%$)		<0.0001	<0.0001	<0.0001	0.0197	0.2082	0.6513	0.8440	0.5377
Percentage of mean on day 1 after treatment ($t_x/t_{1d} \times 100$)		84.0%	74.4%	64.4%	58.3%	53.3%	49.6%	46.5%	42.2%

Table 4: WHO changes (mm²) of the 25 ablation zones over time

	1 d	1 mo	4 mo	7 mo	10 mo	14 mo	18 mo	23 mo	>24 mo
Mean±SD	2458.3±1509.4	1769.3±1098.7	1341.8±928.6	1027.1±628.8	870.1±582.6	720.2±513.3	649.0±497.1	570.4±445.8	511.3±424.5
Minimum	821.2	360.6	285.4	233.4	155.4	56.1	53.9	50.7	49.7
Maximum	6721.3	5483.6	4471.0	2308.4	2210.1	1888.9	1887.3	1758.9	1846.2
<i>P</i> for difference of mean and mean of the immediate preceding study (t_{x-1}/t_x) ($\alpha=5\%$)		<0.0001	<0.0001	<0.0001	0.1114	0.6055	0.7259	0.8414	1.000
Percentage of mean on day 1 after treatment ($t_x/t_{1d} \times 100$)		72.0%	54.6%	41.8%	35.4%	29.3%	26.4%	23.2%	20.8%

Table 5: Density changes (HU) of the 25 ablation zones over time

	1 d	1 mo	4 mo	7 mo	10 mo	14 mo	18 mo	23 mo	>24 mo
Mean	58.9±9.3	47.5±11.5	45.6±12.1	49.0±13.9	48.2±15.2	48.6±14.1	49.6±19.7	48.0±15.8	48.1±19.5
Minimum	32.0	24.0	19.0	19.0	12.0	24.0	22.0	24.0	22.0
Maximum	80.0	67.0	68.0	73.0	76.0	76.0	104.0	91.0	100.0
<i>P</i> for difference of mean and mean of the immediate preceding study (t_{x-1}/t_x) ($\alpha=5\%$)		<0.001	0.9159	0.2243	0.9988	1.000	0.9994	0.9884	0.9994
Percentage of mean on day 1 after treatment ($t_x/t_{1d} \times 100$)		80.6%	77.4%	83.2%	81.8%	82.5%	85.5%	81.5%	81.7%

10/14, 18/23, 23/>24 months). The mean density values significantly decreased between postinterventional day 1 and 4 weeks after RFA, while over the further course of the follow-up, the mean density values did not change significantly.

Discussion

RFA is commonly used for treatment of primary malignant liver tumors as well as metastatic liver disease.^[14-19] Obvious advantages of this interventional procedure compared to surgical resection are its minimal invasiveness and low rates of complications.^[20] Additionally, it may be applied in patients who either refuse or are ineligible for open surgery.

Although the rates of local tumor control are high,^[9] long-time follow-up imaging is needed to detect possible local tumor recurrence.^[6] For this purpose, several imaging modalities can be employed, i.e., contrast-enhanced CT, positron emission tomography (PET)/CT, or magnetic resonance imaging (MRI). Although PET/CT and MRI yield a higher sensitivity for local tumor recurrence than contrast-enhanced CT, both of these modalities are more time-consuming, associated with higher costs, and not as widely available as contrast-enhanced CT.^[21,22] Hence, contrast-enhanced CT is still widely used for post-RFA follow-up imaging.^[10]

To improve the sometimes time-consuming procedure of evaluation of the ablation zone on a follow-up CT, a dedicated software tool would be desirable.

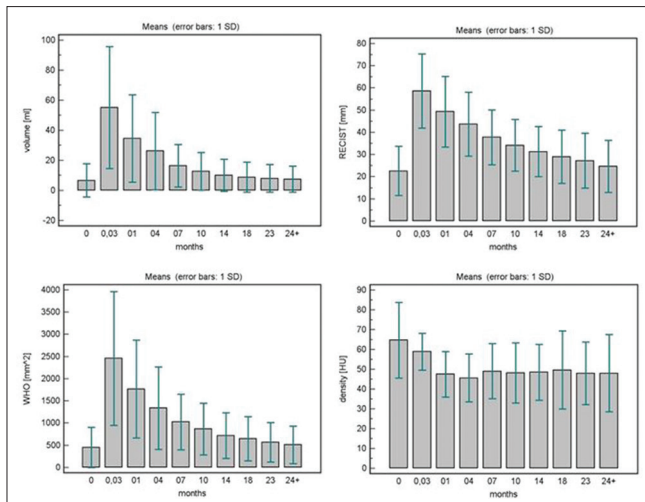


Figure 2: Results. Mean volume, RECIST, WHO, and density values \pm standard deviation (ml) of the 25 hepatic metastases and the ablation zones over the course of time (0 = metastases pretreatment; 0.03 = day 1 after treatment)

Advantages of software-assisted assessment of ablation zones include the ease of volumetric quantification, which allows for a more accurate assessment of lesion changes compared to uni- and bidimensional measurements,^[23] time optimization,^[24] and decreased inter- and intraobserver variability^[25] compared to manual assessment. In addition, a computer-aided design software might be able to detect subtle changes indicating local tumor recurrence within the ablation zone easier and/or earlier than a human person. Parameters indicating local tumor recurrence include a nodular increase in density or an (asymmetrical) increase in size of the ablation zone.^[23,26]

Studies regarding software-assisted measurements of the ablation zone after RFA in comparison to manual measurements have been published previously^[11] and demonstrated the operational reliability of such a software. To develop a software that can additionally automatically assess the ablation zone and aid in detecting potential recurrent disease after RFA, data of the typical short- and long-term changes of hepatic ablation areas after RFA on contrast-enhanced CT are necessary as baseline data.

For a similar purpose, the long-term changes of the hepatic ablation zone after RFA in patients with HCCs have been published before.^[12] However, there are several notable differences between RFA in patients with HCC compared to patients with hepatic metastases that might influence the appearance and changes of the postinterventional ablation zone.

HCCs often arise in cirrhotic livers, while hepatic metastases often occur in formerly healthy liver parenchyma. One could expect that the shrinkage of the ablation zone proceeds more slowly over time in a cirrhotic liver

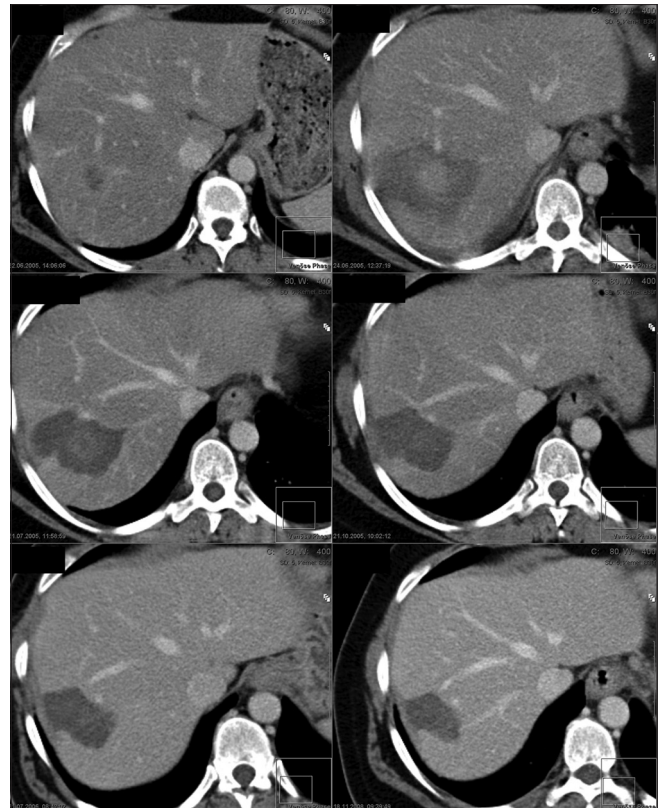

Figure 3: Sample case. Axial CT scan before and 1 day/4 weeks/4/7/14/>24 months after RFA of the same lesion illustrated in Figure 1. Typical peripheral rim of enhancement and a central area of high attenuation on the CT scan 1 day post-RFA followed by continuous shrinkage and decreasing density of the ablation zone

compared to the shrinkage of the ablation zone in patients with noncirrhotic livers. Secondly, HCCs are typically hypervascular lesions while metastases of CRC and BC are mostly hypovascular. And finally, a pseudo-capsule often surrounds hepatocellular carcinomas, while hepatic metastases often demonstrate diffuse growth.

Despite the abovementioned potential differences, the results of the present study were quite similar to a previously published study regarding the changes to the ablation zone in patients with HCCs.

The mean shrinkage of the ablation zone (volume) in relation to the index ablation zone on day 1 after treatment was 62.9% (1 month), 47.6% (4 months), 23.0% (10 months), and 16.1% (18 months), while Lim *et al.* reported quite similar results for HCC (79, 50, 27 and 6% shrinkage).^[12] However, Lim *et al.* also found that 24 of their 43 (56%) investigated lesions showed no considerable changes in size of the ablation zone on follow-up CT examinations. A possible explanation could be that lesion morphology (hypervascular vs. hypovascular, pseudo-capsule vs. diffuse growth) has no significant influence on the ablation zone, while cirrhotic liver parenchyma might hinder scarring and thus shrinkage of the ablation zone.

The spectrum of CT findings after RFA of hepatic tumors has also been investigated by Park *et al.*,^[10] who described areas of increased attenuation in the center of the necrotic ablation area – induced by greater cellular disruption – and a uniform peripheral rim of enhancement as typical findings on the initial postinterventional CT. During further follow-up, these findings were usually completely resolved within the first month after RFA. These observations are similar to the findings in the present study, which demonstrated a significant decrease in density of the ablation zone between day 1 and 1-month post-RFA and stable density values over the course of the further follow-up.

The main limitation of this study is the limited sample size. However, the results of our study are in line with previously published studies.^[12,13] Additionally, small local tumor recurrence may not be apparent on contrast-enhanced CT and may require other imaging modalities such as MRI for detection of recurrent disease.

As an alternative to RFA, microwave ablation is a technique that also produces tissue-heating effects and the resulting ablation zones look quite similar to those after RFA. However, microwave ablation has been shown to lead to more tissue contraction during the ablation procedure,^[27] hence the results of this study should not be blindly applied to post microwave ablation zones.

Conclusion

In summary, we conclude that typical changes of a recurrence-free ablation zone after successful RFA of hepatic metastases of breast or colorectal origin include a significant decrease in density values within the ablation zone within the first month after RFA and a gradual shrinkage of the typically well-defined ablation zone that occurs primarily during the first 7 months after treatment.

These specific findings are in line with previously published results after RFA of HCCs^[12] and could be used as baseline data for the development of a dedicated software tool for automatic assessment of the ablation zone and aid in early detection of local tumor recurrence.

Financial support and sponsorship

Nil.

Conflicts of interest

There are no conflicts of interest.

References

- Boyle P, Ferlay J. Cancer incidence and mortality in Europe, 2004. *Ann Oncol* 2005;16:481-8.
- Benson AB 3rd. Epidemiology, disease progression, and economic burden of colorectal cancer. *J Manag Care Pharm* 2007;13:5-18.
- Greenlee RT, Hill-Harmon MB, Murray T, Thun M. Cancer statistics, 2001. *CA Cancer J Clin* 2001;51:15-36.
- Gillams AR, Lees WR. Radio-frequency ablation of colorectal liver metastases in 167 patients. *Eur Radiol* 2004;14:2261-7.
- Jakobs TF, Hoffmann RT, Schrader A, Stemmler HJ, Trumm C, Lubienski A, *et al.* CT-guided radiofrequency ablation in patients with hepatic metastases from breast cancer. *Cardiovasc Intervent Radiol* 2009;32(1):38-46.
- de Baere T, Elias D, Dromain C, Din MG, Kuoch V, Ducreux M, *et al.* Radiofrequency ablation of 100 hepatic metastases with a mean follow-up of more than 1 year. *AJR Am J Roentgenol* 2000;175:1619-25.
- Wood TF, Rose DM, Chung M, Allegra DP, Foshag LJ, Bilchik AJ. Radiofrequency ablation of 231 unresectable hepatic tumors: indications, limitations, and complications. *Ann Surg Oncol* 2000;7:593-600.
- Dromain C, de Baere T, Elias D, Kuoch V, Ducreux M, Boige V, *et al.* Hepatic tumors treated with percutaneous radio-frequency ablation: CT and MR imaging follow-up. *Radiology* 2002;223:255-62.
- Goldberg SN, Grassi CJ, Cardella JF, Charboneau JW, Dodd GD 3rd, Dupuy DE, *et al.* Image-guided tumor ablation: Standardization of terminology and reporting criteria. *Radiology* 2005;235:728-39.
- Park MH, Rhim H, Kim YS, Choi D, Lim HK, Lee WJ. Spectrum of CT findings after radiofrequency ablation of hepatic tumors. *Radiographics* 2008;28:379-90; discussion 390-2.
- Keil S, Bruners P, Ohnsorge L, Plumhans C, Behrendt FF, Stanzel S, *et al.* Semiautomated versus manual evaluation of liver metastases treated by radiofrequency ablation. *J Vasc Interv Radiol* 2010;21:245-51.
- Lim HK, Choi D, Lee WJ, Kim SH, Lee SJ, Jang HJ, *et al.* Hepatocellular carcinoma treated with percutaneous radio-frequency ablation: evaluation with follow-up multiphase helical CT. *Radiology* 2001;221:447-54.
- Mulier S, Ni Y, Jamart J, Ruers T, Marchal G, Michel L. Local recurrence after hepatic radiofrequency coagulation: Multivariate meta-analysis and review of contributing factors. *Ann Surg* 2005;242:158-71.
- Gazelle GS, Goldberg SN, Solbiati L, Livraghi T. Tumor ablation with radio-frequency energy. *Radiology* 2000;217:633-46.
- McGhana JP, Dodd GD 3rd. Radiofrequency ablation of the liver: Current status. *AJR Am J Roentgenol* 2001;176:3-16.
- Goldberg SN, Dupuy DE. Image-guided radiofrequency tumor ablation: Challenges and opportunities—Part I. *J Vasc Interv Radiol* 2001;12:1020-32.
- Dupuy DE, Goldberg SN. Image-guided radiofrequency tumor ablation: Challenges and opportunities—Part II. *J Vasc Interv Radiol* 2001;12:1135-48.
- Goldberg SN, Gazelle SG, Mueller PR. Thermal ablation therapy for focal malignancy: A unified approach to underlying principles, techniques, and diagnostic imaging guidance. *AJR Am J Roentgenol* 2000;174:323-31.
- Livraghi T, Goldberg SN, Lazzaroni S, Meloni F, Ierace T, Solbiati L, *et al.* Hepatocellular carcinoma: Radio-frequency ablation of medium and large lesions. *Radiology* 2000;214:761-8.
- Buscarini E, Buscarini L. Radiofrequency thermal ablation with expandable needle of focal liver malignancies: Complication report. *Eur Radiol* 2004;14:31-7.
- Kuehl H, Antoch G, Stergar H, Veit-Haibach P, Rosenbaum-Krumme S, Vogt F, *et al.* Comparison of FDG-PET, PET/CT and MRI for follow-up of colorectal liver metastases treated with radiofrequency ablation: Initial results. *Eur J Radiol*. 2008 Aug; 67 (2):362-71.
- Samim B, Molenaar IQ, Seesing MF, van Rossum PS, van den Bosch MA, Ruers TJ, *et al.* The diagnostic performance

- of 18F-FDG PET/CT, CT and MRI in the treatment evaluation of ablation therapy for colorectal liver metastases: A systematic review and meta-analysis. *Surg Oncol* 2017;26:37-45.
23. Heussel CP, Meier S, Wittelsberger S, Götte H, Mildenerger P, Kauczor HU. Follow-up CT measurement of liver malignoma according to RECIST and WHO vs. volumetry. *Fortschr Röntgenstr* 2007;179:958-64.
 24. Fabel M, von Tengg-Kobligk H, Giesel FL, Bornemann L, Dicken V, Kopp-Schneider A, *et al.* Semi-automated volumetric analysis of lymph node metastases in patients with malignant melanoma stage III/IV—a feasibility study. *Eur Radiol* 2008;18:1114-22.
 25. Wormanns D, Kohl G, Klotz E, Marheine A, Beyer F, Heindel W, *et al.* Volumetric measurements of pulmonary nodules at multi-row detector CT: *In vivo* reproducibility. *Eur Radiol* 2004;14:86-92.
 26. Ahmed M, Solbiati L, Brace CL, Breen DJ, Callstrom MR, Charboneau JW, *et al.* Image-guided tumor ablation: Standardization of terminology and reporting criteria—a 10-year update. *J Vasc Interv Radiol* 2014;25:1691-705.e4.
 27. Brace CL1, Diaz TA, Hinshaw JL, Lee FT Jr. Tissue contraction caused by radiofrequency and microwave ablation: A laboratory study in liver and lung. *J Vasc Interv Radiol* 2010;21:1280-6.