

Acoustic radiation force impulse elastography of liver as a screening tool for liver fibrosis in alcoholic liver disease

Iranna M Hittalamani, Bhushita B Lakhkar, Ramesh C Pattanashetti, Bhushan N Lakhkar

Department of Radiology, Shri B.M. Patil Medical College, BLDE University, Solapur Road, Vijayapur, Karnataka, India

Correspondence: Dr. Bhushita B Lakhkar, Department of Radiology, Shri B.M. Patil Medical College, BLDE University, Solapur Road, Vijayapur - 586 103, Karnataka, India. E-mail: bhushitalakhkar@gmail.com

Abstract

Context: Acoustic radiation force impulse (ARFI) elastography is a noninvasive and quantitative technique for diagnosis of liver fibrosis. To the best of our knowledge, there are only two studies reported in literature for evaluation of alcoholic liver disease using ARFI. **Aims:** The aim of this study was to evaluate the diagnostic performance of ARFI elastography for assessing liver fibrosis in alcoholic liver disease and compare it with biochemical indices aspartate transaminase-to-platelet ratio index (APRI) and fibrosis-4 Index (FIB-4) using histopathology as the reference standard. **Settings and Design:** Institutional cross-sectional study. **Methods and Materials:** The patients visiting our hospital over a period of 2 years with a high-risk consumption of alcohol (>40 g/day for men and >20 g/day for women for a cumulative period of more than 5 years) were subjected to ARFI elastography of liver, Liver Function Tests (to calculate APRI and FIB-4 indices), and liver biopsy. **Statistical Analysis Used:** Area under the receiver operating characteristic (AUROC) curve analysis, Kruskal–Wallis test for ANOVA. **Results:** A total of 50 patients of chronic alcoholic liver disease were evaluated with ARFI elastography, which performed better than the biochemical indices in distinguishing cirrhosis of the liver ($F = 4$) from the severe fibrosis ($F \geq 3$) with area under the receiver operating characteristic of 0.97, whereas for significant fibrosis ($F \geq 2$) and severe fibrosis ($F \geq 3$), it was comparable to the biochemical indices with AUROC of 0.65 and 0.70. In our study, the median shear wave velocity cutoff values were 1.37 m/s, 1.51 m/s, and 1.87 m/s for $F \geq 2$, $F \geq 3$, and $F = 4$ fibrosis stages, respectively. **Conclusions:** ARFI elastography is a noninvasive, reliable, and repeatable diagnostic test for grading of liver fibrosis. It performs better than the biochemical indices to differentiate severe fibrosis and cirrhosis of liver.

Key words: Acoustic radiation force impulse elastography; alcoholic liver disease; shear wave velocity, fibrosis stages

Introduction

Alcoholic liver disease in India is rampant with a prevalence of 5% of the total population and liver cirrhosis mortality rate is as high as 63% according to recent data published by the

WHO in 2014.^[1] Chronic liver diseases irrespective of etiology lead to hepatic fibrosis; a dynamic process with evidence of regression on early intervention, if neglected architectural distortion and cirrhosis ensues.^[2,3] Thus, noninvasive early

This is an open access journal, and articles are distributed under the terms of the Creative Commons Attribution-NonCommercial-ShareAlike 4.0 License, which allows others to remix, tweak, and build upon the work non-commercially, as long as appropriate credit is given and the new creations are licensed under the identical terms.

For reprints contact: reprints@medknow.com

Cite this article as: Hittalamani IM, Lakhkar BB, Pattanashetti RC, Lakhkar BN. Acoustic radiation force impulse elastography of liver as a screening tool for liver fibrosis in alcoholic liver disease. Indian J Radiol Imaging 2019;29:190-4.

Access this article online

Quick Response Code:



Website:
www.ijri.org

DOI:
10.4103/ijri.IJRI_399_18

diagnosis of liver fibrosis is of paramount importance. Liver biopsy is the gold standard, but is an invasive, painful procedure, with sampling error, interobserver variability, and an error rate of 33%.^[4,5] Elastography is an alternative, quantitative technique for liver fibrosis. ARFI elastography is one of the ultrasound-based elastographic techniques used for grading of liver fibrosis.

Aims and Objectives

This study was conducted with the aim to evaluate the diagnostic performance of ARFI elastography against biochemical indices and liver biopsy and also assess the utility of available shear wave (SW) velocity cutoffs to potentially avoid liver biopsies.

Materials and Methods

Patient selection and description

This institutional cross-sectional study was approved by the institutional ethics committee and an informed written consent was obtained from all the study participants. We evaluated a total of 50 patients who fulfilled the inclusion criteria.

Inclusion criteria

Patients aged more than 18 years old with high-risk alcohol consumption (>40 g/day for men and >20 g/day for women for a cumulative period of more than 5 years)^[6] were included in the study.

Exclusion criteria

Patients with liver trauma, established cases of cirrhosis, a known history of chronic liver diseases of various other etiologies (*viz.*, viral hepatitis, autoimmune hepatitis, extrahepatic cholestasis, hepatic venous congestion, and other liver diseases) and patients in whom liver biopsy was not possible (due to medical conditions) were excluded from the study.

Technique of ARFI elastography

In our study, Acuson S3000 (Siemens Medical Solutions, USA, Inc.) ultrasound machine equipped with ARFI elastography software was used to obtain SW velocities. ARFI elastography was performed using the manufacturer guidelines. The patients were asked to visit with fasting state for 4–6 h. They were trained for resting respiratory position (neither full inspiration nor full expiration) before the elastography examination. ARFI elastography was performed in dorsal decubitus position, with the right arm above the head for adequate intercostal access and breath hold during each measurement. Routine grayscale ultrasonography of liver was performed first, followed by switching over to the elastography mode. In the elastography mode, the region of interest (ROI), which is a box of 0.5 × 1.0 cm, was placed 1.5–2.0 cm

beneath the Glisson's capsule perpendicular to the center of the transducer, avoiding major vessels of the liver. Ten valid measurements were taken in the right lobe of liver. When the interquartile range of the measurements was >0.3 × median SW speed, the measurements were considered unreliable.^[7,8] Median SW velocity of the measured values was displayed on the results screen and used for grading the liver fibrosis.

Biochemical indices

The APRI and FIB-4 indices were calculated based on the age, liver function tests, and platelet counts that were obtained on the same day.

Liver biopsy

Liver biopsy was performed on the same day. All the biopsies were performed under ultrasound guidance after SW measurements and were reported by same pathologist for all patients. The pathologist was also blinded to the ARFI elastography results.

Statistical analysis

All the statistical analyses were performed in SPSS 16.0 software (Statistical Package for Social Science Inc., Chicago, IL, USA). Descriptive statistics, frequency analysis for categorical variables, and mean and standard deviations were obtained for all continuous variables. AUROC curve analysis was done to assess diagnostic performance of each test (*viz.*, ARFI elastography, aspartate transaminase-to-platelet ratio index, and fibrosis-4 indices) separately and the results were compared for each test; Kruskal–Wallis test was performed for analysis of normal variance of the SW velocities and Pearson correlation coefficient was derived to correlate liver biopsy results with the SW elastography results.

Results

Our study population comprised 50 male patients ranging from 24 to 62 years (mean 41 ± 9.81 years) fulfilling the inclusion criteria. We did not come across any female patients. About 44% (*n* = 22) of our patients were clinically asymptomatic with high risk alcohol consumption. About 36% (*n* = 18) of the cases had hepatomegaly with high-risk alcoholism, and 20% (*n* = 10) of the cases had hepatosplenomegaly and ascites and were referred for confirmation of cirrhosis.

The study population on liver biopsy comprised 12 patients of cirrhosis (*F* = 4), 8 patients of severe liver fibrosis (*F* = 3), 7 patients of significant liver fibrosis (*F* = 2), 9 patients of nonsignificant fibrosis (*F* = 1), and 14 without any evidence of fibrosis (*F* = 0).

ARFI elastography positively correlated [Pearson correlation (*r*): +0.76] with liver biopsy results in our

study. The box plots for measured SW velocities in different pathological stages of fibrosis as observed in our study population are depicted in Figure 1.

Optimal SW velocity cutoff values for different stages of liver fibrosis as suggested by Friedrich-Rust *et al.*^[9] were used and 24 patients were classified into $F \leq 1$ (METAVIR) stage, implying either no fibrosis or minimal fibrosis. Nine patients were classified to be of $F \geq 2$ (significant fibrosis), 6 patients as $F \geq 3$ (severe fibrosis), and 11 patients were grouped as $F = 4$ (cirrhotic).

On the basis of APRI scores, 35 patients had no fibrosis, 5 patients had significant fibrosis, and 6 probably had cirrhosis. APRI score was inconclusive in 4 patients. Similarly, FIB-4 scores suggested that 31 patients had no severe fibrosis, 10 patients had severe fibrosis, and in the remaining 9 patients, FIB-4 index was inconclusive.

Highest AUROC was derived for ARFI elastography, followed by FIB-4 index and the APRI index to grade fibrosis. AUROC was highest for the severe fibrosis versus cirrhosis of liver, implying the ability of ARFI elastography to better distinguish between the severe fibrosis versus cirrhosis of liver. The ROC curves for differentiation of $F > 3$ and $F = 4$ stages of liver fibrosis are shown in Figures 2 and 3.

Discussion

Chronic alcoholism causes hepatic steatosis, alcoholic steatohepatitis, and steatofibrosis finally causing cirrhosis. Classically, aspartate transaminase (AST):alanine transaminase (ALT) ratio >1 is a feature of the alcoholic liver cirrhosis that distinguishes it from other chronic liver diseases. APRI (AST-platelet ratio index) and FIB-4 (fibrosis-4) indices are commonly used biochemical

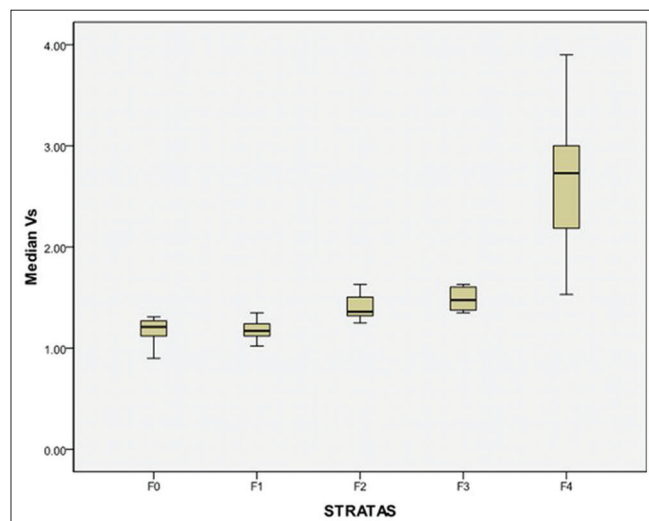


Figure 1: Box Plots of the observed median shear wave velocities

indices to grade and monitor the stages of liver fibrosis. On further advancement, steatofibrosis progresses into alcoholic liver fibrosis.

Role of elastography in alcoholic liver disease

Currently, transient elastography (TE), SW elastography, and ARFI imaging are the three main ultrasound-based elastographic techniques that allow direct and indirect quantification of liver stiffness.^[10] ARFI is a relatively newer elastography technique used for assessment of liver fibrosis. Bota *et al.* in 2013 did a meta-analysis comparing the ARFI elastography against TE with the data available in major research databases. They concluded, "Acoustic radiation force impulse elastography is a good method with higher rate of reliable measurements and similar predictive value to TE for significant fibrosis and cirrhosis."^[11] In other studies conducted by Rizzo *et al.*,^[12] Leung *et al.*,^[13] Doherty *et al.*,^[14] and Jaffer *et al.*,^[15] ARFI elastography had clear advantage over the TE even in patients with ascites. However, Friedrich-Rust *et al.*^[16] and Gerber *et al.*^[17] reported no significant difference in ARFI and TE methods. Hence, ARFI elastography is easily available radiological tool that can be used in conjunction with other biochemical tests and indices as an effective tool for acceptable noninvasive assessment of liver fibrosis.

Friedrich-Rust *et al.* in their pooled meta-analysis of eight studies on ARFI elastography including a total of 518 patients suggested that the optimal cutoff for the diagnosis of significant fibrosis was 1.34 m/s (AUROC = 0.87), 1.55 m/s (AUROC = 0.91) for severe fibrosis, and 1.80 m/s (AUROC = 0.86) for the diagnosis of liver cirrhosis. When these cutoffs were used, we observed that AUROC

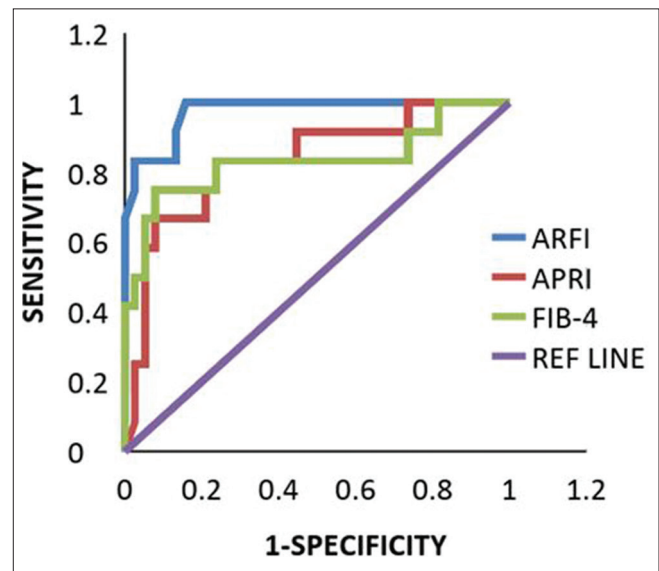


Figure 2: ROC curve using APRI Index (Red Line), ARFI elastography (Blue Line), and FIB-4 index (Green Line) as test curves in diagnosis of Severe Fibrosis and Cirrhosis after applying the cutoff values suggested by F. Rust *et al.*^[9] with pathological outcomes as reference standard

for significant fibrosis was 0.98, for severe fibrosis it was 0.97, and for cirrhosis it was 0.96. When the meta-analysis cutoff values were not applied, there was a clear advantage with an AUROC of 0.97 for the diagnosis of liver cirrhosis. However, in cases of severe fibrosis and significant fibrosis, diagnostic accuracy was comparable to the biochemical tests as seen from our observations [Table 1].^[9]

We have come across very limited literature about ARFI elastography in alcoholic liver diseases, but it has been validated in liver fibrosis of other etiologies, namely, viral hepatic fibrosis, nonalcoholic steatohepatitis, etc., Two studies were available in the literature addressing the use of ARFI elastography in alcoholic liver fibrosis: one by Zhang *et al.* in China (2014) on 112 patients and other by Kiani *et al.* in France (2016) on 83 patients from deaddiction

centers.^[18,19] In our study, we observed the SW velocity cutoffs of 1.37 m/s for significant fibrosis, 1.51 m/s for severe fibrosis, and 1.87 m/s for cirrhosis of liver. The cutoffs from meta-analysis were comparable to our study, whereas the observations of Zhang *et al.* were lower and observations of Kiani *et al.* were higher [Table 2]. The probable reason for this variability in measurements could be because of absence of literature, specifying the depth from the surface at which the measurements are made. The cutoff values of Zhang *et al.*, who have compared the patients with normal ALT levels (1.23 m/s for $F \geq 2$, 1.27 for $F \geq 3$, and 1.41 for $F = 4$) and raised ALT levels (1.33 m/s for $F \geq 2$, 1.40 for $F \geq 3$, and 1.65 for $F = 4$), were still lower than our results. Hence, we also postulate that the variability in cutoffs can be because of the choice of ROI and the depth from the surface for the measurements.

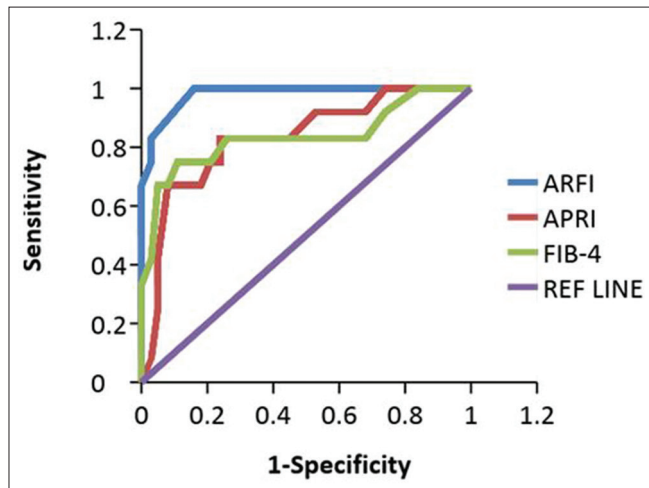


Figure 3: ROC curve using APRI Index (Red Line), ARFI elastography (Blue Line), and FIB-4 index (Green Line) as test curves in diagnosis of Severe Fibrosis and Cirrhosis in our study based on only the pathological outcomes

Advantages of ARFI elastography

We observed that it was possible to measure liver stiffness in obese patients and those with ascites, which is not possible with TE.^[3,20,21] The SW velocities in left lobe of liver were difficult to measure and also were unreliable owing to the cardiac motion degrading the quality of SWs as observed in few other studies.^[22,23]

Disadvantages of ARFI elastography

Ultrasound systems for elastography are manufactured by different manufacturers, and as a result of it, standard values are not available for comparison across different ultrasound systems. In our study, the reliable measurements could be obtained upto a depth of 8 cm, which becomes a hindrance in cases of gross ascites.

Limitations of the study

Our study included a small sample size, which would limit statistical power of the study. The effect of right heart failure and hepatic venous congestion was not considered as none

Table 1: Diagnostic performance of APRI Index vs ARFI Elastography vs FIB-4 Index

Number of Patients (n=50)	Severe Fibrosis vs. Cirrhosis (F=4)			
	APRI	FIB-4	ARFI elastography (using optimal cut-offs)	ARFI elastography (using data obtained in our study)
Sensitivity	0.83	0.83	1.00	0.83
Specificity	0.76	0.74	0.63	0.97
PPV	0.53	0.50	0.92	0.92
NPV	0.94	0.93	0.97	0.97
AUROC	0.83	0.83	0.97	0.97
95% CI	0.651-0.945	0.636-0.934	0.702-0.930	0.810-0.990
P	0.002	0.002	0.001	0.046

Table 2: Comparison of Shear wave velocity cut-offs from available literature

	Present Study	M. Friedrich-Rust <i>et al.</i> ^[9]	D. Zhang <i>et al.</i> ^[18]	Anita Kiani <i>et al.</i> ^[19]
	ARFI cut-off (in m/s) [AUROC]	ARFI cut-off (in m/s) [AUROC]	ARFI cut-off (in m/s) [AUROC]	ARFI cut-off (in m/s) [AUROC]
$F \geq 2$	1.37 [0.65]	1.34 [0.87]	1.27 [0.85]	1.63 [0.87]
$F \geq 3$	1.51 [0.70]	1.55 [0.91]	1.40 [0.88]	1.84 [0.86]
$F = 4$	1.87 [0.97]	1.8 [0.93]	1.65 [0.89]	1.94 [0.89]

of our patients had any known cardiac disease. The effect of ALT levels was not considered in our study, which could potentially affect the choice of cutoff values.

Future directions

A larger cohort of the patients needs to be studied to obtain diagnostic figures. With recent advancements, magnetic resonance elastography has been shown to have promising results; so, ARFI elastography needs to be compared with it and diagnostic accuracy and feasibility need to be studied.

Conclusion

Staging of liver fibrosis helps the patients in a reward system behavior where a patient is committed to detoxification and a regression or reversal of liver fibrosis encourages the patients to further comply with treatment. ARFI elastography has an independent diagnostic ability to perform with AUROC of 0.98 for cirrhosis. The available cutoff values of SW velocities have been well validated in this study with high-diagnostic performance for significant ($F \geq 2$) and severe ($F \geq 3$) fibrosis and cirrhosis as well. Unlike the liver biopsy, ARFI elastography uses a ROI that can be assessed for as many sample areas as possible and for as many repetitions as required noninvasively. It can be performed even in patients with altered coagulation factors. ARFI elastography can be used as a screening tool in asymptomatic patients with suspected liver cirrhosis when biochemical tests reveal an abnormality or altered biochemical indices (e.g. APRI and FIB-4). Thus, ARFI elastography of the liver can significantly reduce the need for liver biopsy.

Financial support and sponsorship

Nil.

Conflicts of interest

There are no conflicts of interest.

References

- World Health Organization. WHO country profile -India. 2010. [online] Available from: http://www.who.int/whosis/whostat/EN_WHS10_Full.pdf?ua=1 [Last accessed on 2017 Oct 02].
- Friedman SL. Hepatic fibrosis-overview. *Toxicology* 2008;254:120-9.
- Barr RG, Ferraioli G, Palmeri ML, Goodman ZD, Garcia-Tsao G, Rubin J, *et al.* Elastography assessment of liver fibrosis: Society of radiologists in ultrasound consensus conference statement. *Radiology* 2015;276:845-61.
- Cadranel JF, Rufat P, Degos F. Practices of liver biopsy in France: Results of a prospective nationwide survey. For the group of epidemiology of the French association for the study of the liver (AFEF). *Hepatology* 2000;32:477-81.
- Afdhal NH, Nunes D. Evaluation of liver fibrosis: A concise review. *Am J Gastroenterol* 2004;99:1160-74.
- Kasper D, Fauci A, Hauser S, Longo D, Jameson J, Loscalzo J. *Harrison's Principles of Internal Medicine*. McGraw Hill Professional; 2015. p. 2052.
- United States of America. Siemens Healthcare White Paper: Best practices for detecting liver fibrosis with ARFI, 2015.
- Ferraioli G, Filice C, Castera L, Choi BI, Sporea I, Wilson SR, *et al.* WFUMB guidelines and recommendations for clinical use of ultrasound elastography: Part 3: Liver. *Ultrasound Med Biol* 2015;41:1161-79.
- Friedrich-Rust M, Nierhoff J, Lupsor M, Sporea I, Fierbinteanu-Braticevici C, Strobel D, *et al.* Performance of acoustic radiation force impulse imaging for the staging of liver fibrosis: A pooled meta-analysis. *J Viral Hepat* 2012;19:212-9.
- Faria SC, Ganesan K, Mwangi I, Shiehmozteza M, Viamonte B, Mazhar S, *et al.* MR imaging of liver fibrosis: Current state of the art. *Radiographics* 2009;29:1615-35.
- Bota S, Herkner H, Sporea I, Salzl P, Sirlir R, Neghina AM, *et al.* Meta-analysis: ARFI elastography versus transient elastography for the evaluation of liver fibrosis. *Liver Int* 2013;33:1138-47.
- Rizzo L, Calvaruso V, Cacopardo B, Alessi N, Attanasio M, Petta S, *et al.* Comparison of transient elastography and acoustic radiation force impulse for non-invasive staging of liver fibrosis in patients with chronic Hepatitis C. *Am J Gastroenterol* 2011;106:2112-20.
- Leung VY, Shen J, Wong VW, Abrigo J, Wong GL, Chim AM, *et al.* Quantitative elastography of liver fibrosis and spleen stiffness in chronic hepatitis B carriers: Comparison of shear-wave elastography and transient elastography with liver biopsy correlation. *Radiology* 2013;269:910-8.
- Doherty J, Trahey G, Nightingale K, Palmeri M. Acoustic radiation force elasticity imaging in diagnostic ultrasound. *IEEE Trans Ultrason Ferroelectr Freq Control* 2013;60:685-701.
- Jaffer OS, Lung PFC, Bosanac D, Patel VM, Ryan SM, Heneghan MA, *et al.* Acoustic radiation force impulse quantification: Repeatability of measurements in selected liver segments and influence of age, body mass index and liver capsule-to-box distance. *Br J Radiol* 2012;85:858-63.
- Friedrich-Rust M, Romen D, Vermehren J, Kriener S, Sadet D, Herrmann E, *et al.* Acoustic radiation force impulse-imaging and transient elastography for non-invasive assessment of liver fibrosis and steatosis in NAFLD. *Eur J Radiol* 2012;81:e325-31.
- Gerber L, Kasper D, Fitting D, Knop V, Vermehren A, Sprinzl K, *et al.* Assessment of liver fibrosis with 2-D shear wave elastography in comparison to transient elastography and acoustic radiation force impulse imaging in patients with chronic liver disease. *Ultrasound Med Biol* 2015;41:2350-9.
- Zhang D, Li P, Chen M, Liu L, Liu Y, Zhao Y, *et al.* Non-invasive assessment of liver fibrosis in patients with alcoholic liver disease using acoustic radiation force impulse elastography. *Abdom Imaging* 2014;40:723-9.
- Kiani A, Brun V, Lainé F, Turlin B, Morcet J, Michalak S, *et al.* Acoustic radiation force impulse imaging for assessing liver fibrosis in alcoholic liver disease. *World J Gastroenterol* 2016;22:4926.
- Tang A, Cloutier G, Szeverenyi NM, Sirlin CB. Ultrasound elastography and MR elastography for assessing liver fibrosis: Part 1, principles and techniques. *Am J Roentgenol* 2015;205:22-32.
- Shiina T, Nightingale KR, Palmeri ML, Hall TJ, Bamber JC, Barr RG, *et al.* Wfumb Guidelines and recommendations for clinical use of ultrasound elastography: Part 1: Basic principles and terminology. *Ultrasound Med Biol* 2015;41:1126-47.
- Samir AE, Dhyani M, Vij A, Bhan AK, Halpern EF, Méndez-Navarro J, *et al.* Shear-wave elastography for the estimation of liver fibrosis in chronic liver disease: Determining accuracy and ideal site for measurement. *Radiology* 2015;274:888-96.
- Toshima T, Shirabe K, Takeishi K, Motomura T, Mano Y, Uchiyama H, *et al.* New method for assessing liver fibrosis based on acoustic radiation force impulse: A special reference to the difference between right and left liver. *J Gastroenterol* 2011;46:705-11.