

## CASE REPORT

# Anti-myelin oligodendrocyte glycoprotein antibody-positive coursing with optic neuritis: Imaging and clinical implications

Nithisha Thatikonda, Juan Gomez<sup>1</sup>, Eduardo Gonazalez Toledo<sup>2</sup>

Medical Student, GMC Nagpur, MUHS, India, <sup>1</sup>Radiology Research Fellow, Louisiana State University Health Science Centre, Shreveport, USA, <sup>2</sup>Department of Radiology, Louisiana State University Health Science Centre, Shreveport, USA

**Correspondence:** Dr. Eduardo Gonzalez Toledo, 1501 Kings Hwy, Shreveport, LA 71103, USA. E-mail: egonz1@lsuhsc.edu

## Abstract

A 9-year-old boy was admitted to our institution with acute onset of bilateral blurry vision. Physical examination revealed bilateral papilledema. Cerebrospinal fluid analysis and comprehensive metabolic panel were normal. Magnetic resonance imaging (MRI) of the brain showed extensive bilateral optic nerve inflammation with post-contrast gadolinium enhancement on T1-weighted sequence. The involvement was limited to the anterior segments of the optic nerves sparing chiasma and optic tracts. Anti-aquaporin-4 antibody (AQP4) was negative while anti-myelin oligodendrocyte glycoprotein antibody (MOG) was positive. After intravenous methylprednisolone, his vision dramatically improved. The patient was discharged with only mildly impaired visual acuity, 2 weeks after admission. Follow-up brain MRI and MOG assay after 3 months were within normal limits.

**Key words:** MRI; myelin oligodendrocyte glycoprotein; optic neuritis

## Introduction

Myelin oligodendrocyte glycoprotein (MOG) is exclusively expressed on the surface of oligodendrocytes and myelin in the central nervous system.<sup>[1]</sup> MOG antibody disease (MOG-AD) is now recognized as a distinct entity characterized by a monophasic or relapsing course of neurological dysfunction, with optic neuritis (ON) as its most common presentation followed by transverse myelitis (TM) and acute disseminated encephalomyelitis (ADEM).<sup>[1-3]</sup> Patients with MOG-IgG associated demyelination appear to have unique clinical, radiological features, and

outcomes compared to other demyelinating conditions, especially AQP4-IgG positive neuromyelitis optica (NMO) and multiple sclerosis (MS).<sup>[3-5]</sup> Hence, the radiological distinction of ON is important.

## Case Report

A 9-year-old African-American boy consulted local optometrist for a 4 days history of acute onset blurring of vision in bilateral eyes associated with pain, more in

This is an open access journal, and articles are distributed under the terms of the Creative Commons Attribution-NonCommercial-ShareAlike 4.0 License, which allows others to remix, tweak, and build upon the work non-commercially, as long as appropriate credit is given and the new creations are licensed under the identical terms.

**For reprints contact:** WKHLRPMedknow\_reprints@wolterskluwer.com

**Cite this article as:** Thatikonda N, Gomez J, Toledo EG. Anti-myelin oligodendrocyte glycoprotein antibody-positive coursing with optic neuritis: Imaging and clinical implications. *Indian J Radiol Imaging* 2020;30:222-4.

**Received:** 07-Dec-2019

**Revised:** 11-Feb-2020

**Accepted:** 05-Mar-2020

**Published:** 13-Jul-2020

### Access this article online

#### Quick Response Code:



**Website:**  
www.ijri.org

**DOI:**  
10.4103/ijri.IJRI\_486\_19

the right eye. It was determined that he had bilateral papilledema. He was then referred to our hospital for further investigation. On examination, his visual acuity was severely impaired (20/200 right eye, 20/100 left eye) with bilateral optic disc edema and no afferent pupillary defect. Routine blood tests and metabolic panel were normal. Erythrocyte sedimentation rate (ESR) was raised to 32 mm/h and C-reactive protein (CRP) was normal. A lumbar puncture was performed, which revealed a cerebrospinal fluid (CSF) cell count of 3 cells/mL, lymphocytes, with normal protein and glucose, and no oligoclonal bands. No lymphocytic pleocytosis was seen.

Brain MRI showed restricted diffusion in bilateral optic nerves on diffusion weighted imaging (DWI) as well as a post-contrast enhancement on T1-weighted sequence indicating extensive bilateral optic nerve inflammation [Figure 1]. MRI spine was unremarkable.

The patient was admitted and started treatment with intravenous methylprednisolone (30 mg/kg/day for 5 days).

Immunologic workup for routine antibodies such as ANA and dsDNA were normal. Indirect immune fluorescence assays using MOG and AQP4 expressing cells revealed positive anti-MOG antibodies (titer 1:40) and negative anti-AQP4 antibodies. Considering the clinical, laboratory, and imaging findings, a diagnosis of anti-MOG associated autoimmune optic neuritis was considered.

Repeat ophthalmological exam after a 5-day course revealed improvement of visual acuity (20/30 in the left eye and 20/20

in right eye) and decreased optic disc swelling. The patient was discharged with continued per oral (PO) steroid dosing with taper after 8 days of hospital stay. The patient was observed subsequently after 2 weeks with visual acuity (20/20 in bilateral eyes). He was further observed for 1 year in outpatient visits and remained asymptomatic. Follow-up brain MRI and anti-MOG IgG assay after 3 months were normal.

## Discussion

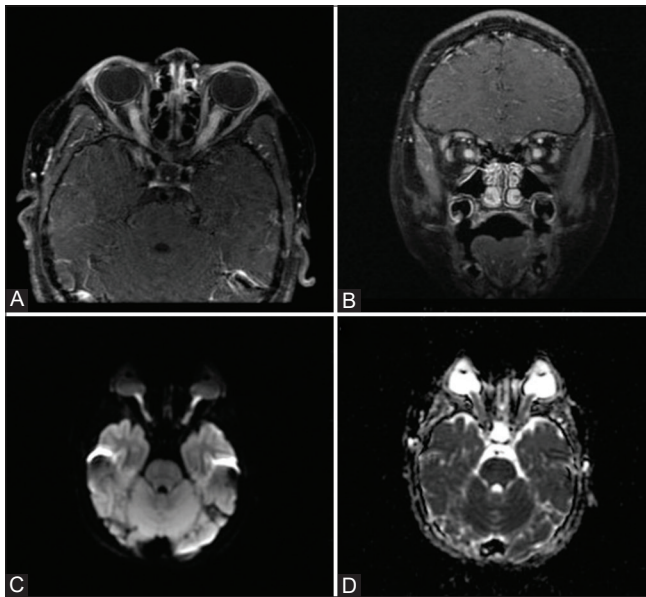
We described a patient with bilateral optic neuritis positive for anti-MOG-IgG. MOG-AD may occur in all decades of life, with a slight predominance in women and with a median age of onset in the mid-thirties. The most common finding was optic neuritis (ON), occurring in 54–61% of patients, followed by TM, or an ADEM-like presentation (e.g., brainstem attack).<sup>[1,2]</sup>

Brain MRI was performed and the images showed extensive post-contrast enhancement of the bilateral optic nerves on the T1-weighted images representing edematous and inflamed bilateral optic nerves. This condition predominantly involved the anterior segments of the optic nerve along with intra-orbital segments, while optic chiasm and optic tracts were spared. Besides, restricted diffusion was found on the DWI sequence and apparent diffusion coefficient (ADC) map.

Bilateral involvement of optic nerves was more common in MOG-ON and AQP4-ON compared to MS-ON<sup>[4]</sup> and according to Sato *et al.*, bilateral involvement of optic nerves was much more common in MOG-ON compared to AQP4-ON.<sup>[2,6]</sup>

In MOG-ON, the T1 gadolinium enhancement predominantly involves the anterior segments of the optic nerves, along with intra-orbital segments with more edematous and extensive inflammation, contrary to AQP4-ON which predominantly affect the chiasma and optic tracts.<sup>[1-5]</sup> This aspect constitutes a vital MRI finding that contributes to making the diagnosis. Akaishi *et al.* studied Japanese patients ( $n = 19$  MOG-ON and  $n = 9$  AQP4-ON) and demonstrated severe and extensive inflammatory changes in the optic nerves of MOG-ON patients that typically spared the chiasm, while AQP4-ON patients had chiasmal swelling.<sup>[7]</sup> A recent cohort of 50 patients presenting with first-episode ON, conducted by Ramanathan *et al.*, has reported chiasma involvement in 64% of patients with AQP4-ON, whereas only 5% of patients with MOG-ON had chiasmal involvement. 15% of MS-ON also had chiasmal involvement but is rarely described and highly variable.<sup>[1,4,8]</sup> Instead, MS-ON is usually unilateral, unpredictable, and occurs in limited segments.<sup>[3,9]</sup>

Besides, patients with MOG-ON and AQP4-ON tend to have longer lesion lengths compared to MS-ON which only involves small segments of the nerves.<sup>[4]</sup> In MOG-ON,



**Figure 1 (A-D):** MRI T1-weighted image showing post-contrast enhancement of extensively edematous bilateral optic nerves in (A) axial and (B) coronal views. Restricted diffusion in bilateral optic nerves on DWI sequence (C) and ADC sequence (D)

sometimes the lesion tends to be so long to involve the optic nerve head in the orbital portion, consistent with the high frequency of optic disc edema resulting in optic nerve head swelling.<sup>[3,4]</sup> The presence of radiological optic nerve head swelling, in particular, was significant and highly suggestive of MOG-ON.<sup>[4]</sup>

Inflammation and enhancement of the perioptic nerve sheath, partly extending into the surrounding fat, is often demonstrated in 50% of patients<sup>[3,10]</sup> and 47% of patients<sup>[8,11,12]</sup> with MOG-ON. Perineural optic nerve enhancement is unusual in AQP4-ON and MS-ON.<sup>[12]</sup> Its presence, therefore, is crucial and suggestive of MOG-ON.<sup>[3,10]</sup> However, this specific finding was not observed in our patient.

Clinically, compared to AQP4-ON, patients with MOG-ON have better visual field outcomes, although recurrence of ON is significantly more frequent.<sup>[3,4]</sup> A relapsing course has been reported in 44–83% of patients.<sup>[3]</sup>

Our patient demonstrates unique radiological findings of MOG-ON, more frequently resulting in bilateral and longitudinally extensive ON likely to be associated with anterior visual pathway involvement, while AQP4 antibodies are more commonly associated with posterior visual pathway involvement. This radiological differentiation may assist clinicians and radiologists with a prompt diagnosis of ON.

#### Declaration of patient consent

The authors certify that they have obtained all appropriate patient consent forms. In the form the patient(s) has/have given his/her/their consent for his/her/their images and other clinical information to be reported in the journal. The patients understand that their names and initials will not be published and due efforts will be made to conceal their identity, but anonymity cannot be guaranteed.

#### Financial support and sponsorship

Nil.

#### Conflicts of interest

There are no conflicts of interest.

## References

1. Wynford-Thomas R, Jacob A, Tomassini V. Neurological update: MOG antibody disease. *J Neurol* 2019;266:1280-6.
2. Cellina M, Fetoni V, Ciocca M, Pirovano M, Oliva G. Anti-myelin oligodendrocyte glycoprotein antibodies: Magnetic resonance imaging findings in a case series and a literature review. *Neuroradiol J* 2018;31:69-82.
3. Denève M, Biotti D, Patsoura S, Ferrier M, Meluchova Z, Mahieu L, *et al.* MRI features of demyelinating disease associated with anti-MOG antibodies in adults. *J Neuroradiol* 2019;46:312-8.
4. Ramanathan S, Prelog K, Barnes EH, Tantsis EM, Reddel SW, Henderson AP, *et al.* Radiological differentiation of optic neuritis with myelin oligodendrocyte glycoprotein antibodies, aquaporin-4 antibodies, and multiple sclerosis. *Mult Scler* 2015;15:1-13.
5. Biotti D, Bonneville F, Tournaire E, Ayrygnac X, Dallièrè CC, Mahieu L, *et al.* Optic neuritis in patients with anti-MOG antibodies spectrum disorder: MRI and clinical features from a large multicentric cohort in France. *J Neurol* 2017; 264:2173-5.
6. Compston A, Coles A. Multiple sclerosis. *Lancet* 2008;372:1502-17.
7. Sato DK, Callegaro D, Lana-Peixoto MA, Water PJ, De H, Jorge FM, *et al.* Distinction between MOG antibody-positive and AQP4 antibody-positive NMO spectrum disorders. *Neurology* 2014;82:474-81.
8. Akaishi T, Sato DK, Nakashima I, Takeshita T, Takahashi T, Doi H, *et al.* MRI and retinal abnormalities in isolated optic neuritis with myelin oligodendrocyte glycoprotein and aquaporin-4 antibodies: A comparative study. *J Neurol Neurosurg Psychiatry* 2016;87:446-8.
9. Carra-Dalliere C, Menjot de Champfleury N, Ayrygnac X, Labauge P. Optic chiasm and oculomotor nerves involvement in active multiple sclerosis. *J Neuroradiol* 2020;47:62-4.
10. Chen JJ, Flanagan EP, Jitprapaikulsan J, López-Chiriboga AS, Fryer JP, Leavitt JA, *et al.* Myelin oligodendrocyte glycoprotein antibody-positive optic neuritis: Clinical characteristics, radiologic clues, and outcome. *Am J Ophthalmol* 2018;195:8-15.
11. Jarius S, Ruprecht K, Kleiter I, Borisow N, Asgari N, Pitarokoilis K, *et al.* MOG-IgG in NMO and related disorders: A multicenter study of 50 patients. Part 2: Epidemiology, clinical presentation, radiological and laboratory features, treatment responses, and long-term outcome. *J Neuroinflammation* 2016;13:280.
12. Kim SM, Woodhall MR, Kim JS, Kim SJ, Park KS, Vincent A, *et al.* Antibodies to MOG in adults with inflammatory demyelinating disease of the CNS. *Neurol Neuroimmunol Neuroinflamm* 2015;2:e163.