

CASE REPORT

Osseous metaplasia of antrochoanal polyp: Case report and radiological-pathological correlation

Samrat Mandal, Arindam Bhandari, Sunil Jalan¹, Rajib Kumar Mondal²

Departments of Radiology and ¹Otorhinolaryngology, Kothari Medical Centre, ²Department of Pathology, NRS Medical College, Kolkata, West Bengal, India

Correspondence: Dr. Samrat Mandal, 29 Dhirendranath Ghosh Road, Kolkata - 700 025, West Bengal, India. E-mail: sm2yv@virginia.edu

Abstract

Osseous metaplasia of inflammatory sinonasal polyp is an extremely rare entity. Correct preoperative diagnosis by noncontrast CT scan is needed to rule out other more common bony neoplasms in paranasal sinuses and for accurate surgical planning. Here, we present a case of 20-year-old patient with an antrochoanal polyp with osseous metaplasia. We describe the lesion and discuss the radiological differential diagnosis thereby providing a brief review of literature of the few published cases worldwide along with histopathological correlation.

Key words: Antrochoanal polyp; CT; osseous metaplasia

Introduction

Osseous metaplasia of inflammatory sinonasal polyp is an extremely rare entity. Preoperative imaging evaluation of sinonasal polyps is usually done by noncontrast CT scan of paranasal sinuses. Correct identification of this rare entity preoperatively and differentiation from radiological mimics is of utmost clinical importance.

Case Presentation

A 20-year-old female presented with chronic left nasal blockage and headache for 1 year. She had no history of documented fever or epistaxis during that period. On nasal examination and nasal endoscopy, pale polypoidal mass was seen in left nasal cavity and left nasopharynx arising from lateral wall of nose.

Noncontrast CT scan [Figures 1-4] showed a soft tissue polypoidal lesion arising from left maxillary sinus extending into left nasal cavity via widening of left accessory maxillary ostium. The polypoidal soft tissue was further extending upto nasopharynx via the left choana causing partial nasopharyngeal airway compromise. Within the central part of soft tissue polypoidal lesion, there was a bone density component which was completely surrounded by the soft tissue component of antrochoanal polyp and had no continuity with the bony walls of left maxillary sinus, left nasal cavity, and nasopharynx. No destruction of bony walls of nasal cavity and paranasal sinuses were noted.

The patient was treated with endoscopic sinus surgery with removal of the antrochoanal polyp. Intraoperative findings

This is an open access journal, and articles are distributed under the terms of the Creative Commons Attribution-NonCommercial-ShareAlike 4.0 License, which allows others to remix, tweak, and build upon the work non-commercially, as long as appropriate credit is given and the new creations are licensed under the identical terms.

For reprints contact: reprints@medknow.com

Cite this article as: Mandal S, Bhandari A, Jalan S, Mondal RK. Osseous metaplasia of antrochoanal polyp: Case report and radiological-pathological correlation. Indian J Radiol Imaging 2019;29:468-71.

Received: 13-Jan-2019

Revision: 24-Mar-2019

Accepted: 20-Aug-2019

Published: 31-Dec-2019

Access this article online

Quick Response Code:



Website:
www.ijri.org

DOI:
10.4103/ijri.IJRI_488_18

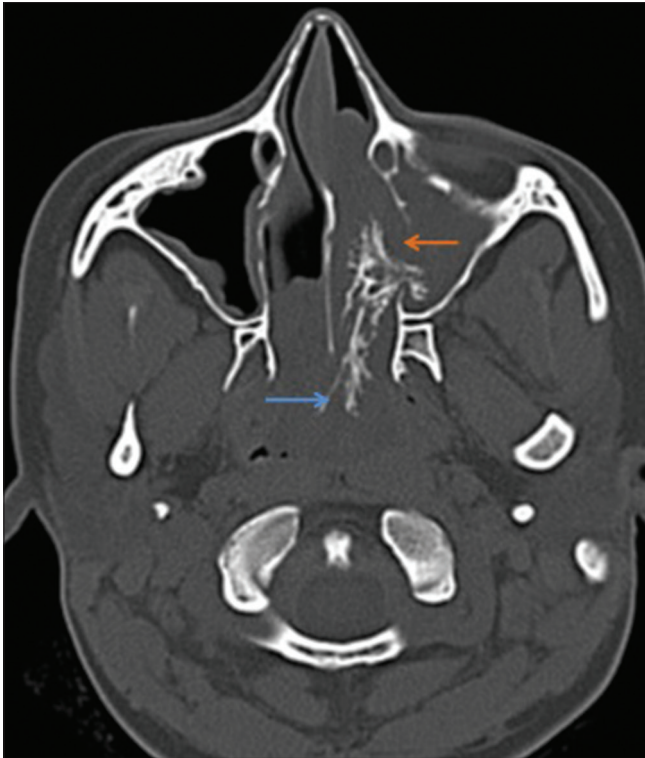


Figure 1: NCCT axial scan in bone window showing osseous trabeculae (blue arrow) within polyp passing from maxillary sinus to nasal cavity through accessory maxillary ostium (orange arrow)

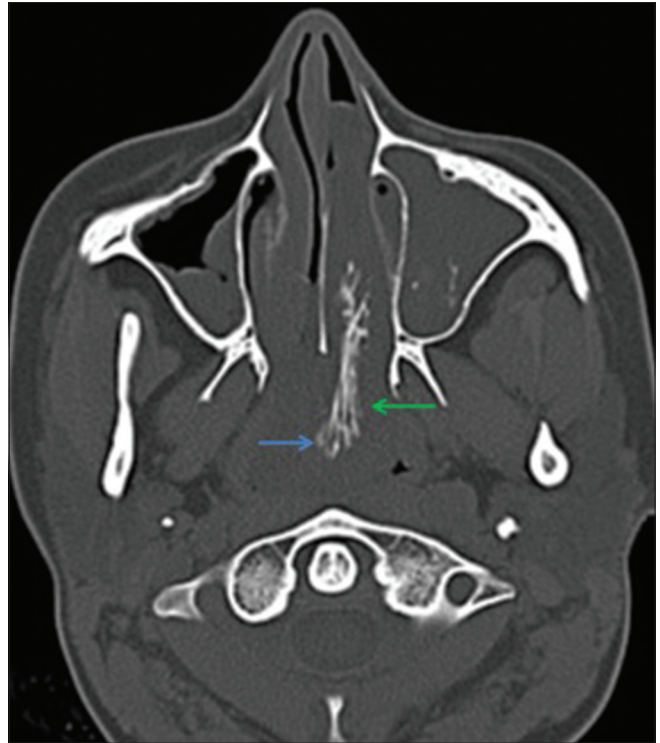


Figure 2: NCCT axial scan in bone window showing osseous trabeculae (blue arrow) within polyp passing from nasal cavity to nasopharynx through choana (green arrow)

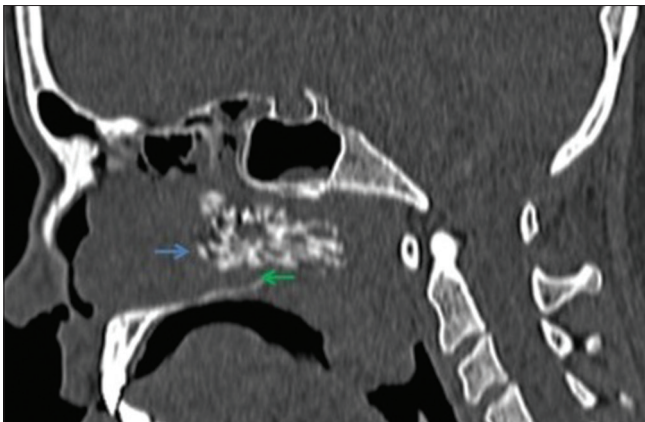


Figure 3: NCCT sagittal scan in bone window showing osseous trabeculae (blue arrow) within polyp passing from nasal cavity to nasopharynx through choana (green arrow)

included the presence of hard bony elements within the polyp [Figure 5] and the specimen was sent for histopathological evaluation. Microscopic examination of the sample confirmed the presence of osteoid material within the inflammatory nasal polyp [Figures 6 and 7].

Discussion

The term antrochoanal polyp refers to polyp that arises from antrum and extends out of maxillary sinus into nasal cavity through choana into nasopharynx.

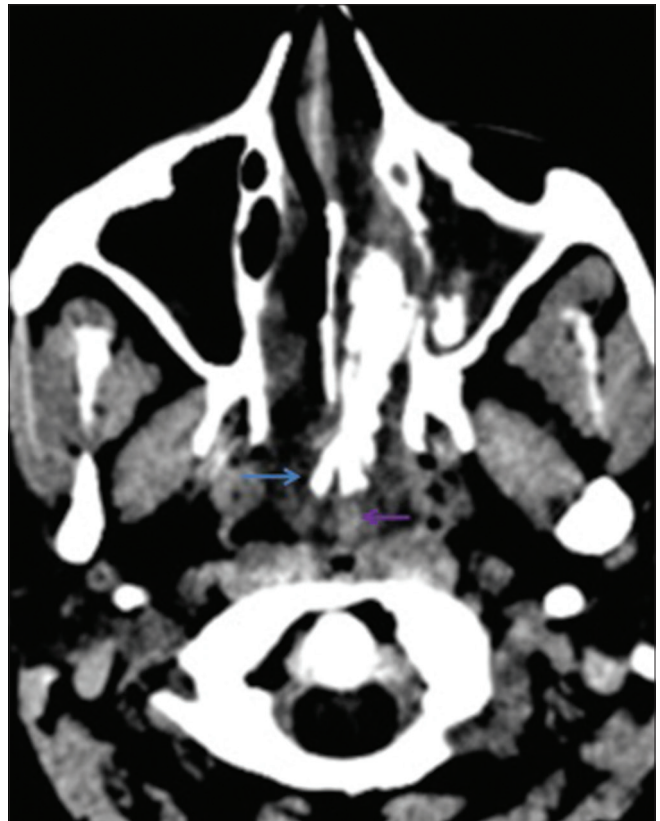

Figure 4: NCCT axial scan in soft tissue window showing the osseous component (blue arrow) of antrochoanal polyp embedded centrally within the soft tissue component of polyp (pink arrow)

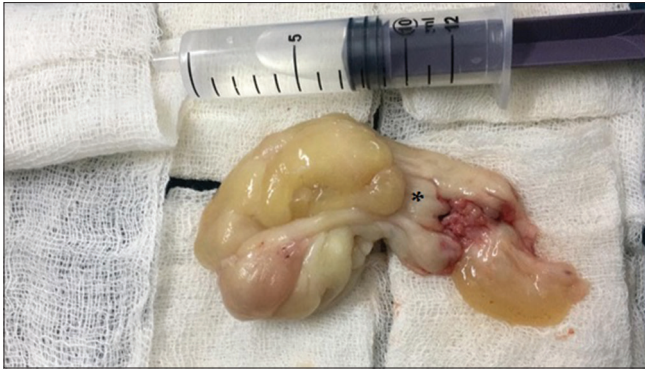

Figure 5: Surgical specimen with (*) marking the bony hard component in the excised polyp

Frosini *et al.*^[1] in their landmark paper has proposed a mechanism in which antrochoanal polyp are formed. There is initial infective/allergic process that leads to obstruction to acinar mucous glands and retention cyst formation. Subsequently due to narrowing or complete blockage of maxillary ostium and accessory maxillary sinus ostium, there is development of high pressure within the maxillary cavity. This high pressure results in herniation of retention cyst through accessory maxillary ostium resulting in formation of antrochoanal polyp.

Histopathologically, antrochoanal polyps are inflammatory. The polyps are lined by ciliated respiratory epithelium. At the submucosal level, there are abundance of plasma cells with scanty eosinophils.^[2] The overlying respiratory epithelium has been reported to undergo dysplastic or squamous metaplastic changes.^[3]

Osseous metaplasia of nasal mucosal polyps is a known rare entity. Cases of mucosal polyps with osseous metaplasia have been reported in other parts of the body such as stomach,^[4] rectum,^[5-7] and colon.^[8] Osseous metaplasia of mucosal polyps is a much rarer entity with cases being reported from external auditory canal, tongue, and nasal polyps.^[9]

The exact mechanism of osseous metaplasia is still vastly unknown. Mesenchymal cells in mucosal polyps are believed to differentiate into osteoblasts with raised local alkaline phosphatase secretion.^[10] Role of bone morphogenetic proteins^[11] and upregulation of type-1 collagen and osteonectin^[12] have been also implicated.

A literature survey reveals only few sporadic published cases^[9,13-16] of osseous metaplasia of nasal polyp in last four decades and the largest case series was of five patients published by Kim *et al.*^[17]

Osseous metaplasia is a rare entity and presence of bone density component within an endonasal lesion can simulate other common entities such as chronic fungal allergic polyps with hyperdense components, rhinoliths, and tumours

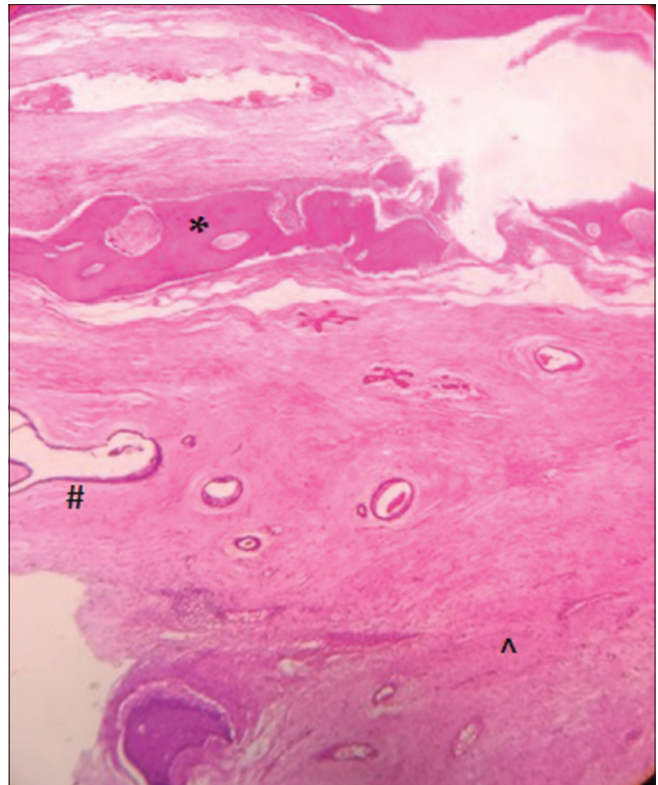


Figure 6: Section shows tissue lined by benign respiratory epithelium (#) with underlying loose myxoid stroma and few seromucinous glands. Chronic inflammatory infiltrate (^) seen within the stroma. Foci of osseous metaplasia (*) noted (hematoxylin-eosin stain; low magnification)

such as osteosarcoma, chondrosarcoma, and fibro-osseous lesions.

In our case, NCCT showed hyperdense bony component which was centrally located. It was completely surrounded by soft tissue on all sides. There was mild widening of accessory maxillary ostium and mild remodelling of nasal cavity. No gross destruction of walls of maxillary sinus, nose, or nasopharynx was noted. These features made the alternate diagnosis of neoplastic lesion like osteosarcoma unlikely. The ring and arc pattern of chondroid calcification that is seen in chondrosarcoma was absent.

Our case could be easily distinguished from rhinoliths and fungal elements on NCCT because of large size, dumb-bell shape of bony component with linear well-defined trabeculae extending from the maxillary sinus through accessory ostium into nasal cavity, and nasopharynx.

Management of sinonasal polyps with osseous metaplasia is similar to other sinonasal polyps and endoscopic sinus surgery remains the current treatment of choice. However, due to hardness of the polyp, extraction of the mass can be challenging. Jacono *et al.*^[17] has reported a case where the nasal polyp with osseous metaplasia was so hard that the mass had to be delivered through mouth.

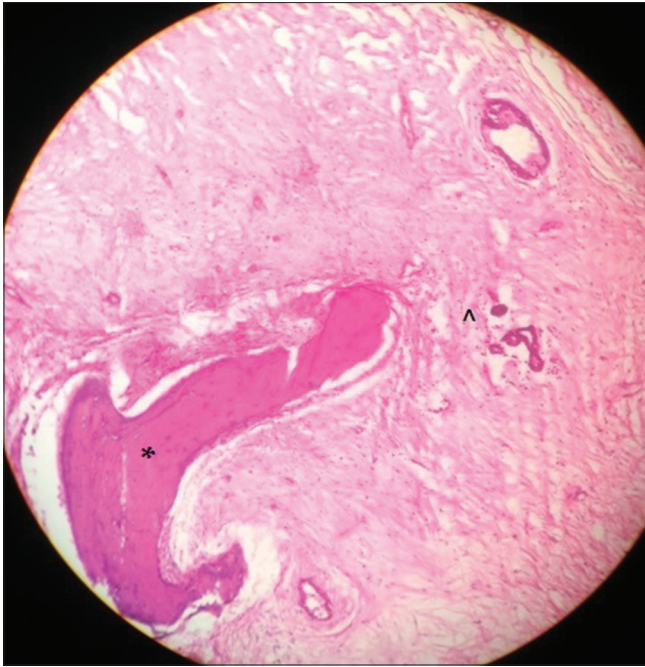


Figure 7: Section shows loose myxoid stroma and few seromucinous glands. Chronic inflammatory infiltrate (^) seen within the stroma. Foci of osseous metaplasia (*) noted. (hematoxylin-eosin stain; intermediate magnification)

Our case was managed through endoscopic sinus surgery uneventfully.

Conclusion

Though only few cases of osseous metaplasia have been published in literature till date and no cases have been published from India to our knowledge till date, radiologists need to be aware of the existence of this entity and be able to differentiate from other radiologic mimics. A large bony component within a polyp may lead to significant intraoperative difficulty in removal of the polyp and increase duration of operation thereby increasing the possibility of subsequent postoperative complications. Preoperative diagnosis of osseous metaplasia helps in improved surgical planning and may lead to eventual better patient outcome.

Declaration of patient consent

The authors certify that they have obtained all appropriate patient consent forms. In the form the patient(s) has/have given his/her/their consent for his/her/their images and other clinical information to be reported in the journal. The patients understand that their names and initials will not be published and due efforts will be made to conceal their identity, but anonymity cannot be guaranteed.

Financial support and sponsorship

Nil.

Conflicts of interest

There are no conflicts of interest.

References

1. Frosini P, Picarella G, De Campora E. Antrochoanal polyp: Analysis of 200 cases. *Acta Otorhinolaryngol Ital* 2009;29:21-6.
2. Balıkcı H, Ozkul M, Uvacin O, Yasar H, Karakas M, Gurdal M. Antrochoanal polyposis: Analysis of 34 cases. *Eur Arch Otorhinolaryngol* 2013;270:1651-4.
3. Couto LG, Fernandes AM, Brandão DF, Neto S, Valera FC, Anselmo-Lima WT, *et al.* Histological aspects of rhinosinusal polyps. *Braz J Otorhinolaryngol* 2008;74:207-12.
4. Zapata E, Castiella A, Zubiaurre L, Agirre A, Rodriguez J. Osseous metaplasia in a gastric adenomatous polyp. *Endoscopy* 2012;44(Suppl 2UCTN):E81.
5. Oono Y, Fu KL, Nakamura H, Iriguchi Y, Oda J, Mizutani M, *et al.* Bone formation in a rectal inflammatory polyp. *World J Gastrointest Endosc* 2010;2:104-6.
6. Zemheri E, Toprak M, Zerk PE, Ozkanli S, Mutus M. Inflammatory rectal polyp with osseous metaplasia. *Medeniyet Med J* 2015;30:143-6.
7. Odum BR, Bechtold ML, Diaz-Arias A. Osseous metaplasia in an inflammatory polyp of the rectum: A case report and review of the literature. *Gastroenterol Res* 2012;5:74.
8. White V, Shaw AG, Tierney GM, Lund JN, Semeraro D. Osseous metaplasia in an ulcerating tubular adenoma of the colon: A case report. *J Med Case Rep* 2008;2:130.
9. Jacono AA, Sclafani AP, Van TDW, McCormick S, Frenz D. Metaplastic bone formation in nasal polyps with histologic presence of transforming growth factor beta-1 (TGFbeta-1) and bone morphogenetic proteins (BMPs). *Otolaryngol Head Neck Surg* 2001;125:96-7.
10. Randall JC, Morris DC, Tomita T, Anderson HC. Heterotopic ossification: A case report and immunohistochemical observations. *Hum Pathol* 1989;20:86-8.
11. Liu K, Tripp S, Layfield LJ. Heterotopic ossification: Review of histologic findings and tissue distribution in a 10-year experience. *Pathol Res Pract* 2007;203:633-40.
12. Chauveau C, Devedjian JC, Blary MC, Delecourt C, Hardouin P, Jeanfils J, *et al.* Gene expression in human osteoblastic cells from normal and heterotopic ossification. *Exp Mol Pathol* 2004;76:37-43.
13. Yilmaz M, Ibrahimov M, Kilic E, Ozturk O. Heterotopic bone formation (osseous metaplasia) in nasal polyps. *J Craniofac Surg* 2012;23:620.
14. Shafii M, Saatian M, Aliehyai F, Jangholi E, Najibpour R, Farshad A. Nasal polyp with heterotopic bone formation (osseous metaplasia): A case report. *Galen Med J* 2013;2:80-2.
15. Cho IY, Kim JW, Kim HJ, Cho KS. Septochoanal polyp with metaplastic ossification mimicking sinonasal tumor: A case report. *Iran J Radiol* 2016;13.
16. Promsopa C. Septochoanal polyp with osseous metaplasia: A case report. *J Med Case Rep* 2016;10:149.
17. Kim YK, Kim HJ, Kim J, Chung SK, Kim E, Ko YH, *et al.* Nasal polyps with metaplastic ossification: CT and MR imaging findings. *Neuroradiology* 2010;52:1179-84.