

Demographic and clinico-radiological profile on High-Resolution Computerized Tomography (HRCT) thorax in mild or asymptomatic clinically suspected COVID-19 patients in high-endemicity area of India—Can HRCT be the first screening tool? –The DECRYPTION study

Kamal Sharma, Amit Gupta¹, Komal Vadgama¹, Hardik D Desai², Neha Sharma³, Komal Shah⁴, Dhigishaba M Jadeja⁵

U N Mehta Institute of Cardiology and Research Center, Affiliated to B J Medical College, ¹Usmanpura Imaging Center, ³Cardiology Clinic, Ahmedabad, ²Graduate Medical Education, Gujarat Adani Institute of Medical Sciences, Affiliated to K S K V University, ⁵Gujarat Adani Institute of Medical Sciences, Affiliated to K S K V University, Bhuj, ⁴Indian Institute of Public Health, Gandhinagar, Gujarat, India

Correspondence: Prof. Kamal Sharma, U N Mehta Institute of Cardiology and Research Center, Affiliated to B J Medical College, Ahmedabad, Gujarat, India. E-mail: drkamalsharma@unmicrc.org

Abstract

Background: With COVID-19 cases rising, despite CT chest being of value in diagnosis and prognostication in COVID-19, its role in mild or asymptomatic suspected COVID-19, before RT-PCR test is lacking. **Method:** This is a retrospective observational study involving asymptomatic or mildly symptomatic clinically suspected COVID-19 infection in a high endemicity area. Of 2532 HRCT chest database, 376 eligible cases were analyzed for clinico-radiological correlation for CT findings based CORADS and CT severity score between positive vs negative group. **Results:** Of 376, 186 (48.46%) had COVID-19 features on HRCT in mild and asymptomatic suspected patients. 98 (26.06%) had CO-RARDS - 5, 88 (23.40%) had CO-RADS - 4. 48 (12.76%), 128 (34.04%), 14 (3.72%) had CO-RADS score of 3,2,1, respectively. Positive CT findings were more likely beyond 3 days of symptoms compared to those presenting earlier {days: (Mean) 4.2 vs 2.76} Positive CT was significantly associated with patients with anosmia and dyspnea. The common presenting symptoms were Fever 196 (52.12%) and followed by sore throat in 173 (46.01%). The common

Video Available on: www.ijri.org

Access this article online

Quick Response Code:



Website:
www.ijri.org

DOI:
10.4103/ijri.IJRI_796_20

This is an open access journal, and articles are distributed under the terms of the Creative Commons Attribution-NonCommercial-ShareAlike 4.0 License, which allows others to remix, tweak, and build upon the work non-commercially, as long as appropriate credit is given and the new creations are licensed under the identical terms.

For reprints contact: WKHLRPMedknow_reprints@wolterskluwer.com

Cite this article as: Sharma K, Gupta A, Vadgama K, Desai HD, Sharma N, Shah K, *et al.* Demographic and clinico-radiological profile on High-Resolution Computerized Tomography (HRCT) thorax in mild or asymptomatic clinically suspected COVID-19 patients in high-endemicity area of India—Can HRCT be the first screening tool? —The DECRYPTION study. *Indian J Radiol Imaging* 2021;31:S122-7.

Received: 26-Sep-2020

Revised: 14-Oct-2020

Accepted: 02-Jan-2021

Published: 23-Jan-2021

HRCT findings were Ground glass opacity (GGO) (74.60%), followed by Lymphadenopathy (LN) (27.92%). LN which was more prevalent in symptomatic patients {99/343 (28.86%) vs {6/33 (18.18%)}} asymptomatics (P : 0.04)}. Consolidation was significantly more in asymptomatics with COPD (P : 0.004). 6 (3.22%) patients had CT score $>17/25$. **Conclusion:** Chest HRCT picked 48.46% positive cases in mildly symptomatic and asymptomatic patients of which 3.22% had severe involvement (>17). Being a noninvasive, rapid, sensitive, low risk of cross infection with high reproducibility, chest CT is worth evaluating as screening modality even in asymptomatic and mildly symptomatic clinically suspected COVID-19.

Key words: COVID-19; high resolution CT; sars-cov-2; screening

Introduction

As the process of “unlocking” unfolded in India, the number of new cases of COVID-19 surged in many parts of the country. As of 17th September 2020 COVID-19 has affected 29,737,453 cases with 937,391 deaths worldwide with CFR dropping to (1.10%) 3.15 from 4.25 in June 2020.^[1] Due to high sensitivity of Computerized Tomography (CT) scan,^[2] there is a growing interest in this modality along with RT-PCR for the screening, diagnosis, prognostication and management of suspected and confirmed cases of COVID-19. However, due to limited availability especially in rural parts, higher costs, associated radiation hazard, and presumed lower test specificity as a screening tool, RT-PCR for COVID-19 remains the preferred modality of diagnosis. On the other hand, time delay for the results of nasopharyngeal RT-PCR, sampling site/collection errors, lower sensitivity as compared to CT scan and invasive nature of sampling apart from social reasons, pitches HRCT thorax as a possible alternative to RT-PCR as a screening modality especially in symptomatic cases.^[3] Small preliminary evidence suggests that early use of CT scan may be more efficacious in differentiating COVID-19 from other pulmonary infections based on “classical” COVID-19 specific findings on CT scan.^[4] Although, low specificity of HRCT would still mandate a confirmation by RT-PCR, the concern remains for continued infectivity and “community transmission” from a “false negative” RT-PCR of COVID-19 patients who are strongly suspected for symptomatic COVID-19 infection based on chest HRCT imaging.

Being a noninvasive modality with rapid test results, high sensitivity, low risk of cross infection, good reproducibility for analysis as compared to RT-PCR make chest CT worth evaluating as primary screening modality. With this background, we intended to study demographics, clinico-radiological profile including symptomatology and radiology profile in a high endemicity area of western India from a single high volume HRCT center in mildly symptomatic for clinically suspected COVID-19 by treating physician or asymptomatic high risk individuals comprising of Healthcare professionals (HCP) who were directly involved in care of COVID-19 patients viz. doctors,

paramedics etc., or individuals who had history of direct contact of a confirmed case of COVID-19 in last 14 days. We analyzed their data based on the results of HRCT thorax as positive if it showed classical radiological findings known in COVID-19 (CORADS -4/5) and Negative if the same were absent. (CORADS-1/2/3). We compared their demographics, clinical and radiological features. We also compared Symptomatic patients’ vs asymptomatic patients for the same.

Method

This was a single-center, observational, all-comers, retrospective analysis from a high-volume tertiary care radiology center in high endemicity zone of Western India. Out of a total of 2352 HRCT thorax done at our center between 1st April 2020 and 31st August 2020. We identified and analyzed database of 376 eligible patients based on inclusion and exclusion criteria, who were mildly symptomatic for clinically suspected COVID-19 by the treating physician or were asymptomatic high-risk individuals defined as HCP or individuals with recent history of exposure to a confirmed case of SARS-COV-2 patient in last 14 days and had underwent HRCT thorax prior to RT-PCR for COVID-19 [Figure 1]. This study hence excluded symptomatic and confirmed cases in the data base from the study. This retrospective study analysis was conducted after obtaining independent ethical committee approval and applicable waivers.

Patient population

The study population comprised of all-comers 376 eligible patients who were either asymptomatic high-risk HCP or individuals with recent exposure to a confirmed case or were mildly symptomatic for suspected COVID-19 infection by treating physician. The inclusion criteria were (1) Mild symptoms with clinical suspicion of COVID-19 as per diagnosis and treatment guidelines of “Ministry of Health and Family welfare of Government of India” or asymptomatic high-risk individuals like HCP or individuals with exposure to confirmed case COVID-19 in last 14 days.^[5] (2) Age >18 years, (3) <14 days from symptoms onset to 1st CT scan. (4) Patients who hadn’t undertaken COVID-19 serological or RT-PCR prior to scan.

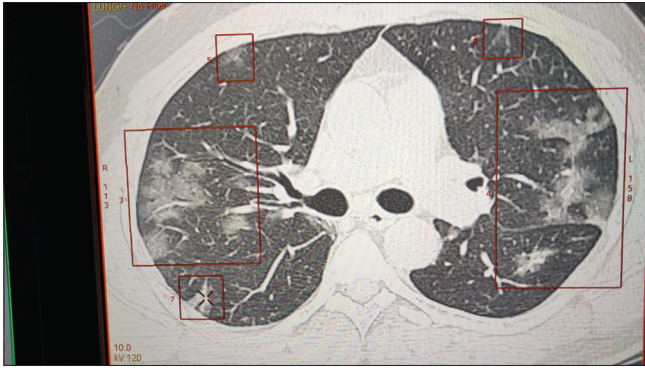

Figure 1: High resolution computed tomography (HRCT) in patients with COVID-19 suspected patients

Exclusion criteria were (1) Past medical history of Lung surgery (2) Lung Malignancy (3) age <18 years (4) Pregnancy (5) Known cases of COVID-19 prior to HRCT thorax (6) >14 days from symptoms onset to 1st CT scan.

Qualitative image analysis

CT imaging features of COVID-19 were reported based on CORADS scoring system for COVID-19 by 2 independently reporting senior radiologist. We summarized the features on chest HRCT based on lesion morphology as the presence of (1) a ground-glass opacities (GGOs); (2) consolidation; (3) crazy-paving pattern; (4) Bronchiolitis; (5) cavitation; (6) Emphysematous changes; (7) lymphadenopathy; (8) pleural effusion; (9) pulmonary atelectasis; or (10) pleural thickening (11) Bronchiectasis (12) Non-pulmonary findings. Lesion distribution, such as whether they were unilateral, bilateral, the number of lung lobes and segments involved and the involvement of the upper, middle, and lower fields of the lung was analyzed. CT severity score out of a maximum of 25 was calculated based on CT severity scoring as proposed by Chang *et al.*^[6] as following:

(Each of the 5 lobes were scored based on the extent of anatomic involvement) 0: no involvement; 1:<5% involvement; 2:5–25% involvement; 3: 26–50% involvement; 4: 51–75% involvement; and 5: >75% involvements.

CORADs score was reported as following.^[7]

CO-RADS 1: Normal or Noninfectious.

CO-RADS 2: Low (abnormalities typical for other infection other than COVID-19).

CO-RADS 3: Unsure (can be COVID-19 or other infection).

CO-RADS 4: High (abnormalities suspicious for COVID-19).

CO-RADS 5: very High (abnormalities highly suggestive of COVID-19).

Statistical analysis

Patient data were recorded by End note, and statistical analysis was performed using SPSS 20.0 (IBM Corporation). Normally distributed continuous variables are expressed as the mean \pm SD. Independent t-tests were used to compare measurement data. Categorical information is described by percentages and was compared using the Chi-squared test or Fisher's exact test. Multivariate regression was also performed by ANOVA test to evaluate association between chest CT morphology and presenting clinical symptoms if any and all statistical tests were bidirectional comparisons, and $P < 0.05$ was regarded as statistically significant.

Results

Amongst 2352 consecutive patients, 376 were found eligible for study; based on inclusion and exclusion criteria. Out of 376, 186 patients were found to be positive for COVID-19 features on HRCT thorax yielding 49.46% positivity rate in mild and asymptomatic suspected COVID-19 patients. Of 376 patients, males comprised 61.4%, with mean age 47.43 years (Range: 19-85). 98 (26.06%) had CO-RADS score of 5 followed by 88 (23.40%) had CO-RADS score of 4. 48 (12.76%), 128 (34.04%), 14 (3.72%) had CO-RADS score of 3,2,1, respectively. Table 1 shows that the mean age in HRCT Positive group was significantly higher with mean age of 49.95 years (SD: 15.64) vs 44.97 years (15.24) in negative group ($P: 0.003$). Time interval between symptoms onset or suspected exposure in asymptomatic individuals to CT imaging was a mean value of 3.47 days (SD: 2.35). Patients who presented early (1-3 days) after symptoms onset were more likely to be negative for COVID-19 on CT thorax than those who presented beyond 3 days ($P: < 0.0001$). 343 out of 376 (91.22%) patients were mildly symptomatic and only 8.78% were asymptomatic. The most common presenting symptom at the time of HRCT Thorax was Fever in 196 (52.12%), followed by sore throat in 173 (46.01%). 91 (24.20%) had anosmia, 56 (14.89%) reported mild Dyspnea, and 41 (10.90%) had Gastro-intestinal Symptoms. HRCT findings were statistically higher in patients who presented with anosmia and dyspnea ($P < 0.0001$). There was no significant difference observed in oxygen saturation between the two group (Mean: 94.48% vs 94.16%). The most common HRCT finding was Ground glass opacity (GGO) (74.60%), followed by Lymphadenopathy (LN) (27.92%), Consolidation (13.3%), Pleural effusion (2.62%) Bronchiectasis (2.62) and Crazy paving pattern (1.32%) [Image 1 and Video 1]. COVID-19 concordant findings such as GGO, LN, Consolidation were significantly higher in CT positive Group ($P: < 0.0001$). Pleural effusion was commonly observed in positive group, although not significantly higher than HRCT negative group.

The lesion distribution characteristics are shown in Table 2. For the positive group, lesions were distributed bilaterally

Table 1: General Demographic Information

Characteristics	Chest CT positive (n: 186) n/ Mean (SD)	Chest CT negative (n: 190) n/ Mean (SD)	P
Baseline characteristics			
Age (Years)	49.95 (15.64)	44.97 (18.24)	0.003
SpO ₂ (%)	94.48 (3.47)	94.16 (3.04)	0.308
Symptoms onset to 1 st Chest CT (days)	4.2 (2.38)	2.76 (2.1)	<0.0001
CT score	6.82 (4.57)	0	<0.0001
CO-RADS score	4.52 (0.50)	2.21 (0.53)	<0.0001
Gender			
Male	124	107	0.039
Female	62	83	
Symptom			
Asymptomatic	17	16	0.805
Symptomatic	169	174	
Sore throat	85	88	0.904
Fever	102	94	0.298
GI Symptoms	19	22	0.671
Anosmia	87	4	<0.0001
Dyspnea	48	8	<0.0001
CT Morphology			
GGO	179	0	<0.0001
Consolidation	48	1	<0.0001
LN	102	3	<0.0001
Pleural Effusion	8	2	0.07
Co-morbidities			
HTN	43	41	0.72
DM	18	17	0.80
COPD	13	11	0.63
IHD	8	6	0.55

CT=Computed Tomography, GGO=Ground glass opacity, LN=Lymphadenopathy, HTN=Hypertension, DM=Diabetes Mellitus, COPD=Chronic Obstructive Pulmonary Disease, IHD=Ischemic Heart Disease

in only 10/376 (2.62%) patients. Ten patients (2.62%) showed involvement of at least two lobes. Left lower lobe (70, 18.61%) and right lower lobe (70, 18.61%) involvement was most frequently observed followed by Right Upper Lobe, Left Upper lobe, Right middle lobe 25 (6.64%), 18 (4.78%), 9 (2.39%) respectively. On multivariate regression, GGO was found to have significant correlation with GI symptoms (coefficient of correlation: 0.18) (P : 0.005). Consolidation significantly correlated with sore throat as symptom amongst positive patients (coefficient of correlation: 0.7) (P : 0.04). Lymphadenopathy (LN) was frequently observed in patients with sore throat and dyspnea (Significant at P : 0.006, 0.01 respectively) followed by pleural effusion in patients having dyspnea (P : 0.01). Furthermore, there is no significant difference observed between asymptomatic vs symptomatic patients in CT morphology and demographic characteristics except LN which was significantly higher in symptomatic patients {99/343 (28.86%) vs 6/33 (18.18%) (P : 0.04)}. CT score was higher in patients without symptoms (Mean:

4.66 vs 3.25 asymptomatic vs symptomatic respectively) but was not statistically significant (P : 0.09). On multivariate regression analysis, consolidation was significantly higher in patients with COPD (P : 0.004, coefficient of correlation: 0.21) amongst symptomatic patients [Table 3]. 6 (3.22%) patients had CT score of more than 17 on Chest HRCT suggestive of severe disease.

Discussion

Chest HRCT imaging studies in asymptomatic COVID-19 individuals are meagre. Studies have reported that; chest HRCT can be normal in a considerable percentage of symptomatic COVID-19 patients too. Study by Ai *et al.* found that sensitivity of finding chest CT abnormalities was 97% in COVID-19 mildly symptomatic patients which was higher than that reported by Zhong *et al.* (76.4%).^[2,8] The current study is the first ever study in our knowledge to assess the HRCT abnormalities in mildly symptomatic or asymptomatic high-risk individuals as defined in protocol in high endemicity area from India. The positive yield of 49.46% in Chest HRCT in our cohort is higher than the seropositive study yield in community in same city during the same time period which was around 18% only.^[9] The study also highlights that even in asymptomatic or mildly symptomatic patients without pneumonia, HRCT is a tool worth evaluating in COVID-19.

In our study, we observed that more than half of the asymptomatic COVID-19 patients 17/33 (51.5%) had positive CT findings and amongst them GGO and consolidation were the most common lesion morphology present. Study done by Bernheim *et al.* reported that patients with 1st CT scan early in mild symptomatic phase 0-2 days from symptoms onset showed no evidence of lung disease in majority of the cases compared to those whose CT scan was done during intermediate phase (3-5 days) (56% vs 9%).^[10] Our study also reported similar findings that patients who presented during intermediate phase (3-6 days) [Table 1] with mild symptoms had higher rate of CT positive findings compared to those who presented in early phase (1-3 days) (P : <0.0001). This suggests that in mildly symptomatic who had early CT scan during first 3 days, HRCT yield may be lower for COVID-19 due to early disease course. This would make it advisable to screen clinically suspected COVID-19 patients with CT scan after 3 days of symptom onset or COVID-19 exposure in high risk asymptomatic individuals. Furthermore, almost half of the asymptomatic patients had CT features showing pattern of Ground glass opacity and crazy paving pattern.

In the current study, we observed that 6 (3.22%) patients had CT score of more than 17 on Chest HRCT. Study by Francone *et al.* have reported that patients with CT score (>18) had higher mortality/less survival rate as

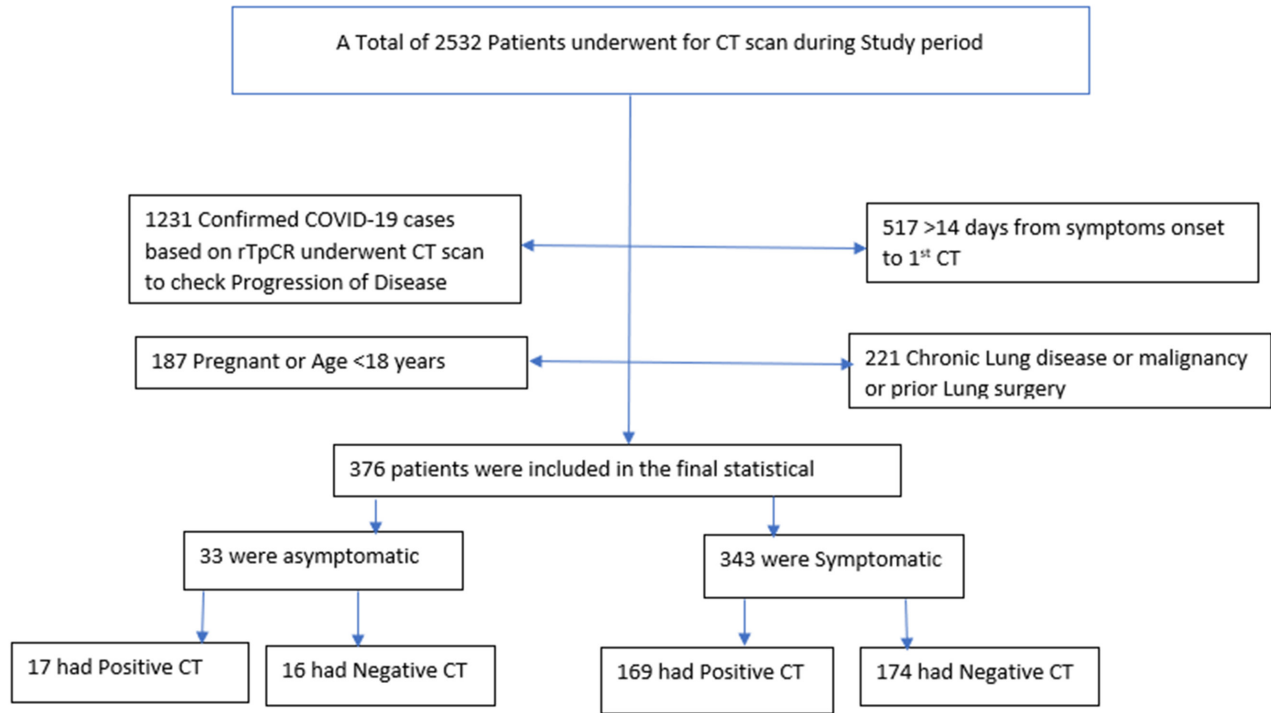


Image 1: Study flow chart

compared to those with lower score (<18).^[11] Thus chest CT might be an important diagnostic tool to assess for the disease severity or lesion pattern even in mildly symptomatic or asymptomatic high-risk individuals of which around 3% individuals can be identified early with higher likelihood of poor prognosis. Early diagnosis will help in immediate hospitalization of an infected patient and also isolation from the healthy population even when they are asymptomatic or mildly symptomatic suspected COVID-19 patients. This shall help clinician to manage the disease at early stage by early diagnosis and also prevent further community transmission.

On Clinico-radiological assessment we observed that patients who presented with clinical symptoms such as anosmia and dyspnea had higher CT positive findings ($P < 0.0001$). Furthermore, in multivariate regression of association between CT morphology and clinical symptoms, GGO was found to be higher in patients with GI symptoms ($P < 0.005$), followed by consolidation in patients with sore throat ($P : 0.05$). Lymphadenopathy correlated with sore throat and dyspnea in HRCT ($P: 0.006, 0.01$ respectively). Furthermore, Lymphadenopathy was more prevalent amongst symptomatic patients compared to asymptomatic ones ($P: 0.04$). The present study, also found a predominance of opacities in the lower lobes as compared to the middle and upper lobes, a finding consistent with previous studies.^[12,13] However, there was no significant difference observed in between Right and Left lower lung fields unlike other studies. This is the first ever study

Table 2: Lung Morphology and Lesion distribution on CT imaging in COVID-19 suspected Patients

Lung Morphology	n: 376 (%)
GGO	179 (74.60)
Consolidation	49 (13.3)
LN	105 (27.92)
Pleural Effusion	10 (2.65)
Crazy Paving Pattern	5 (1.32)
Bronchiectasis	10 (2.65)
Atelectasis	2
Pericardial Effusion	1
Bronchiolitis	3
Emphysematous Changes	2
Cystic Changes	1
Distribution Characteristics	
Bilateral Pulmonary Distribution	10
Right Upper Lobe	25
Right Lower Lobe	70
Right Middle Lobe	9
Left Upper Lobe	18
Left Middle Lobe	0
Left Lower Lobe	70
More than 2 Lobe	9
More than 3 Lobe	1

CT=Computed Tomography, GGO=Ground glass opacity, LN=Lymphadenopathy

from India looking at clinico-radiological profile in mildly symptomatic and asymptomatic high-risk individuals based on chest HRCT.

Table 3: Correlation showing between CT morphology vs COVID-19 specific clinical symptoms and Comorbidities

CT Morphology	Symptoms/Comorbidities	P	Correlation coefficient
GGO	GI Symptoms	0.005	0.18
Consolidation	Sore throat	0.04	0.07
	DM	0.06	0.12
	COPD	0.01	0.18
LN	Sore throat	0.01	0.12
	Dyspnea	0.006	0.17
Plural Effusion	Dyspnea	0.01	0.06
	COPD	0.07	0.06

CT scan=Computed Tomography scan, GGO=Ground glass opacity, LN=Lymphadenopathy, COPD=Chronic Obstructive pulmonary disease, IQR=Interquartile range

Limitations

Being a retrospective analysis, the data may have recall bias for symptomatology and duration of exposure. Since the aim was to evaluate clinically suspected COVID-19 patients and compare the difference in CT imaging features between Positive and negative groups based on HRCT and not based on RT-PCR, clinical and demographics may vary in early stage of COVID-19 accordingly. Our inclusion criteria had a cut off of 14 days of symptom onset or exposure and could have confounded results for longer or other duration of exposure of COVID-19. Furthermore, study done by Bai H. *et al.* observed a variation in performance of 7 radiologists in finding CT sensitivity in COVID-19 (80%, 67%, 97%, 93%, 83%, 73%, and 70%), thus 2 reporting radiologist could have inter-personal observational variability in assessing and reporting the chest CT and thus confounding the results.^[14] A prospective multicentric study may overcome this potential limitation of this study.

Conclusion

As the number of cases continue to rise, optimizing various diagnostic and prognostic modalities has a potential place for chest HRCT. Chest HRCT was positive in nearly 50% of mildly symptomatic and asymptomatic high-risk individuals in high endemicity area. Chest HRCT positive patients were older, more likely in those with anosmia and dyspnea while GI symptoms also correlated with GGO. LN was less likely in asymptomatic individuals. Findings were more likely to be picked after day 3 as compared to first 3 days. This strategy can pick 3.22% cases with severe disease (CT score >17) in asymptomatic or mildly symptomatic suspected COVID-19 cases.

Financial support and sponsorship

Nil.

Conflicts of interest

There are no conflicts of interest.

References

- Desai HD, Jadeja DM, Sharma K. Takotsubo syndrome a rare entity in patients with COVID-19: An updated review of case-reports and case-series. *Int J Cardiol Heart Vasc* 2020;29:100604.
- Ai T, Yang Z, Hou H, Zhan C, Chen C, Lv W, *et al.* Correlation of chest CT and RT-PCR testing for coronavirus disease 2019 (COVID-19) in China: A report of 1014 cases. *Radiology* 2020;296:E32-40.
- Fang Y, Zhang H, Xie J, Lin M, Ying L, Pang P, *et al.* Sensitivity of chest CT for COVID-19: Comparison to RT-PCR. *Radiology* 2020;296:E115-7.
- Himoto Y, Sakata A, Kirita M, Hiroi T, Kobayashi KI, Kubo K, *et al.* Diagnostic performance of chest CT to differentiate COVID-19 pneumonia in non-high-epidemic area in Japan. *Jpn J Radiol* 2020;38:400-6.
- Clinical Management protocol COVID-19 "Ministry of Health and Family welfare Government of India" June 13th 2020, Available from: <https://www.mohfw.gov.in/pdf/ClinicalManagementProtocolforCOVID19.pdf>.
- Chang YC, Yu CJ, Chang SC, Galvin JR, Liu HM, Hsiao CH, *et al.* Pulmonary sequelae in convalescent patients after severe acute respiratory syndrome: Evaluation with thin-section CT. *Radiology* 2005;236:1067-75.
- Prokop M, van Everdingen W, van Rees Vellinga T, van Ufford HQ, Stöger L, Beenen L, *et al.* CO-RADS: A categorical CT assessment scheme for patients suspected of having COVID-19-definition and evaluation. *Radiology* 2020;296:E97-104.
- Guan WJ, Ni ZY, Hu Y, Liang WH, Ou CQ, He JX, *et al.* Clinical characteristics of coronavirus disease 2019 in China. *N Engl J Med* 2020;382:1708-20.
- "The Times of India." Available from: <https://timesofindia.indiatimes.com/city/ahmedabad/ahmedabad-has-no-herd-immunity-only-17-6-have-antibodies/articleshow/77137851.cms>.
- Bernheim A, Mei X, Huang M, Yang Y, Fayad ZA, Zhang N, *et al.* Chest CT findings in coronavirus disease-19 (COVID-19): Relationship to duration of infection. *Radiology* 2020;295:200463.
- Francone M, Iafrate F, Masci GM, Coco S, Cilia F, Manganaro L, *et al.* Chest CT score in COVID-19 patients: Correlation with disease severity and short-term prognosis. *Eur Radiol.* 2020;30:6808-17.
- Wu J, Wu X, Zeng W, Guo D, Fang Z, Chen L, *et al.* Chest CT findings in patients with corona virus disease 2019 and its relationship with clinical features. *Invest Radiol* 2020;55:257-61.
- Yang R, Li X, Zhen Y, Liu H, Zhen Y, Zhang X, *et al.* Chest CT score: An imaging tool for assessing severe COVID-19. *Radiol Cardiothorac Imaging.* 2020;2:e200047.
- Bai HX, Hsieh B, Xiong Z, Halsey K, Choi JW, Tran TML, *et al.* Performance of radiologists in differentiating COVID-19 from non-COVID-19 viral pneumonia at chest CT. *Radiology* 2020;296:E46-54.