

The utility of HRCT in the initial diagnosis of COVID-19 pneumonia—An Indian perspective

Rohan Kashyape, Richa Jain¹

Medall Spark Diagnostics, Nashik, Maharashtra, ¹Aster CMI Hospital New Airport Road, NH-7, Outer Ring Rd, Sahakar Nagar, Bengaluru, Karnataka, India

Correspondence: Dr. Rohan Kashyape, Consultant Radiologist, Medall Spark Diagnostics. E-mail: rskashyape@gmail.com

Abstract

A total of 1,499 patients who underwent High Resolution Computed tomography (HRCT) chest in the duration of 2 months for suspected COVID-19 pneumonia were included. Subjects included were those who had tested positive for the virus on RT-PCR, those with symptoms suspicious for COVID-19 infection awaiting results for the RT-PCR test or with negative result but strong clinical suspicion as well as those with exposure to proven patients based on contact tracing. Thus, both symptomatic as well as asymptomatic patients were included. The positive predictive value of HRCT was 85%, sensitivity was 73% for all patients. Overall, accuracy was 68%. There was no significant difference in these values for symptomatic and asymptomatic individuals. These results were also independent of the time of scan from the onset of symptoms or contact. Thus, we propose that HRCT is an excellent adjunct for initial diagnosis of COVID-19 pneumonia in both symptomatic and asymptomatic individuals in addition to the role of prognostic indicator for COVID-19 pneumonia.

Key words: COVID-19, diagnosis, high resolution computed tomography

Background

COVID-19 induced viral pneumonia pandemic has now raged for more than 10 months across the world and has severely affected several countries including India. As of early November 2020, more than 8.7 million cases have been reported in India with nearly 1,29,000 deaths. Of these, the highest number (nearly 1.74 million) have been reported from state of Maharashtra.

Despite the promise of vaccine and ever-evolving treatment strategies; case identification, isolation, contact tracing remain the cornerstone of the strategy to control the pandemic. Though RT-PCR is the gold standard for diagnosis of COVID-19, limitations include limited availability, long

turn-around times, false-negative reports means that the sensitivity remains around 70%.^[1] Previous researchers have shown that the false-negative ratio of RT-PCR test for patients infected with COVID-19 is approximately 1 in 5.^[2]

HRCT has been widely accepted for prognostication of COVID-19 pneumonia.^[3]

We evaluated the sensitivity of HRCT in symptomatic and asymptomatic cases and contacts in the setting of a stand-alone diagnostic centre in Nashik, Maharashtra.

This is an open access journal, and articles are distributed under the terms of the Creative Commons Attribution-NonCommercial-ShareAlike 4.0 License, which allows others to remix, tweak, and build upon the work non-commercially, as long as appropriate credit is given and the new creations are licensed under the identical terms.

For reprints contact: WKHLRPMedknow_reprints@wolterskluwer.com

Cite this article as: Kashyape R, Jain R. The utility of HRCT in the initial diagnosis of COVID-19 pneumonia—An Indian perspective. *Indian J Radiol Imaging* 2021;31:S178-81.

Received: 15-Dec-2020

Revised: 15-Dec-2020

Accepted: 15-Dec-2020

Published: 23-Jan-2021

Access this article online

Quick Response Code:



Website:
www.ijri.org

DOI:
10.4103/ijri.IJRI_944_20

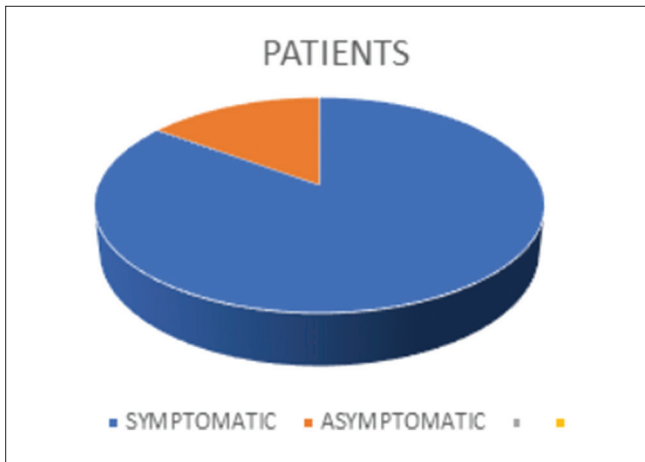


Figure 1: Pie chart showing symptomatic vs asymptomatic patients in the present cohort

Table 1: Sensitivity, specificity and predictives values of findings on HRCT compatible with COVID 19 Pneumonia in both asymptomatic and symptomatic individuals

	Asymptomatic (in %)	Symptomatic (in %)
Sensitivity	73.1	71.2
Specificity	50	57
Positive predictive value	84.4	85.5
Negative predictive value	33.3	35.2
Accuracy	68.2	68.1

Objectives

The objective was to test the hypothesis that HRCT is a sensitive tool for the primary diagnosis of COVID-19 pneumonia irrespective of symptoms.

Methods

Study design: This was a retrospective, cross-sectional study. HRCT is already proven to be of significant prognostic value in diagnosed cases of COVID-19 pneumonia. A total of 1,499 patients who presented to the clinic in a 2-month duration of September and October were included. This was a stand-alone diagnostic centre in a Tier II city in Maharashtra, India.

HRCT was performed in a single breath-hold on a 16 slice- MDCT scanner (GE Healthcare, Brivo- CT385).

The patients included were either index cases who had been recently diagnosed for COVID-19 or patients whose testing was performed and results awaited but were clinically symptomatic. Also included were patients who were in close contact with already proven patients—these included both symptomatic as well as asymptomatic contacts. HRCT was deemed “positive” for diagnosis of COVID-19 pneumonia if either one or a combination of several well-described

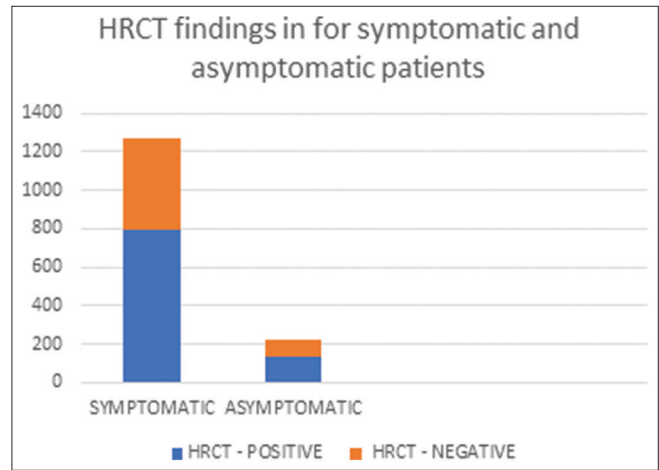


Figure 2: How many patients show findings compatible with COVID 19 Pneumonia on HRCT in both symptomatic and asymptomatic individuals

signs were seen—including but not limited to ground-glass opacities in typical peripheral subpleural distribution, subpleural/interlobular interstitial thickening, atoll sign, halo and reverse halo signs,^[4-8] to name a few. Further, CT severity index was evaluated for the patients who had a “positive” HRCT to assess the severity in these patients.

Statistical Analysis and Results

Though its well-known fact that 80% of all COVID-19 infections are asymptomatic, only 15.1% (226) of our patient population were asymptomatic [Figure 1]. This highlights the fact that most clinicians did not order for a HRCT in the asymptomatic—this further reflects the current belief that HRCT serves as a good diagnostic test and prognostic indicator in symptomatic individuals. However, its utility and accuracy in the asymptomatic group is not widely known. Of these asymptomatic individuals, 132 (58.7%) had at least one CT finding described in literature for a COVID-19 pneumonia [Figure 2]. Infact, 14 of these asymptomatic patients had a proven negative RT-PCR and yet had a CT finding suggesting a COVID-19 pneumonia on CT, these were very likely false negative on RT PCR. Thus, HRCT helps to identify the COVID-19 pneumonia even in asymptomatic individuals irrespective of RT-PCR. This is crucial and means that HRCT can and should be used for initial diagnosis of patients irrespective of symptoms and RT-PCR.

84.9% (1273) of all patients were symptomatic (defined for purpose of this study as at least one of the common symptoms described for COVID-19 infection including fever, cough, breathlessness, weakness, body ache, headache, throat pain). Of these, 928 (72.8%) had at least one CT finding described in literature for a COVID-19 pneumonia. Infact, 34 (3%) of these patients had a proven negative RT-PCR and yet had a CT finding suggesting a COVID-19 pneumonia on CT, indicating that these were

very likely false negative on RT-PCR. Additionally, 557 were RT-PCR status unknown (either not done or result was not available). So a total of 591 patients (39.42%) were diagnosed faster/more accurately because CT was done in these patients.

At the time of the scan, RT-PCR results were available for 499 patients. There were a total of 392 positive, 107 proven negative subjects. RT-PCR status was not known or not available for a total of 1,000 subjects. This number is large and includes patients who were waiting for the results, those who had not been tested for a variety of reasons, those who were reluctant to declare their RT-PCR results. These highlight the real-world problems in a typical tier II city in India and further stress the need for a multipronged strategy to diagnose, isolate, and treat patients using all available means.

Diagnostic HRCT findings were seen in 68% of all patients irrespective of symptoms and day of scan from the onset of symptoms/exposure [Table 1].

Discussion

In the fight against the coronavirus pandemic, early and accurate diagnosis of patients, including those with little or no symptoms is crucial.^[3,9] This is especially because nearly 80% of all infections have little or no symptoms and yet, these individuals are equally infective and thus play a major role in spreading the pandemic. Existing serological tests including RT-PCR swab test, rapid antigen, and antibody tests each have their limitations. In particular, the dangers of a false-negative result have been highlighted previously.^[10] RT-PCR has a turnaround time of at least 24–48 h. For an asymptomatic individual in the infectious period, however, these 24–48 h can be crucial as she/he can still spread the infection to close contacts.^[11–14] Thus, the need for fast turn-around time for an accurate test is crucial. Also, the invasive nature of the test, social taboo increasingly associated with the testing are deterrents especially for asymptomatic individuals to get themselves tested.

Especially in places where prevalence is high, a fast, non-invasive, accurate, and inexpensive test for screening and diagnosis is essential. The sensitivity of HRCT, when compared with RT-PCR, has been previously studied and was shown to be higher than RT-PCR.^[2]

In the present study, we have proven that HRCT chest is a sensitive test with high positive predictive value, most importantly, in the present study the accuracy was the same irrespective of symptoms.^[15] Additionally, with immediate availability of the result of the scan, crucial time is saved.

The cost for HRCT chest study in India (about 2,500-6,000 INR) being a fraction of those in the rest of the world is

a unique advantage which must be leveraged. From an infrastructure point of view for the administration, already existing facilities in both public and private healthcare providers mean that no additional ramping up of the facilities is required, saving costs and even more crucially, time. From healthcare providers perspective as well, since the scan is no different from other “routine” chest scans for non-COVID indications—thus the only “additional cost” for the scanner—facilities include those for protection of the healthcare personnel (for PPE, sanitization). Others being fixed costs (e.g., scanners, facility costs), there is only a marginal increase in the cost-burden to the providers.

Additional prognostic information provided with the CT severity index means it can be used as an important metric for a triage system to determine who needs to be admitted/home quarantined and so on.^[16] Easy scalability with high throughput, the possibility of remote diagnosis by leveraging teleradiology facilities mean that the HRCT chest is a very useful tool for initial diagnosis. Additional information for other causes of breathlessness (e.g., cardiomegaly/pleural effusions/pulmonary edema and even malignancies) may also be available. One of the problems always highlighted with CT scans is radiation burden. Average dose per study being about 7 mSv. This is much well within the limit of the max allowable dosage of 5 per year lower than the average 5 year dose of 100 mSv or 20 mSv/year as recommended by ICRP. Infact, accuracy of LDCT which has a lower overall average effective dose (approximately 2 mSv as compared with an average effective dose of 5–7 mSv for a typical standard-dose chest CT examination)^[17] needs to be further explored for the purpose of diagnosing COVID-19 pneumonia.^[18]

Limitations of our study include using the diagnostic criteria for COVID-19 pneumonia, these patients were labelled as “Findings consistent with or suspicious for COVID 19 pneumonia.” We are aware that several other processes including other viral pneumonia can appear similar on HRCT imaging. However, in view of the pandemic situation with high percentage positivity in RT-PCR results, we did not think this as a major limitation. Importantly, the radiologists were not blinded to the RT-PCR results. Though this was less relevant as nearly 2/3rd of the patients did not have a result, yet this could be a source of bias in the rest.

As of mid-November, India had performed about 12 million serological tests.^[19] Yet, only about 40% of these tests were with RT-PCR kits, and the remaining were rapid antigen tests. Though reports from China the epicenter of the pandemic when it started did give an indication of the important role of CT scan,^[2] guideline reports from the US and Europe in fact gave discouraging reports afterwards. We have proven that HRCT is a very useful tool for the initial diagnosis of patients suspected to have COVID-19 irrespective of symptoms or day of onset of CT. Considering

the many overall advantages, HRCT for the chest deserves to be included in the official diagnostic guidelines for diagnosis.

Financial support and sponsorship

Nil.

Conflicts of interest

There are no conflicts of interest.

References

- Kucirka L, Lauer S, Laeyendecker O, Boon D, Lessler J. Variation in false-negative rate of reverse transcriptase polymerase chain reaction-based SARS-Cov-2 tests by time since exposure. *Ann Intern Med*. 2020;173:262-7.
- Fang Y, Zhang H, Xie J, Lin M, Ying L, Pang P, *et al*. Sensitivity of chest CT for COVID-19: Comparison to RT-PCR. *Radiology* 2020;296:E115-7.
- Dong Y, Mo X, Hu Y, Qi X, Jiang F, Jiang Z, *et al*. Epidemiological characteristics of 2143 pediatric patients with 2019 coronavirus disease in China. *Pediatrics* 2020; doi: 10.1542/peds.2020-0702
- Salehi S, Abedi A, Balakrishnan S, Gholamrezanezhad A. Coronavirus disease 2019 (COVID-19): A systematic review of imaging findings in 919 patients. *AJR Am J Roentgenol* 2020;215:87-93.
- Parry AH, Wani AH, Yaseen M, Jehangir M, Choh NA, Dar KA. Spectrum of chest computed tomographic (CT) findings in coronavirus disease-19 (COVID-19) patients in India. *Eur J Radiol* 2020;129:109147.
- Pan Y, Guan H, Zhou S, Wang Y, Li Q, Zhu T, *et al*. Initial CT findings and temporal changes in patients with the novel coronavirus pneumonia (2019-nCoV): A study of 63 patients in Wuhan, China. *Eur Radiol* 2020;30:3306-9.
- Caruso D, Zerunian M, Polici M, Pucciarelli F, Polidori T, Rucci C, *et al*. Chest CT features of COVID-19 in Rome, Italy. *Radiology* 2020;296:E79-85.
- Ye Z, Zhang Y, Wang Y, Huang Z, Song B. Chest CT manifestations of new coronavirus disease 2019 (COVID-19): A pictorial review. *Eur Radiol* 2020;30:4381-9.
- Li R, Pei S, Chen B, Song Y, Zhang T, Yang W, *et al*. Substantial undocumented infection facilitates the rapid dissemination of novel coronavirus (SARSCoV2). *Science* 2020;368:489-93.
- West CP, Montori VM, Sampathkumar P. COVID-19 testing: The threat of false-negative results. *Mayo Clin Proc* 2020;95:1127-9.
- Real-time RT-PCR in COVID-19 detection: Issues affecting the results dx.doi.org/10.1080%2F14737159.2020.1757437.
- Kucirka LM, Lauer SA, Laeyendecker O, Boon D, Lessler J. Variation in false-negative rate of reverse transcriptase polymerase chain reaction-based SARS-CoV-2 tests by time since exposure. *Ann Intern Med* 2020:M20-1495. doi.org/10.7326/M20-1495.
- SUMMARY COVID-19 RT-PCR TEST – FDA. www.fda.gov/media/136151/download. [Last accessed on 2020 Apr 15].
- Corman VM, Landt O, Kaiser M, Molenkamp R, Meijer A, Chu DKW, *et al*. Detection of 2019 novel coronavirus (2019-nCoV) by real-time RT-PCR. *Euro Surveill* 2020;25:2000045.
- Ooi EE, Low JG. Asymptomatic SARS-CoV-2 infection. *Lancet Infect Dis* 2020;20:996-8.
- Altschul DJ, Unda SR, Benton J, de la Garza Ramos R, Cezayirli P, Mehler M, *et al*. A novel severity score to predict inpatient mortality in COVID-19 patients. *Sci Rep* 2020;10:16726.
- Larke FJ, Kruger RL, Cagnon CH, Flynn MJ, McNitt-Gray MM, Wu X, *et al*. Estimated radiation dose associated with low-dose chest CT of average-size participants in the national lung screening trial 3. *AJR Am J Roentgenol* 2011;197:1165-9.
- Ravenel JG, Scalzetti EM, Huda W, Garrisi W. Radiation exposure and image quality in chest CT examinations. *AJR Am J Roentgenol* 2001;177:279-84.
- Worldometers.info, release date November 2020.