

Role of chest radiography in the management of COVID-19 pneumonia: An overview and correlation with pathophysiologic changes

Anirudh Kohli, Pradipta C Hande, Shivam Chugh

Department of Radiology and Imaging, Breach Candy Hospital Trust, Mumbai, Maharashtra, India

Correspondence: Dr. Pradipta C Hande, Department of Radiology and Imaging, Breach Candy Hospital Trust, Mumbai - 400 026, Maharashtra, India. E-mail: pradipta.hande@gmail.com

Abstract

Background: Chest radiography (CXR) is a widely available baseline radiological modality in evaluating symptomatic patients with suspected or confirmed Covid-19 disease. Serial changes can help in monitoring the patients in conjunction with the clinical status of these patients in a hospital setting. **Purpose:** The purpose of this study was to analyse the patterns of radiological findings on chest radiograph (CXR) for suspected and confirmed COVID-19 patients on initial presentation to the emergency medical services (EMS) on admission and to assess the progression and resolution. **Materials and Methods:** In this study, patients who presented to EMS of a multispeciality hospital as suspected or confirmed Covid-19 on consecutive reverse transcriptase polymerase chain reaction (RT-PCR). CXR was examined for findings of haziness, patterns and distribution of opacities. Progression and regression of findings in serial CXR were studied and evaluated with the clinical and laboratory parameters. High resolution CT (HRCT) chest was performed initially for some patients. **Results:** 756 RT-PCR confirmed COVID-19 patients were included in our study who had initial CXR. 510 (67.46%) of our patients with positive initial RT-PCR showed abnormal baseline CXR. The abnormal findings were described as haziness akin to ground glass opacities (GGO) on CT, peripheral opacities, patchy parenchymal opacities and consolidation. Peripheral opacities and lower zone distribution were the commonest pattern of CXR abnormalities with bilateral involvement. The severity of findings on serial CXR and radiographic regression was studied along with follow-up to assess response to treatment. Forty-six patients showed features of acute lung injury (ALI). Complications and new CXR findings were reported for patients who were given ventilator support. **Conclusion:** CXR is a valuable baseline radiological investigation on hospital admission in symptomatic patients with suspected or confirmed Covid-19 presenting to the EMS as it helps to monitor the progress and regression of the disease in conjunction with clinical findings.

Key words: Acute lung injury; Covid-19 pneumonia; ventilator-associated pneumonia

Introduction

The chest X-ray is usually the initial and often only investigation required in the evaluation of diseases of the

This is an open access journal, and articles are distributed under the terms of the Creative Commons Attribution-NonCommercial-ShareAlike 4.0 License, which allows others to remix, tweak, and build upon the work non-commercially, as long as appropriate credit is given and the new creations are licensed under the identical terms.

For reprints contact: WKHLRPMedknow_reprints@wolterskluwer.com

Cite this article as: Kohli A, Hande PC, Chugh S. Role of chest radiography in the management of COVID-19 pneumonia: An overview and correlation with pathophysiologic changes. Indian J Radiol Imaging 2021;31:S70-9.

Received: 24-Dec-2020

Revised: 31-Dec-2020

Accepted: 31-Dec-2020

Published: 23-Jan-2021

Access this article online

Quick Response Code:



Website:
www.ijri.org

DOI:
10.4103/ijri.IJRI_967_20

chest. The world is gripped by a pandemic caused by SARS COV -2 virus which results in a lower respiratory tract viral pneumonia termed as Covid-19 pneumonia. The clinical symptoms of the disease are nonspecific presenting with influenza-like illness (ILI) with fever >38 degrees C, cough associated with malaise, generalised myalgia, headache and breathlessness. However, patients with Severe Acute Respiratory Infection (SARI) are advised hospitalisation as per WHO recommendation. Real-time polymerase chain reaction (RT-PCR) is the standard accepted test in the diagnosis of COVID-19 to detect the nucleic acid of the virus.

The role of chest radiography in the management of COVID-19 pneumonia was evaluated in a retrospective study at a Multi Speciality Hospital in Mumbai.

Materials and Methods

Consecutive individuals who tested RTPCR positive for SARS COV2 and underwent chest X-rays were collated during their stay in the hospital.

The initial radiograph was evaluated as negative or positive, if positive the type of abnormality, its location, distribution, any other features of note such as cavitation, mediastinal adenopathy, pleural effusion. Note was also made if CT was performed at time of initial X-ray, if so whether positive or negative.

Patients who had more than one X-ray were followed up, a note was made of the progression, regression of abnormalities, number of days to reach progression, number of days to regression either from initial X-ray or after peak of progression. Number which had complications such as ARDS, barotrauma, type of barotrauma, ventilator-associated pneumonia were recorded.

Results

The observations were recorded for total of 756 cases as shown in Table 1.

Discussion

SARS COV-2 has a particular affinity for ACE-2 receptors. These are in abundance in type 2 alveolar cells. After gaining entry into the type 2 receptor cells there is diffuse alveolar damage resulting in exudation into the alveolar spaces.^[1,2]

This appears on Chest radiographs X-rays as a diffuse haziness obscuring vascular markings, akin to the well documented ground-glass densities seen on CT scans.^[3] With further progression in alveolar cell apoptosis the exudation may result in denser opacities on the X-ray appearing as consolidations. These consolidations do not incite sympathetic effusions or internal cavitation as may occur with bacterial

Table 1: RT-PCR positive patients

	Total (N)756	100%
RTPCR positive patients with normal X-ray	246	33%
RTPCR positive patients with abnormal X-ray	510	67%
Total HRCT done	390	52%
Abnormal HRCT	350	90%
Abnormal X-ray abnormal HRCT	258	73%
Normal X-ray abnormal HRCT	92	26%
X-ray showing only peripheral opacities	180	35%
X-ray showing both central and peripheral opacities	330	65%
X-ray showing haziness (GGO)	160	31%
X-ray showing consolidation	350	69%
Unilateral-right lung involvement	115	23%
Unilateral-left lung involvement	80	16%
Bilateral lung involvement	315	61%
Patients showing progression on serial X-ray	132	26%
X-rays showing upper half involvement	153	30%
X-rays showing lower half involvement	357	70%
First normal x-ray which showed progression in due course of time	17	7%
Abnormal first X-ray showing progression	115	23%
Average days of progression	6.4	
Total patients showing regression	124	24%
Average days of regression	10	
Total number of patients which developed acute lung injury (ALI)	46	9%
Patients that presented with ALI	14	3%
Patients that progressed to ALI	32	6%
Patients that regressed from ALI	24	52%
Total patients developing barotrauma during hospital stay	18	2%
Total expired patients	31	4%
Total invasive ventilation patients	29	4%
Total non-invasive ventilation patients	12	1.5%

pneumonias. Occasionally reticular opacities may be seen on the X-ray as linear bands due to septal/alveolar thickening due to inflammation. The distribution of abnormalities is usually in the lung bases as well as in the periphery.^[1,2] [Figures 1-12].

A negative chest X-ray may be due to lack of lung involvement, early in the disease, subtle involvement below resolution of X-rays or technical factors.^[4] [Figure 13].

In our study 67% of patients with positive RTPCR had abnormalities on the chest X-ray. 33% were negative. Chest radiograph was negative in 26% of positive HRCT indicating CT is far more sensitive than chest X-ray in detecting COVID 19 pneumonia. The distribution of abnormalities were predominantly in the lower zone (70%) bilateral (61%) and peripheral and central in location (65%) The type of abnormality was predominantly consolidation (68%). These findings were consistent with smaller cohorts reported earlier.^[5-7]

The diffuse alveolar damage evolves over 1-3 weeks resulting in temporal changes on imaging. There are 3 stages of diffuse alveolar damage.^[6]

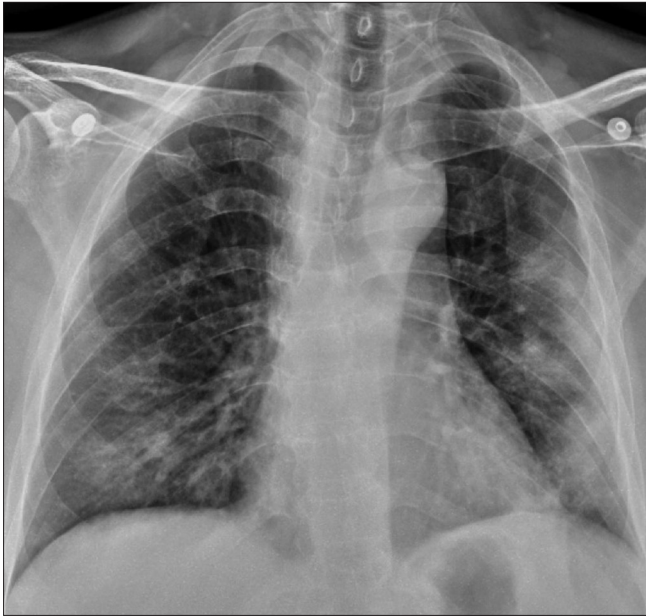


Figure 1: Chest radiograph PA view of RT-PCR proven COVID positive patient showing patchy opacities in bilateral mid and lower zones predominantly involving the peripheral lung fields (left more than right)

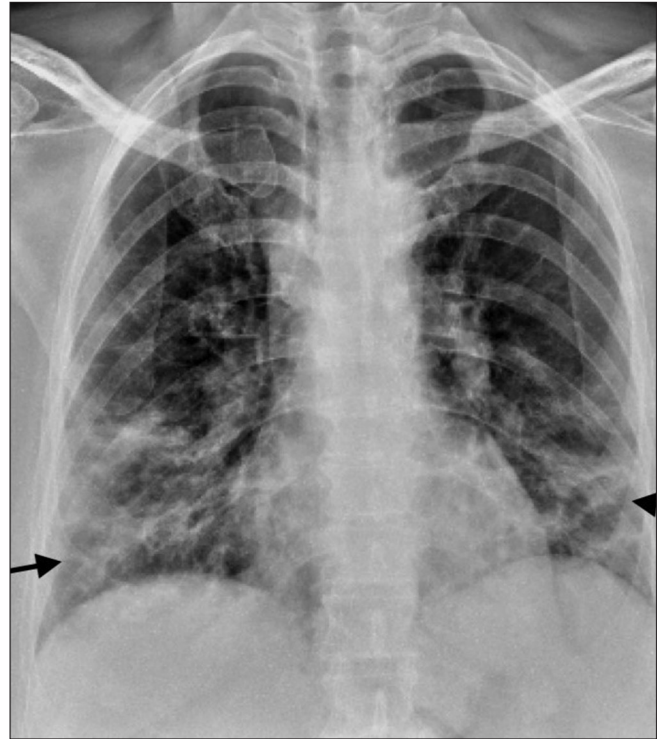


Figure 2: Chest radiograph PA view of RT-PCR proven COVID positive patient showing ill-defined air space consolidations with reticular opacities (black arrows) in bilateral mid and lower zones

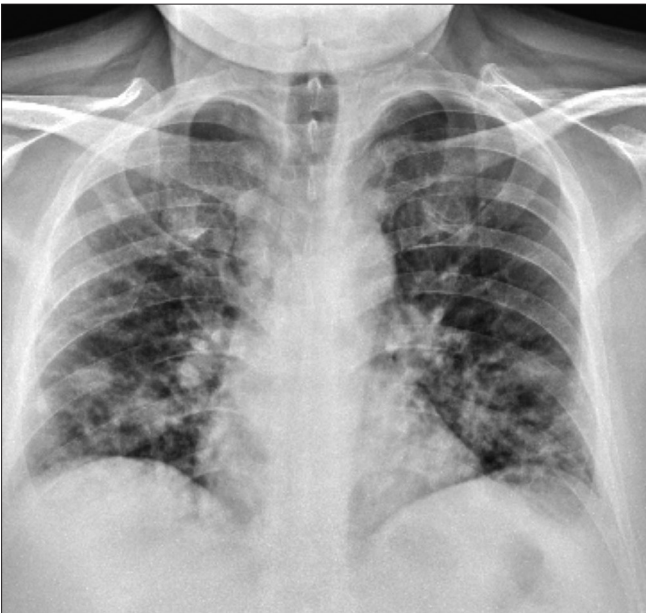


Figure 3: Chest radiograph of a COVID positive patient showing patchy nodular lesions in bilateral mid and lower zones representing atypical appearance

Stage 1 is the exudative phase which occurs in the first few days after infection, usually till day 4/5. There is limited leakage of fluid into the interstitium as a result radiographs demonstrate essentially clear lung fields.

Stage II is an inflammatory stage where there is an alveolar capillary leak of protein, fluid resulting in diffuse alveolar opacities predominantly in the peripheral portions of the lungs. With increasing capillary leak diffuse alveolar damage may progress with extensive lung involvement

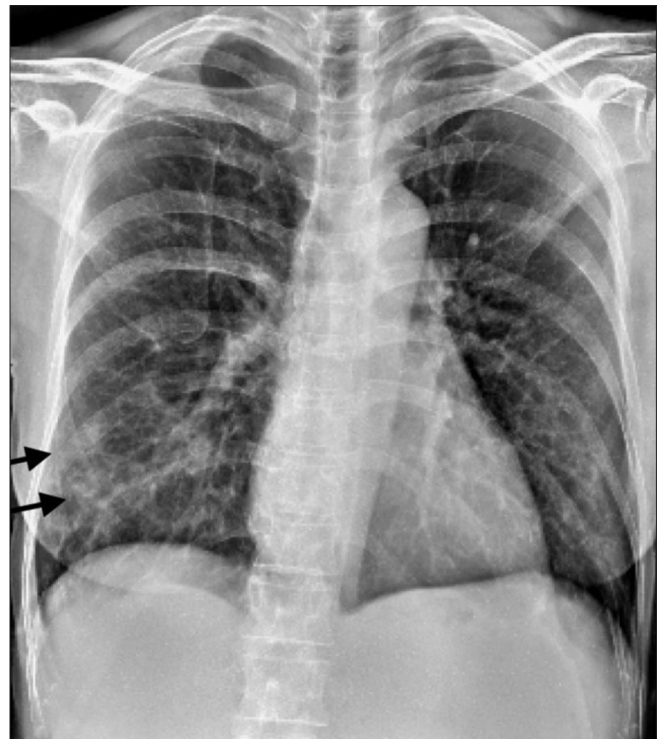


Figure 4: Chest radiograph of COVID positive patient proven by RT-PCR showing subtle hazy opacities (black arrow) in right lower zone

resulting in Acute Respiratory Distress Syndrome (ARDS). This results in loss of aerated lung tissue, impaired gas exchange, hypoxia. opacities tend to become confluent,

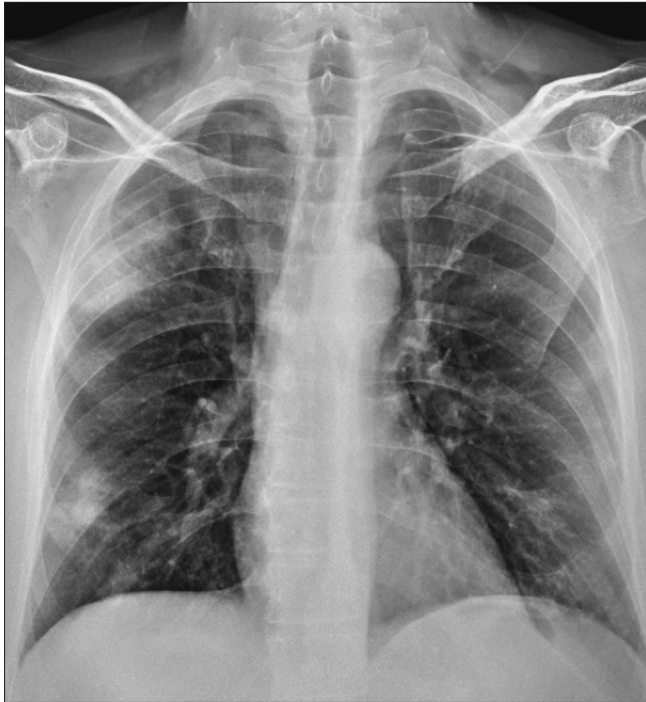

Figure 5: Chest radiograph of COVID positive patient proven by RT-PCR shows dense airspace consolidation in subpleural region of right upper and lower zones

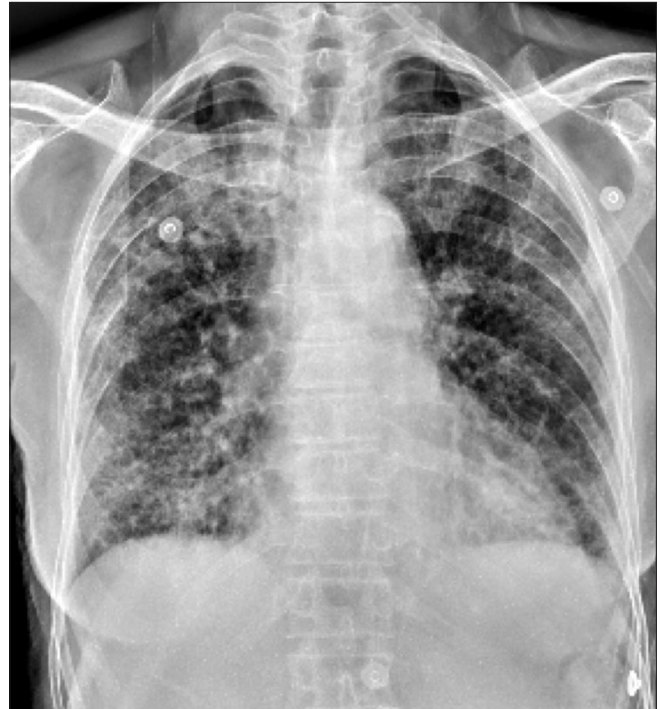


Figure 6: Chest radiograph of COVID positive patient proven on RT-PCR shows small nodular consolidations involving both lung fields representing broncho-pneumonia pattern

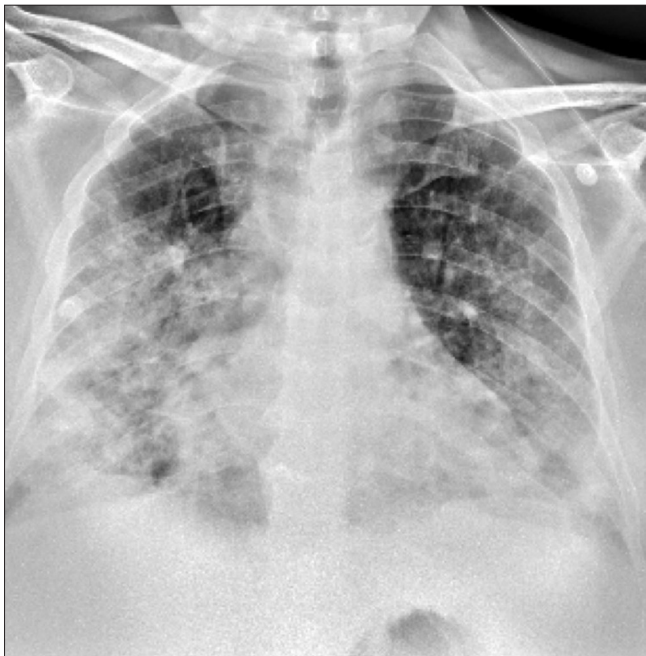


Figure 7: Chest radiograph in a Covid positive patient proven on RT-PCR reveals diffuse airspace consolidation in bilateral mid and lower zones (right more than left lung)

lungs become totally opaque, air bronchograms may be present with injury to alveolar cells, there is decreased surfactant production and decreased lung compliance. This is reflected in the radiographic findings of relatively small lung volumes and atelectasis. Rarely there are associated pleural effusions; these are usually small if present. At

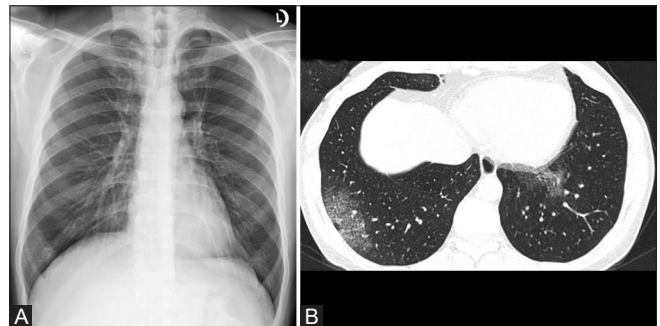


Figure 8 (A and B): (A) Chest radiograph of a RT-PCR proven COVID positive patient shows no abnormality. (B) HRCT chest was done on same day as patient was symptomatic revealed patchy areas of ground glass densities with interlobular septal thickening in posterior basal segment of right lower lobe and medial basal segment of left lower lobe

this juncture it is important to differentiate cardiogenic, overhydration oedema from the alveolar oedema of ARDS. The alveolar oedema of ARDS is not accompanied by widening of the vascular pedicle, cardiomegaly, altered pulmonary blood flow distribution, pleural effusions and septal lines. In fact if the pulmonary vessels can be distinguished they are often constricted in size. The opacities tend to be in the periphery as compared to central in cardiogenic oedema as well as don't change temporally as they do on cardiogenic oedema. In our study 9% of patients progressed to ARDS.^[4] [Figures 14 and 15].

Stage III is a fibro-proliferative phase, in this phase there is proliferation of epithelial cells and fibroblasts with collagen

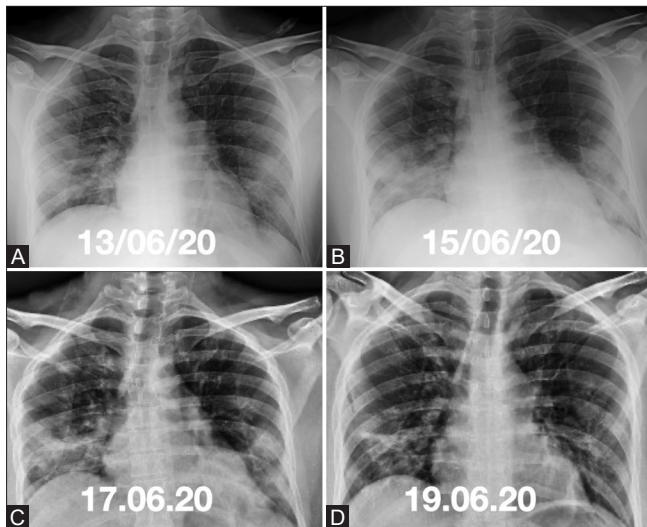


Figure 9 (A-D): Serial chest radiographs over 7 days in a patient with Covid-19 infection depicting (A-C) progression of the disease in the first 3 days with (D) gradual resolution of opacities over the next 4 days

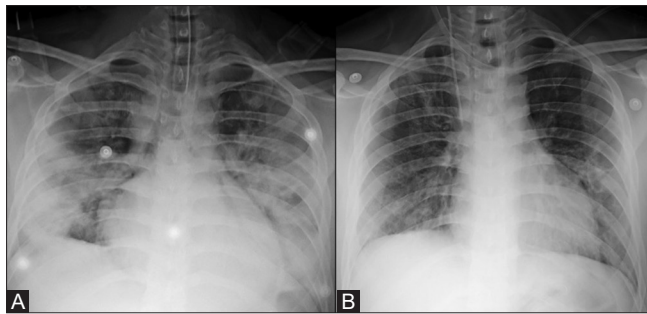


Figure 11 (A and B): Serial chest radiographs at 7 days interval in a patient with Covid-19 infection showing resolution of the diffuse consolidation involving the bilateral mid and lower zones in Chest X-ray (A)

deposition. A transition from alveolar to interstitial opacities is noted.

The radiographic appearances are of progressive clearing of alveolar opacities which are replaced by reticular opacities. In the chronic phase the radiograph often returns to normal, occasionally residual fibrosis or cystic changes may be present.

The main complication of COVID-19 pneumonia is the development of ARDS.

The mainstay of treatment of ARDS is to recruit the alveoli in the atelectic/consolidated portions of the lung by using high positive end expiratory pressures via mechanical ventilation. This distends the alveoli. An effort to recruit the consolidated atelectic portions can result in over distension of these alveoli and consequently barotrauma due to rupture of alveoli. The radiologist has an extremely important role to play in the detection, prevention and treatment of these complications.

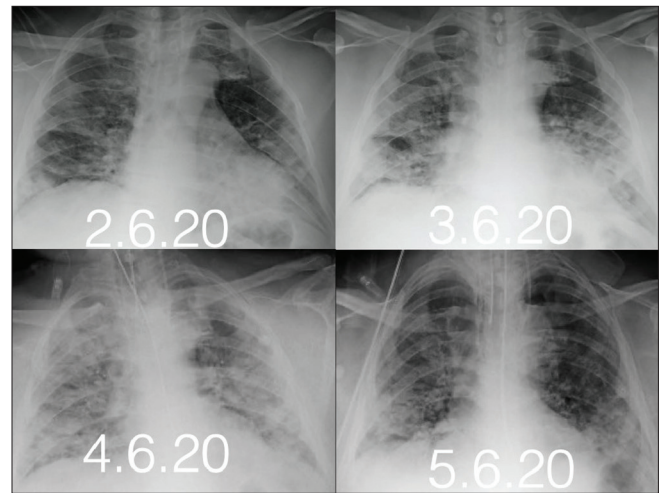


Figure 10: Serial chest radiographs over 4 days in a patient with Covid-19 infection showing progression of the disease for which patient was intubated. Follow-up radiograph demonstrates resolution on the 4th day

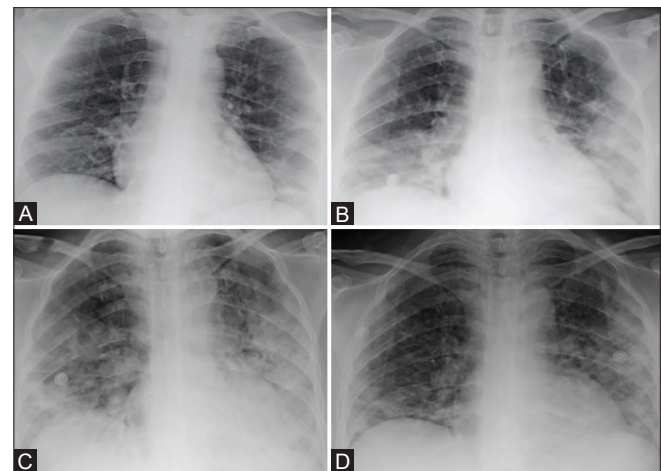


Figure 12 (A-D): Serial chest radiographs in RT-PCR proven COVID positive patient showing progression of the ill-defined hazy opacities noted in right lower zone (A) with increase in densities of opacities and involvement of bilateral mid lower zones (B and C) and gradual regression in the densities of these opacities noted in last chest X-ray (D)

The adverse effects of Positive pressure ventilation can be classified into 2 groups

- 1) Due to physiological effects of mechanical ventilation on heart/pulmonary vasculature
- 2) Direct lung injury resulting in Air leak phenomena.

During the acute phase the use of positive end expiratory pressure may result in improvement of the chest radiograph appearances, such as clearing of previously visualised opacities. This infact is a paradox as the positive end expiratory pressure causes overdistension of the alveoli resulting in the apparent clearing of opacities on the chest X-ray. This overdistension of the alveoli actually results in diversion of pulmonary blood flow to the poorly ventilated regions resulting in paradoxical worsening of the oxygenation.

Air leak phenomena

This is the most commonly recognised manifestation of barotrauma, the development of extra alveolar air collections which may accumulate in five compartments, the pleural space, mediastinum, interstitium, pericardial sac and subcutaneous tissues. Although each area has distinct radiological features, overlap exists and occasionally differentiation can be difficult. 2% of all patients developed barotrauma, in our study 40% of patients mechanically ventilated developed barotrauma [Figures 16-19]. As compared with reported overall rate of 24 % in a study by McGuinness *et al* in patients with COVID-19 on invasive mechanical ventilation^[8] [Figures 16-19].

Pulmonary interstitial emphysema

This occurs due to rupture of alveoli with resultant leak of air into the interstitium, interstitial emphysema. This air then dissects along the vascular sheaths and interlobular septae, paths of least resistance, centrally to the hilum. resulting in a pneumomediastinum. and peripherally to the pleura resulting in a pneumothorax. Pulmonary interstitial emphysema is difficult to observe on radiographs as the air in the interstitium is difficult to detect against the background of dark alveolar air. Pulmonary interstitial emphysema becomes much easier to detect in a consolidated lung as the consolidation contrasts the air in the interstitium.

The earliest radiographic signs are a mottled increase in the radio-lucency of the lung anteriorly and medially around the heart, as well as the diaphragmatic surface. There may be streaky linear radiolucencies radiating from the hila to the periphery of the lung. These may resemble air bronchograms, they however differ from air bronchograms by the fact that they do not branch nor do they taper to the periphery.^[9]

They may form pneumatoceles which may coalesce to form large subpleural cysts.

Pneumomediastinum

The mediastinum is anatomically defined as the space between the two lungs, it is enveloped all round by parietal pleura. It contains two air filled structures, the trachea and the oesophagus. Any air outside these structures is pathological. As the air collects around the mediastinal structures, the great vessels, the cardiac contour is demarcated extremely well. Streaky vertically oriented opacities may be visualised extending superiorly into the neck. Normally the infracardiac surface of the diaphragm is not visualised, this is as the density of the cardiac structures and diaphragm are similar. In a pneumomediastinum air dissects inferiorly into the infracardiac region, separating the cardiac and diaphragmatic densities producing a continuous

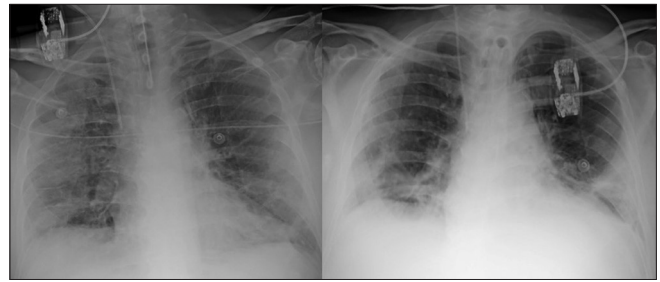


Figure 13: Serial chest radiographs in a patient on mechanical ventilation. Diffuse airspace consolidation involving right lung field and left mid and lower zone. There is resolution of the opacities visualised in right upper and bilateral mid zones

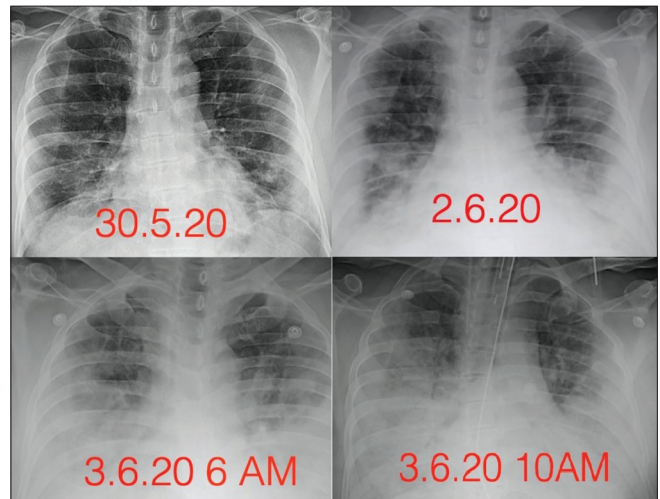


Figure 14: Serial chest radiographs over 5 days in a case with COVID pneumonia showing progression of density and area of airspace opacities. Patient was intubated on the 5th day and unfortunately expired one day later

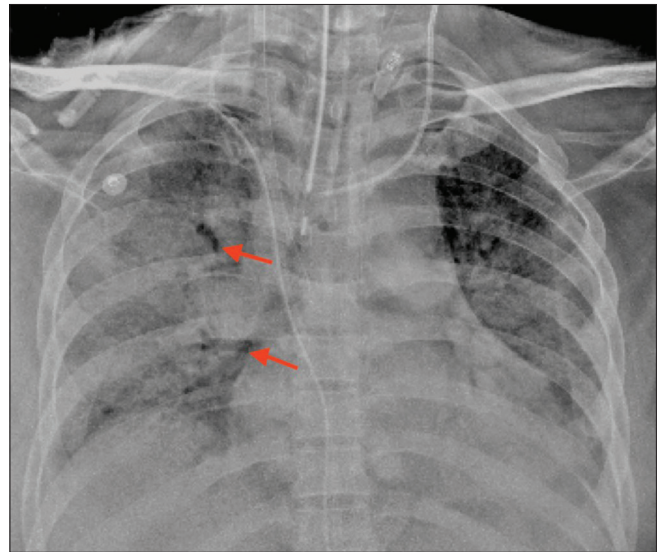


Figure 15: Portable chest radiograph of COVID pneumonia patient with diffuse airspace opacities in bilateral lung fields with relative sparing of left upper zone. Patient was intubated and put on positive ventilation because of diffuse lung involvement. Linear lucencies in right mid zone (red arrow) representing pulmonary interstitial emphysema

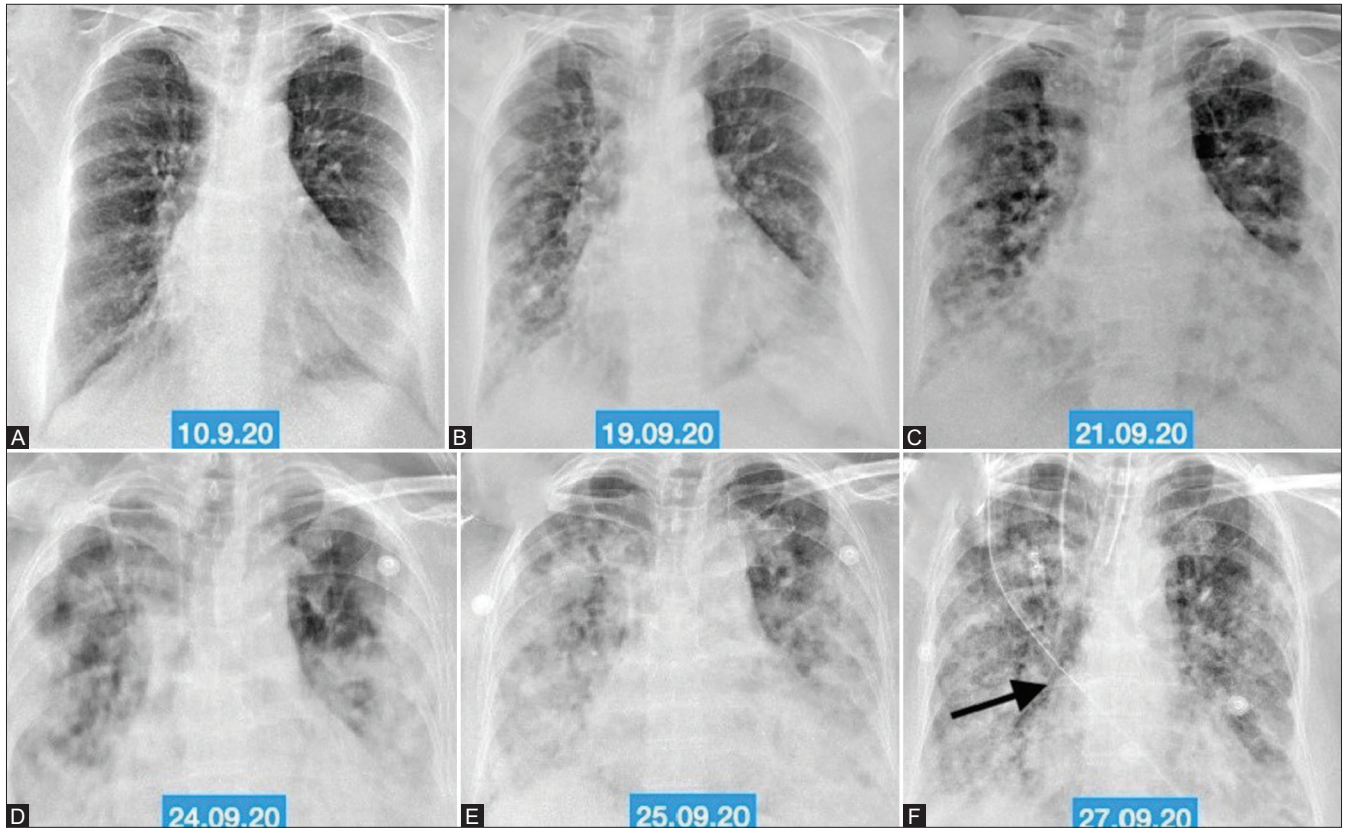


Figure 16 (A-F): Serial chest radiographs (A-F) in a COVID positive patient who presented with acute breathlessness. (A) Normal initial OPD Chest radiograph. (B-F) Subsequent Chest radiographs show progression of the patchy ground glass opacities to diffuse consolidation for which patient required ventilatory support. (F) Mediastinal emphysema (black arrow) is noted as a result of barotrauma

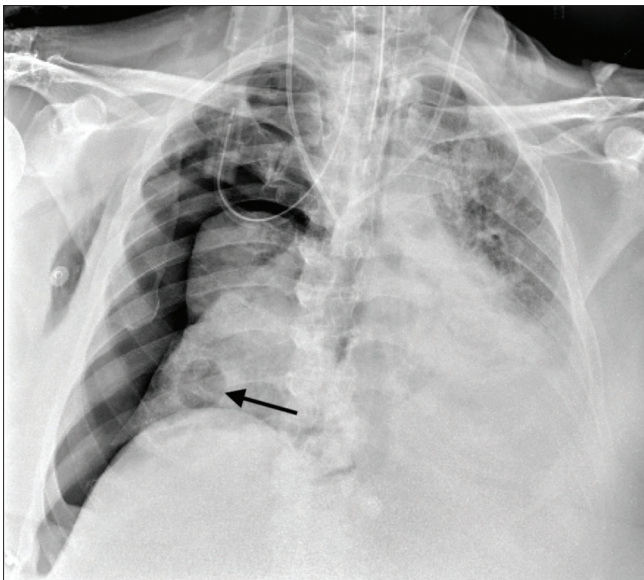


Figure 17: Portable chest X-ray of a COVID pneumonia patient with bilateral diffuse involvement of lungs developed right-sided pneumothorax with collapse of underlying right lung and mediastinal shift towards left due to barotrauma. Incidentally noted is a well-defined oval radiolucency representing a pneumatocele in right lower zone (black arrow)

diaphragm sign. The diaphragm is seen in its entire extent. The mediastinal pleura may be visualised as a thin line surrounding the mediastinal air.^[10,11]

Pneumothorax

This is the most common life threatening emergency in patients supported by mechanical ventilation. Pneumothorax usually follows the development of pneumomediastinum. The relatively thin mediastinal pleura ruptures when overdistended with air. Once a pneumothorax develops in a patient on the ventilator it may rapidly increase in size to become a tension pneumothorax.^[11,12]

The most important radiographic feature of a pneumothorax is the presence of a thin white line representing the visceral pleura with air on both sides of this white line, air in the pleural space and air in the lung parenchyma. Other signs are absence of lung markings beyond the visceral pleural line and hypertranslucency of the pleural space. Unfortunately, in most patients with suspected barotrauma only supine X-rays are possible. In these situations detection of a pneumothorax may be difficult and the signs are different. The principles are the same, air collects in a nondependent location such as the antero-medial or subpulmonary location, when the air leak is large, air may collect in the apicolateral location. The displaced visceral pleural line is difficult to demonstrate on a supine radiograph X-ray. In the absence of this specific sign secondary signs to demonstrate the collection of extrapleural air is important. As air collects in

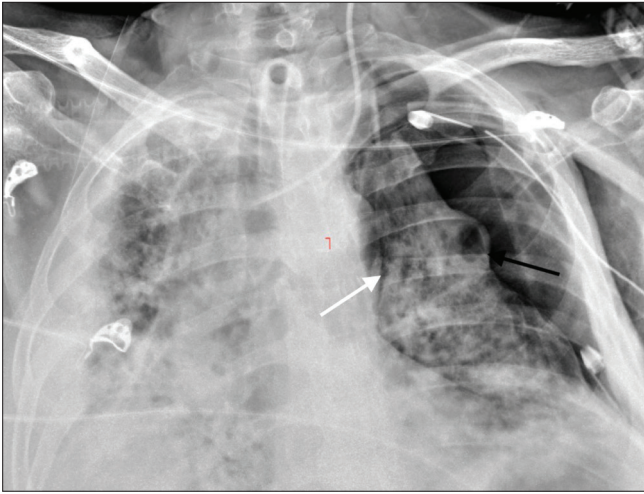


Figure 18: Portable Chest radiograph after chest tube insertion in Covid positive patient with bilateral diffuse air space consolidation requiring positive pressure ventilation developed left sided pneumothorax likely due to barotrauma resulting in collapse of the underlying left lung and mediastinal shift towards right. A well-defined oval radiolucency in periphery of left mid zone representing a pneumatocele (black arrow) with linear radiolucencies in left mid and lower zones around heart representing pulmonary interstitial emphysema

the anterior costophrenic sulcus there is transradiancy in the hypochondrial region overlying the diaphragm. There is increased sharpness of adjacent mediastinal margin and diaphragm. The costophrenic sulcus becomes deep with a well-defined margin. The inferior edge of collapsed lung becomes visible. Ipsilateral hemidiaphragm is depressed. Cardiac margins become sharp and pericardial fat pads become well outlined. A pneumothorax suspected on a supine film can be confirmed on a cross table lateral view or lateral decubitus with suspect side uppermost. If there is any doubt, CT chest is very useful, as it would be confirmatory.

Skin folds may mimic the white line of displaced pleura. Skin folds are often in pairs as well as often cross the midline, diaphragm or chest wall. Lines or tubes projecting over the lung may also simulate the white visceral pleural line. In these cases, the other signs of a pneumothorax are absent and the appliances can be seen exiting the confines of the thoracic cage.^[13]

A pneumothorax is considered under tension when the pressure in the pleural space exceeds atmospheric pressure. The ipsilateral lung collapses with mediastinal shift, especially displacement of the azygo oesophageal recess. There may also be evidence of inversion of the diaphragm and flattening of the heart especially the IVC and SVC impairing normal venous return to the right heart.^[14]

Pneumothorax is treated by placing a thoracic tube. If there is only air in the pleural space, the thoracic tube is placed anteriorly in the second intercostal space, if there is

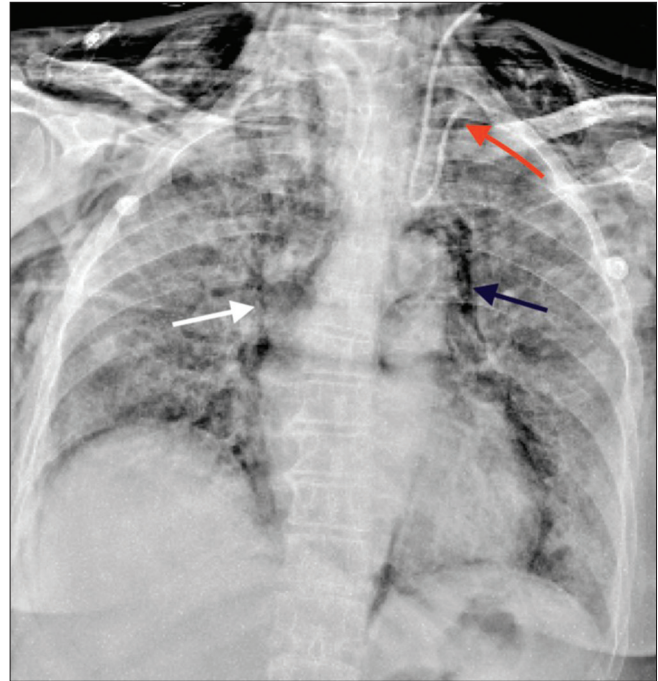


Figure 19: Portable chest X-ray in a Covid pneumonia patient on mechanical ventilation developed mediastinal emphysema (black arrow) and diffuse subcutaneous emphysema as a result of barotrauma. Linear radiolucencies noted in right mid zone representing pulmonary interstitial emphysema. Incidentally noted is central line coiled back in left IJV (red arrow)

a mixture of air and fluid then the tube is placed in the sixth or seventh interspace in the mid axillary line.

Subcutaneous emphysema

Air can dissect along the fascial planes of the neck, chest and abdominal walls from the mediastinum or pleura. Often the presence of air in the chest wall in a patient on mechanical ventilation is the first sign of barotrauma. Due to the presence of subcutaneous emphysema, pneumothorax or underlying parenchymal abnormalities may not be detected on the chest radiograph. Rarely subcutaneous emphysema may be due to a necrotising soft tissue infection. Radiographically multiple lucencies of varying configurations may be seen within the soft tissues of the neck and thorax. Subcutaneous emphysema present is of little clinical significance.

Ventilator-associated pneumonia

Due to the immunosuppressed state of critically ill patients bacteria colonise in the endotracheal/tracheostomy tube. The endotracheal or tracheostomy tube allows free passage of bacteria into the lower segments of the lung, thus these may be imbibed into the lungs with each breath, also they may be propelled down by suctioning and bronchoscopy.^[15,16] This results in an infectious pneumonia. The key to the diagnosis is the presence of new opacities, especially cavitation, pleural effusions. Clinical and laboratory parameters support the diagnosis. On chest X-ray these may be difficult to demonstrate on the

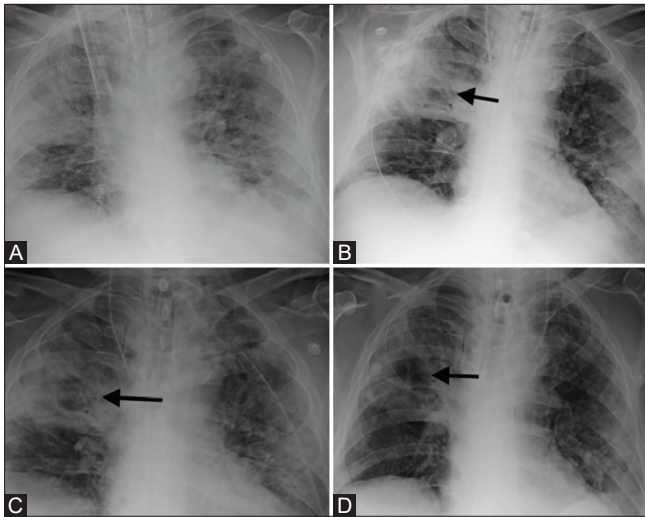


Figure 20 (A-D): Serial portable chest radiographs in a Covid positive patient requiring mechanical ventilation, showing (A) dense consolidation in right upper and mid zone (this was a new finding as compared to old X-rays). (B-D) shows cavitation in dense consolidation. Endotracheal tube swab (ETS) grew *Acinetobacter Baumannii* on culture. Pneumonia resolved on appropriate antibiotic therapy as shown in follow up chest X-rays

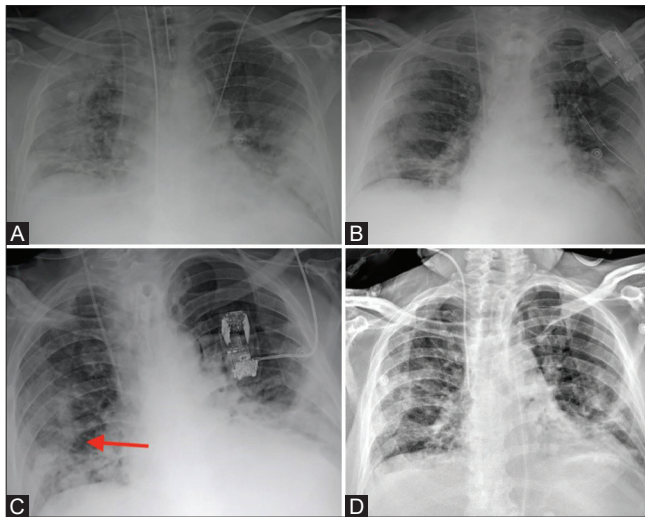


Figure 21 (A-D): Serial portable chest radiographs in a Covid positive patient. (A) showing airspace consolidation in right lung and left mid and lower zone (B) resolution in the density and extent of airspace consolidation in right lung field and left mid zone (C) ill-defined consolidation in right mid and lower zone (new finding-red arrow). Microbiological investigations revealed *Acinetobacter Baumannii* on culture (D) shows resolution of extent and density of opacities noted in right mid and lower zones after appropriate antibiotic treatment

background of white out lung. [Figures 20 and 21]. In our study 2/29 (7%) patients on invasive/mechanical ventilation developed-associated pneumonia.

Conclusion

The chest X-ray is an important diagnostic tool in the detection and management of Covid-19 pneumonia.

Chest X-ray is useful tool to detect changes to suggest the diagnosis, CT chest however has a higher sensitivity. The common CT findings of bilateral involvement, peripheral distribution, and predominantly in lower zones were also appreciated on CXR which was commensurate with other studies.^[1,5,17] Portable CXR being a bedside modality can be used to monitor the progression, regression of lung changes, complications in the form of ARDS, barotrauma, ventilator-associated pneumonia and misplaced tubes and lines helping reduce the morbidity and mortality.

This has been included in WHO guidelines for the use of chest imaging in Covid-19 of 11 Jun 2020 which gives conditional recommendation (R2.2) to use CXR for the diagnosis in symptomatic cases as it can be performed with portable equipment at the point of care which reduces the risk of cross-infection.^[18]

Financial support and sponsorship

Nil.

Conflicts of interest

There are no conflicts of interest.

References

- Jacobi A, Chung M, Bernheim A, Eber C. Portable chest X-ray in coronavirus disease-19 (COVID-19): A pictorial review. *Clin Imaging* 2020;64:35-42.
- Cevik M, Kuppalli K, Kindrachuk J, Peiris M. Virology, transmission, and pathogenesis of SARS-CoV-2. *BMJ* 2020;371:m3862. doi: 10.1136/bmj.m3862.
- Rodrigues JC, Hare SS, Edey A, Devaraj A, Jacob J, Johnstone A, *et al.* An update on COVID-19 for the radiologist-A British society of Thoracic Imaging statement. *Clin Radiol* 2020;75:323-5.
- Tang X, Du R, Wang R, Cao TZ, Guan LL, Yang CQ, *et al.* Comparison of hospitalized patients with ARDS caused by covid-19 and H1N1. *Chest* 2020;158(1):195-205.
- Wong HY, Lam HY, Fong AH, Leung ST, Chin TW, Lo CS, *et al.* Frequency and distribution of chest radiographic findings in COVID-19 positive patients. *Radiology* 2020;201160. Vol. 296, No. 2
- Yasin R, Gouda W. Chest X-ray findings monitoring COVID-19 disease course and severity. *Egypt J Radiol Nucl Med* 2020;51:1-8.
- Durrani M, Inam ul Haq UK, Yousaf A. Chest X-rays findings in COVID 19 patients at an University Teaching Hospital-A descriptive study. *Pak J Med Sci* 2020;36:S22.
- McGuinness G, Zhan C, Rosenberg N, Azour L, Wickstrom M, Mason DM, *et al.* Increased incidence of barotrauma in patients with COVID-19 on invasive mechanical ventilation. *Radiology* 2020;297:E252-62.
- Sherrin PB, Jovaisa T. Pulmonary interstitial emphysema presenting in a woman on the intensive care unit: Case report and review of literature. *J Med Case Reports* 2011;236.2011 Dec 1;5(1):236
- Kouritas VK, Papagiannopoulos K, Lazaridis G, Baka S, Mpoukovinas I, Karavasilis V, *et al.* Pneumomediastinum. *J Thorac Dis* 2015;7(Suppl 1):S44.
- Sun R, Liu H, Wang X. Mediastinal emphysema, Giant Bulla, and pneumothorax developed during the course of COVID-19 pneumonia. *Korean J Radiol* 2020;21:541-4.

12. Hsu CW, Sun SF. Iatrogenic pneumothorax related to mechanical ventilation. *World J Crit Care Med* 2014;3:8-14.
13. O'connor AR, Morgan WE. Radiological review of pneumothorax. *BMJ* 2005;330:1493-7.
14. Jalota R, Sayad E. Tension pneumothorax. *Stat Pearls* [Internet] 2020 Jul 6.
15. Chastre J, Fagon JY. Ventilator-associated pneumonia. *Am J Respir Crit Care Med* American Journal of respiratory and critical care medicine. 2002;165(7):867-903.
16. Magill SS, Li Q, Gross C, Dudeck M, Allen-Bridson K, Edwards JR. Incidence and characteristics of ventilator-associated events reported to the National Healthcare Safety Network in 2014. *Crit Care Med* 2016;44:2154-62.
17. Salehi S, Abedi A, Balakrishnan S, Gholamrezanezhad A. Coronavirus disease 2019 (COVID-19): A systematic review of imaging findings in 919 patients. *AJR Am J Roentgenol* 2020;215:87-93. 2020;215(1):87-93 doi: 10.2214/AJR.20.23034. Epub 2020 Mar 14. PMID: 32174129.
18. WHO/2019-nCoV/Clinical/Radiology/Radiology_imaging/2020.1.