

## Original Article

## Role of Colonoscopy in Differentiating Intestinal Tuberculosis from Crohn's Disease

P. Rajesh Prabhu, Mayank Jain<sup>1</sup>, Piyush Bawane<sup>1</sup>, Joy Varghese<sup>1</sup>, Jayanthi Venkataraman<sup>1</sup>

Department of Gastroenterology, Stanley Medical College, <sup>1</sup>Department of Gastroenterology and Hepatology, Gleneagles Global Health City, Chennai, Tamil Nadu, India

## ABSTRACT

**Background:** The interface between tuberculosis (TB) and Crohn's disease (CD) is relevant as TB complicates both the diagnosis and management of CD. **Aim:** This study aimed to identify the distinctive characteristics of ileocaecal and colonic TB (C-TB) and colonic CD (C-CD) at colonoscopy and to correlate the colonoscopy findings with histology. **Materials and Methods:** This prospective study included consecutive patients presenting with classical symptoms of TB or CD. The colonoscopic findings were compared with histology, which was taken as gold standard. Appropriate statistical tests were applied. **Results:** Fifty-eight individuals fulfilled the inclusion criteria. Nine and 16 patients with C-TB and C-CD, respectively, had histological confirmation of respective diagnosis. In 33 specimens, the histological diagnosis was inconclusive. The sensitivity of colonoscopy for diagnosing C-TB was high at 88.9% (95% confidence interval [CI]: 51.8–99.7). It was 50% (95% CI: 24.7–75.4) for CD. The reverse was true for CD whose specificity was high at 71.4% (95% CI: 55.3–84.3) and low for TB at 46.9% (95% CI: 32.5–61.7). All the patients diagnosed as confirmed CD or TB responded well to respective treatment. Six of the thirty patients with failed response to anti-TB treatment required surgery or change in treatment after 2 months. **Conclusion:** Colonoscopic findings of isolated ileal involvement, aphthous ulcer, cobble stoning, long-segment strictures, skip lesions and perianal involvement favored a diagnosis of CD. Correlation of colonoscopy with histology is poor for both CD and TB. The accuracy, sensitivity and specificity of colonoscopy were better and superior for the diagnosis of CD, than in the diagnosis of TB.

**KEYWORDS:** *Diagnosis, endoscopy, pathology*

## INTRODUCTION

Tuberculosis (TB) epidemic is expanding and currently a third of the world's population is infected, the majority residing in the developing world.<sup>[1]</sup> The epidemiology of inflammatory bowel disease is also changing, though far less dramatically, with more cases being reported from low- and middle-income countries. There exists a multifaceted relationship between intestinal TB (ITB) and Crohn's disease (CD), as they share common pathogenic and clinical characteristics. The interface between these two diseases is particularly relevant in the developing world where TB complicates both the diagnosis and management of CD.

The present study aimed to identify the distinctive characteristics of ileocaecal and colonic TB (C-TB) and colonic CD (C-CD) at colonoscopy and to correlate the colonoscopic findings with histology.

## MATERIALS AND METHODS

This prospective study was undertaken in the Department of Gastroenterology at Stanley Medical College, Chennai, a tertiary referral center in Tamil Nadu,

**Address for correspondence:** Dr. Jayanthi Venkataraman, Gleneagles Global Health City, Chennai - 600 100, Tamil Nadu, India.  
E-mail: drjayanthi35@yahoo.co.in

This is an open access article distributed under the terms of the Creative Commons Attribution-NonCommercial-ShareAlike 3.0 License, which allows others to remix, tweak, and build upon the work non-commercially, as long as the author is credited and the new creations are licensed under the identical terms.

**For reprints contact:** reprints@medknow.com

**How to cite this article:** Prabhu PR, Jain M, Bawane P, Varghese J, Venkataraman J. Role of colonoscopy in differentiating intestinal tuberculosis from Crohn's disease. *J Dig Endosc* 2017;8:72-7.

## Access this article online

## Quick Response Code:



**Website:** www.jdeonline.in

**DOI:** 10.4103/jde.JDE\_13\_17

between January 2006 and December 2007. Consecutive patients presenting with abdominal pain, chronic mucoid diarrhea, fever, weight loss, altered bowel habits and features of malabsorption, past history of TB with or without treatment, belonging to either sex, age range between 15 and 60 years, with colonoscopy favoring either ileocaecal or C-TB, C-CD, or an overlap between the two (C-unclassified [UC]) were included in the study. No attempt was made to correlate the clinical presentation with either endoscopy or histology.

Polyethylene glycol was used for preparation of the colon. After perianal examination, the entire colon including terminal ileum was screened for mucosal lesions. Fentanyl 50 mcg and injection midazolam 2 mg were used for sedation. Multiple biopsy specimens were taken both from the diseased and normal appearing mucosa, the latter at 10 cm interval from ileum to rectum. This was as per the observations made in a previous study from South India wherein multiple biopsy was recommended from normal mucosa.<sup>[2]</sup> The pathologist was blinded to the colonoscopic findings.

### Colonoscopic diagnosis

a. Ileocaecal/C-TB (Gp I: C-TB): Combination of at least three of the six under mentioned characteristics were noted - isolated ileal or ileocecal (IC) involvement with nodularity and/or IC valve destruction, presence of circumferential ulcers,

- short-segment strictures, and mucosal nodularity in colon with or without pseudopolyps [Figure 1b]
- b. Ileocaecal/C-CD (Gp II: C-CD): Combination of two or more of the five under mentioned criteria: perianal lesions, aphthous or serpiginous ulcers, stellate, fissuring, and deep ulcers of varying sizes with normal intervening mucosa, ileal involvement with preservation of IC valve, skip lesions, long-segment strictures, and cobblestone appearance of the mucosa. Isolated ileocaecal involvement with cobblestone of colonic mucosa was also considered as C-CD [Figure 1a]
- c. Colonoscopic findings were considered as unclassified (Gp III: C-UC) when there was an overlap of four or more findings of C-TB and C-CD.

### Histology

Pulimood's classification<sup>[3]</sup> for TB and CD was used for histological interpretation.

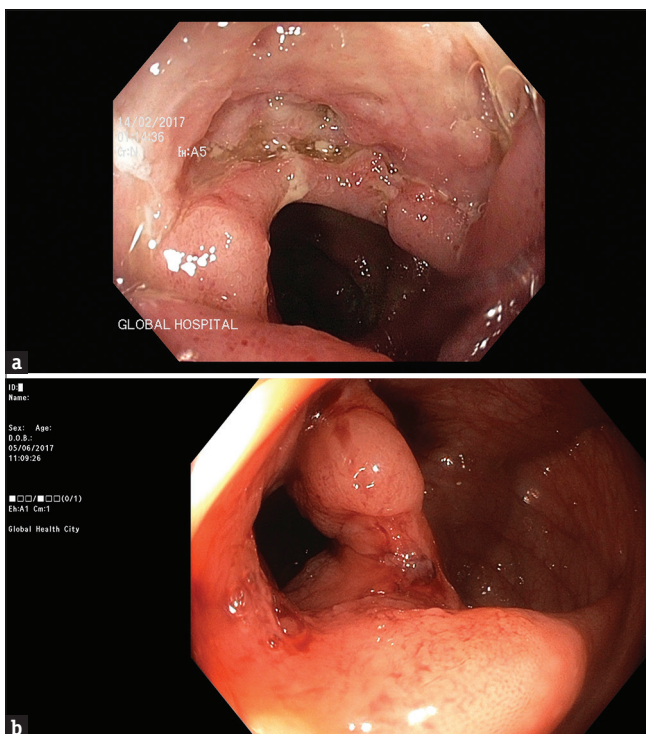
- a. TB (Gp A: histology-TB): Large (>200  $\mu\text{m}$ ) granulomas, caseating, confluent, and multiple with submucosal inflammation and/or presence of epithelioid cells
- b. CD (Gp B: histology-CD): Small (<100  $\mu\text{m}$ ), noncaseating, and solitary granulomas, transmural chronic inflammatory cell response, glandular distortion distant from the site of granulomatous inflammation, and presence of a granulomatous response in normal-appearing mucosa
- c. When the histological report was equivocal, i.e., an overlap of findings, these were reported as histology UC (H-UC).

Diagnosis at histology was considered as the gold standard and was correlated with the colonoscopic diagnosis.

### Follow-up

Histology-confirmed TB and CD patients were treated as per the standard protocol. Patients with IC CD were started on tapering dose of steroids in combination with mesalamine 2.4 g/day. Steroid-dependent patients were started on azathioprine 1.5–2 mg/kg body weight with close monitoring of blood counts and liver function tests. Patients diagnosed as TB were started on four drug regimens (isoniazid 5 mg/kg, rifampicin 10 mg/kg, ethambutol 15 mg/kg, and pyrazinamide 25 mg/kg) for 8 weeks along with pyridoxine 40 mg once a day for the first 2 months. Subsequently, patients were continued on isoniazid 300 mg once a day in combination with rifampicin 450 mg once a day for further 4 months. All patients were monitored with liver function tests at every other week until completion of treatment.

Those in whom the histology remained unclassified, the treatment was tailored to the endoscopic diagnosis. Patients



**Figure 1:** (a) Deep, fissuring ulcer in Crohn's disease - representative picture. (b) Patulous ileocecal valve with ulceration in tuberculosis - representative picture

in whom diagnosis was noninformative both at endoscopy and histology were reviewed 3 months later for progression of the disease and decision regarding further treatment.

The primary end point of the study was histological correlation with colonoscopic diagnosis. Secondary end point was the response to treatment for CD and TB.

### Exclusion criteria

These included patients at extremes of age (<14 years, >60 years), known case of IC/C-TB or CD on treatment and follow-up, CD or TB lesions elsewhere in the gastrointestinal tract, ischemic bowel disease, radiation-induced injury, and diverticular disease of the colon.

Ethics Committee approval of the institution (Stanley Medical College Hospital) was obtained prior to the initiation of the study. Ethical principles as dictated by the Declaration of Helsinki, which provide guidance to physicians and other participants in medical research involving humans, were strictly followed.

### Statistical analysis

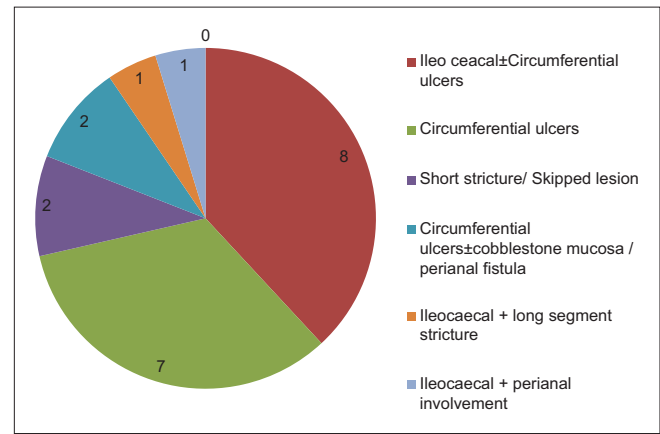
The sensitivity, specificity, positive and negative predictive values were calculated.

## RESULTS

Eighty-two patients presented with clinical symptoms and signs of IC/C-TB or CD during the study period.

Fifty-eight patients fulfilled the inclusion criteria. Table 1 summarizes the demographic and clinical profile of patients with TB and CD.

Nine and 16 patients with C-TB and CD, respectively, had histological confirmation of respective diagnosis. In 33 patients, the histological diagnosis was inconclusive. Figures 2 and 3 show the colonoscopic findings in endoscopy-diagnosed CD and TB in H-UC patients, respectively. In one patient, colonoscopic diagnosis of either CD or TB was not possible. While the sensitivity of colonoscopic for diagnosing C-TB was high at 88.9% (95% confidence interval [CI]: 51.8–99.7), it



**Figure 2:** Colonoscopic features of tuberculosis in patients with unclassified histology

**Table 1: Demographic and clinical profile of tuberculosis and Crohn's disease**

Variables	Clinical	
	TB (n=36), n (%)	CD (n=22), n (%)
Mean age (years)	33±18.6	27±5.2
Male:female	25:11	8:14
Mean per capita income (Rs.)	815	1440
Smokers	7 (19.4)	2 (9.1)
Alcoholics	8 (22.2)	4 (18.2)
Tobacco chewers	3 (8.3)	1 (4.6)
History of appendectomy	2 (5.6)	1 (4.6)
History of surgery for pile/fissure/perianal abscess	3 (8.3)	2 (9.1)
Treatment for tuberculosis	3 (8.3)	2 (9.1)
Mean duration of illness (months)	13	11
Interval between onset and diagnosis (months)	14	13.5
Fever	15 (41.6)	7 (31.8)
Abdominal pain	8 (22.2)	19 (86.4)
Diarrhea	11 (30.6)	5 (22.7)
Blood and mucus	19 (52.7)	12 (54.5)
Mass abdomen	23 (63.8)	11 (50)
Perianal symptoms (fissure, hemorrhoid, abscess)	3 (8.3)	7 (31.8)
Edema legs	5 (13.8)	6 (27.2)
Extraintestinal manifestations	None	None
Anemia	4 (11.1)	7 (31.8)
Hypoproteinemia	3 (8.3)	6 (27.2)

TB=Tuberculosis, CD=Crohn's disease

was significantly low at 50% (95% CI: 24.7–75.4) for CD. The reverse was true for CD whose specificity was high at 71.4% (95% CI: 55.3–84.3) and low for TB at 46.9% (95% CI: 32.5–61.7).

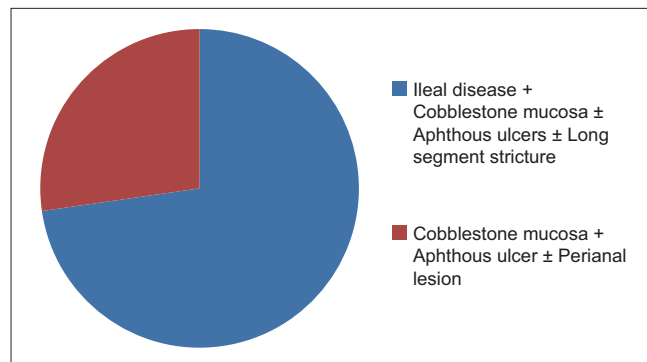
All the patients confirmed as CD or TB responded well to respective treatment. Perianal lesions in addition required 8 weeks of metronidazole (400 mg three times a day) and ciprofloxacin (500 mg twice a day). One patient required surgical intervention. None required biologicals.

Of the 21 patients with colonoscopic diagnosis of TB, 14 completed the treatment and recovered completely (71.4%). Two required surgical resection and diagnosis of TB was confirmed on the resected specimen. Three patients failed to respond at 8 weeks and were reassessed and treated as CD. Two of the three patients had aphthous ulcers, cobblestone mucosa, and short-segment stricture of 2.5 cm with ileocaecal valve destruction. One required further surgical intervention for partial small bowel obstruction and was confirmed as TB on resected specimen. Two patients were lost to follow-up [Figure 4].

Of the 11 patients with C-CD, 6 responded to steroids and maintenance azathioprine. Three other patients had evidence of CD in small bowel and responded to immunosuppressant. Two were lost to follow-up.

## DISCUSSION

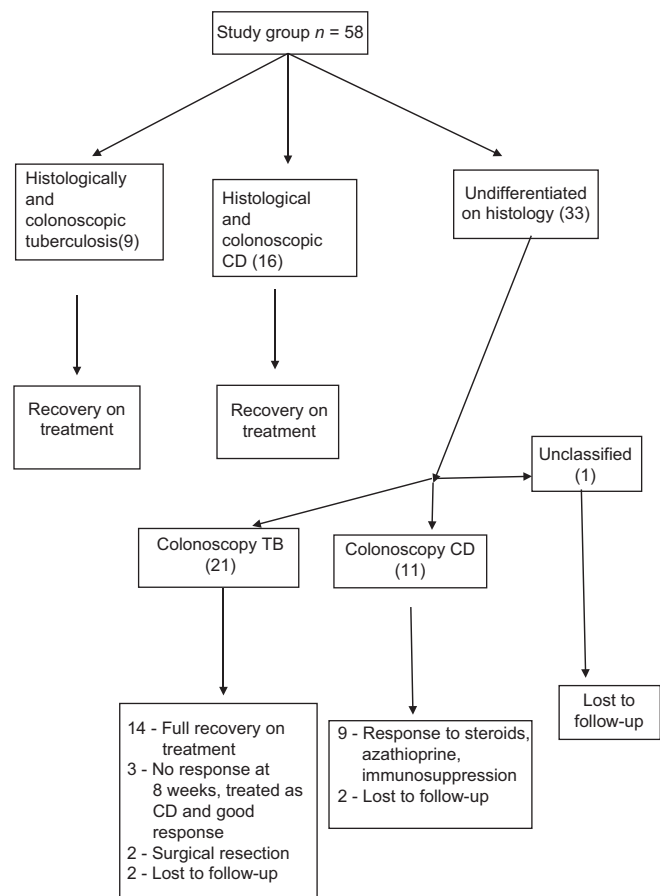
In our study, TB was prevalent among the patients from lower socioeconomic strata, whereas CD was common among the affluent. Symptoms of fever, blood and mucous diarrhea, and abdominal mass dominated in TB. In CD, female predilection, perianal symptoms, periumbilical abdominal pain, anemia, and hypoproteinemia were noted. These findings are similar to earlier studies.<sup>[4-6]</sup> Though extraintestinal manifestations have been reported to be common in CD,<sup>[7]</sup> we did not find this in our small cohort. Recent Indian data suggest that the prevalence of extraintestinal manifestations is 38.3% in CD and 14.3%



**Figure 3:** Colonoscopic features in Crohn's disease in patients with unclassified histology

in ITB.<sup>[5]</sup> About 38% of patients have at least one and 20% have multiple extraintestinal manifestations.<sup>[8]</sup> The differences in our observations could be due to small sample size, lack of follow-up data, and exclusion of known CD or TB cases in the study cohort. Moreover, none of our patients were examined by trained rheumatologists, ophthalmologists, or dermatologists and hence a few subtle findings might have been missed.

Based on colonoscopic findings, 30 and 27 patients had features of TB and CD, respectively. One patient had considerable overlapping features of CD and TB. Ileocaecal region is the most commonly involved area in TB due to numerous reasons such as physiological stasis, high rate of fluid and electrolyte absorption, and an abundance of lymphoid tissue.<sup>[9,10]</sup> Thus, biopsy from a normal-appearing terminal ileum is likely to reveal granuloma in an additional 4% of patients.<sup>[11]</sup> Terminal ileal involvement alone with relative cecal sparing has also been described in TB.<sup>[4]</sup> Segmental colonic involvement in the absence of ileocaecal involvement and pancolitis may be noted in 10%–20% and 5% of cases, respectively.<sup>[12-14]</sup> Ileocolonic CD is noted in 39.2% cases of CD in India.<sup>[15]</sup> Aphthous ulcers are usually the earliest changes which are followed by cobblestoning,



**Figure 4:** Study methodology and results in algorithm

fistula formation, and development of varied sized strictures.<sup>[16]</sup> Upper gastrointestinal involvement may be noted in one-third of cases of CD.<sup>[17]</sup> In spite of considerable overlap in the endoscopic findings between TB and CD, certain features favor a high probability to a higher likelihood of CD. These include involvement of left side of the colon, involvement of multiple segments of the intestine, and presence of longitudinal ulcers and cobblestoning of the mucosa.<sup>[18]</sup> In our study, correlating colonoscopic findings in TB and CD the presence of aphthous ulcers, isolated ileal involvement, cobblestoning, long-segment strictures, and perianal involvement predicted the diagnosis of CD than TB, with variable significances. This was similar to the observations by Lee *et al.*<sup>[19]</sup>

Twenty-five patients (43.1%) had a perfect colonoscopy correlation with histology for CD and TB. For TB, this was in 30% (9 out of 30 cases) and 59.3% for CD (16 out of 27). In the remaining patients, though the colonoscopy had features of TB or CD, histology was not informative. One patient remained unclassified on histology and had overlapping features of the two diseases at colonoscopy. This highlights the diagnostic dilemma in Indian settings where TB is rampant and CD is emerging. We had earlier reported similar findings in our retrospective analysis from the same center. Of a total of 102 patients, 60 (58.8%) were classified as TB based on clinical presentation, 20 (19.6%) as CD, and 22 (21.6%) could not be differentiated based on clinical presentation, imaging, and colonoscopy. Only 12 (20%) patients in the TB group and 13 (65%) in the CD group could be confirmed on histology. Nine (41%) patients in the group who could not be differentiated before histology could be correctly classified as TB or CD. The diagnosis changed from CD to TB in one patient and from TB to CD in 14 patients. In the remaining 52 (51%) patients, the diagnosis remained elusive even at histology.<sup>[20]</sup> The type and frequency of granulomas, presence or absence of ulcers lined by epithelioid histiocytes and microgranulomas, and the distribution of chronic inflammation are the histological parameters that have been used to differentiate TB and CD in mucosal biopsy specimens obtained at colonoscopy.<sup>[3]</sup> However, the yield varies significantly and is dependent on the expertise of a dedicated histopathologist.

The sensitivity and specificity of colonoscopy for diagnosing TB were 88.9% and 46.9%, respectively. However, the sensitivity and specificity for diagnosing CD were 50% and 71.4%, respectively. In their study, Lee *et al.*<sup>[19]</sup> have shown that the diagnosis of either ITB or CD would have been made correctly in 77 of their

88 patients (87.5%), incorrectly in seven patients (8.0%), and would not have been made in four patients (4.5%).

With anti-TB treatment in TB group, improvement was noted in 23 (76.7%) patients. However, three cases (10%) failed to respond at the end of 8 weeks and were treated as CD with good results. Two patients required surgery and two were lost to follow-up. Among the CD patients, 25 (92.6%) responded to combination of steroids and azathioprine or other immunosuppressants. Two were lost to follow-up. Our findings are similar to other Indian centers which report that, in endemic regions, empirical trial of ATT and response to treatment at 3 months may help to make a diagnosis in difficult cases.<sup>[21-23]</sup>

## CONCLUSION

Our study has looked at the role of colonoscopy in predicting the diagnosis of IC/C-TB and C-CD. Colonoscopic findings of isolated ileal involvement, aphthous ulcer, cobblestone mucosa, long-segment strictures, skip lesions, and perianal involvement favor a diagnosis of CD and not ITB. Correlation of colonoscopy with histology is poor for both CD and TB. The accuracy, sensitivity, and specificity of colonoscopy were better and superior for the diagnosis of CD than in the diagnosis of TB. Large-volume multicentric studies may be necessary to further validate the present information, especially the outliers where CD and TB are close mimickers with similar clinical presentation, mucosal changes, and overlap in histology that exist between the two granulomatous disorders.

## Financial support and sponsorship

Nil.

## Conflicts of interest

There are no conflicts of interest.

## REFERENCES

1. Available from: [http://www.who.int.tb.publications/2007/factsheet\\_2007.pdf](http://www.who.int.tb.publications/2007/factsheet_2007.pdf). [Last accessed on 2007 Apr 18].
2. Pulimood AB, Peter S, Ramakrishna B, Chacko A, Jeyamani R, Jeyaseelan L, *et al.* Segmental colonoscopic biopsies in the differentiation of ileocolic tuberculosis from Crohn's disease. *J Gastroenterol Hepatol* 2005;20:688-96.
3. Pulimood AB, Ramakrishna BS, Kurian G, Peter S, Patra S, Mathan VI, *et al.* Endoscopic mucosal biopsies are useful in distinguishing granulomatous colitis due to Crohn's disease from tuberculosis. *Gut* 1999;45:537-41.
4. Almadi MA, Ghosh S, Aljebreen AM. Differentiating intestinal tuberculosis from Crohn's disease: A diagnostic challenge. *Am J Gastroenterol* 2009;104:1003-12.
5. Singh B, Kedia S, Konijeti G, Mouli VP, Dhingra R, Kurrey L, *et al.* Extraintestinal manifestations of inflammatory bowel disease and intestinal tuberculosis: Frequency and relation with disease phenotype. *Indian J Gastroenterol* 2015;34:43-50.
6. Jayanthi V, Robinson RJ, Malathi S, Rani B, Balambal R,

- Chari S, *et al.* Does Crohn's disease need differentiation from tuberculosis? *J Gastroenterol Hepatol* 1996;11:183-6.
7. Sharma R, Madhusudhan KS, Ahuja V. Intestinal tuberculosis versus crohn's disease: Clinical and radiological recommendations. *Indian J Radiol Imaging* 2016;26:161-72.
  8. Bandyopadhyay D, Bandyopadhyay S, Ghosh P, De A, Bhattacharya A, Dhali GK, *et al.* Extraintestinal manifestations in inflammatory bowel disease: Prevalence and predictors in Indian patients. *Indian J Gastroenterol* 2015;34:387-94.
  9. Haddad FS, Ghossain A, Sawaya E, Nelson AR. Abdominal tuberculosis. *Dis Colon Rectum* 1987;30:724-35.
  10. Chen WS, Su WJ, Wang HS, Jiang JK, Lin JK, Lin TC. Large bowel tuberculosis and possible influencing factors for surgical prognosis: 30 years' experience. *World J Surg* 1997;21:500-4.
  11. Misra SP, Dwivedi M, Misra V, Gupta M, Kunwar BK. Endoscopic biopsies from normal-appearing terminal ileum and cecum in patients with suspected colonic tuberculosis. *Endoscopy* 2004;36:612-6.
  12. Alvares JF, Devarbhavi H, Makhija P, Rao S, Kottoor R. Clinical, colonoscopic, and histological profile of colonic tuberculosis in a tertiary hospital. *Endoscopy* 2005;37:351-6.
  13. Singh V, Kumar P, Kamal J, Prakash V, Vaiphei K, Singh K. Clinicocolonoscopy profile of colonic tuberculosis. *Am J Gastroenterol* 1996;91:565-8.
  14. Shah S, Thomas V, Mathan M, Chacko A, Chandy G, Ramakrishna BS, *et al.* Colonoscopic study of 50 patients with colonic tuberculosis. *Gut* 1992;33:347-51.
  15. Makharia GK, Ramakrishna BS, Abraham P, Choudhuri G, Misra SP, Ahuja V, *et al.* Survey of inflammatory bowel diseases in India. *Indian J Gastroenterol* 2012;31:299-306.
  16. Rutgeerts PJ. From aphthous ulcer to full-blown Crohn's disease. *Dig Dis* 2011;29:211-4.
  17. Diaz L, Hernandez-Oquet RE, Deshpande AR, Moshiree B. Upper gastrointestinal involvement in Crohn disease: Histopathologic and endoscopic findings. *South Med J* 2015;108:695-700.
  18. Moka P, Ahuja V, Makharia GK. Endoscopic features of gastrointestinal tuberculosis and Crohn's disease. *J Dig Endosc* 2017;8:1-11.
  19. Lee YJ, Yang SK, Byeon JS, Myung SJ, Chang HS, Hong SS, *et al.* Analysis of colonoscopic findings in the differential diagnosis between intestinal tuberculosis and Crohn's disease. *Endoscopy* 2006;38:592-7.
  20. Navaneethan U, Cherian JV, Prabhu R, Venkataraman J. Distinguishing tuberculosis and Crohn's disease in developing countries: How certain can you be of the diagnosis? *Saudi J Gastroenterol* 2009;15:142-4.
  21. Sood A, Midha V, Singh A. Differential diagnosis of Crohn's disease versus ileal tuberculosis. *Curr Gastroenterol Rep* 2014;16:418.
  22. Amarapurkar DN, Patel ND, Rane PS. Diagnosis of Crohn's disease in India where tuberculosis is widely prevalent. *World J Gastroenterol* 2008;14:741-6.
  23. Pratap Mouli V, Munot K, Ananthkrishnan A, Kedia S, Addagalla S, Garg SK, *et al.* Endoscopic and clinical responses to anti-tubercular therapy can differentiate intestinal tuberculosis from Crohn's disease. *Aliment Pharmacol Ther* 2017;45:27-36.