

Case Report

Ciliated Foregut Cyst of the Pancreas Presenting as a Mucinous Cystic Neoplasm

Nadia Huq, Wesley Papenfuss¹, Nalini M. Guda²

Departments of Internal Medicine, ¹Surgical Oncology and ²Gastroenterology, Aurora St. Luke's Medical Center, Milwaukee, WI, USA

ABSTRACT

A 53-year-old underwent an abdominal computed tomography for hematuria that incidentally discovered a cystic lesion of the pancreas. Endoscopic ultrasound revealed a structure with debris and septations; fine-needle aspiration with negative cytology but elevated tumor marker suggested a mucinous cystic neoplasm or an intraductal papillary mucinous neoplasm. Laparoscopic excision confirmed a walled-off cyst detachable from the posterior aspect of the pancreas consistent with a ciliated foregut cyst. There are limited data on ciliated foregut cysts of the pancreas, and the current report highlights the diagnostic dilemma and a review of the current literature.

KEYWORDS: Embryonic cyst, intraductal papillary mucinous neoplasm, mucinous cystic neoplasm, pancreatic lesion

INTRODUCTION

Ciliated foregut cysts of the pancreas have unclear incidence but are considered rare. Due to increase in cross-sectional imaging and sensitivity of current scans, there has been an increase in the detection of incidental cysts of the pancreas. Some cystic lesions of the pancreas have malignant potential and hence even those incidentally detected are subject to further evaluation. Although there are case reports of ciliated foregut cysts detected by endoscopic ultrasound (EUS) and fine-needle aspiration (FNA), there are no clear or definitive diagnostic criteria. Thus, when fluid carcinoembryonic antigen (CEA) levels are high, these lesions are evaluated further.^[1,2]

CASE REPORT

A 53-year-old Caucasian female had undergone computed tomography (CT) urography for evaluation of hematuria. She had no prior pancreatic disease, weight loss, jaundice, early satiety, or right upper quadrant pain. CT findings reported a lobulated cystic area with septations in the posterior body of the pancreas and adjacent cysts of 4.9 cm × 3.8 cm in axial diameter and 2.6 cm in cephalocaudad extent. Appreciable calcification was not identified [Figure 1].

Laboratory tests from 3 months prior revealed normal liver function tests including albumin, aspartate transaminase, alanine transaminase, and total bilirubin. EUS was performed for further evaluation with an Olympus linear echoendoscope (Olympus Corporation, Center Valley, PA, USA). An approximately 3.5–2.5 cm anechoic lesions with some hyperechoic septations and hyperechoic material in the lesion was suggestive of debris within the body of the pancreas. No communication with the main pancreatic duct was visualized. Prophylactic antibiotics were administered, and FNA was performed using a 19-gauge needle (Cook Echo tip, Cook Medical, Bloomington, IN, USA) and 6cc of thick brown fluid was aspirated. The rest of the pancreas was sonographically normal.

Cyst fluid was sent and amylase and CEA levels were elevated to 1616 units/L and 1190.8 units/L, respectively. The cytology report was negative for malignant cells. There were findings of foam cells, scattered red blood cells, and rare mixed inflammatory cells. The absence of cyst lining cells favored a pseudocyst. However, the specimen did not contain

Address for correspondence: Dr. Nalini M. Guda, 2801 W Kinnickinnic River Pkwy, Milwaukee, WI 53215, USA. E-mail: nguda@wisc.edu

This is an open access journal, and articles are distributed under the terms of the Creative Commons Attribution-NonCommercial-ShareAlike 4.0 License, which allows others to remix, tweak, and build upon the work non-commercially, as long as appropriate credit is given and the new creations are licensed under the identical terms.

For reprints contact: reprints@medknow.com

How to cite this article: Huq N, Papenfuss W, Guda NM. Ciliated foregut cyst of the pancreas presenting as a mucinous cystic neoplasm. J Dig Endosc 2018;9:125-7.

Access this article online

Quick Response Code:



Website: www.jdeonline.in

DOI: 10.4103/jde.JDE_20_17

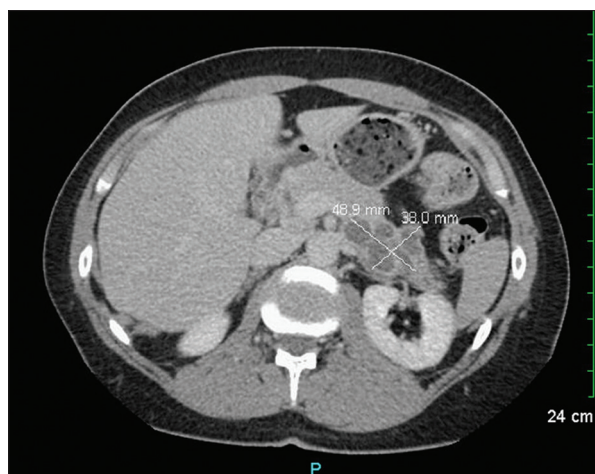


Figure 1: Computed tomography urogram. A complex lobulated cyst with septations or cystic mass of the posterior body of the pancreas of 4.9 cm × 3.8 cm × 2.6 cm diameter

the degree of debris and inflammation usually seen with a pseudocyst but appeared as a true cyst with unrepresented cyst lining.

CT abdomen completed 10 months later showed the same complex cystic mass located along the inferior aspect of the body of the pancreas without significant change in size measuring approximately 2.4 cm × 5.3 cm × 2.4 cm in anteroposterior, width, and height dimensions, respectively. At this time, the lesion demonstrated no calcification but did have internal thin enhancing septa. There was no dominant enhancing mural nodule. The patient remained asymptomatic during this course, but given the size of the lesion and high CEA level, there was a concern for a mucinous cystic lesion with a potential for malignant transformation. The patient was given the option of continued monitoring or surgical excision given the risk for malignant transformation, and she has elected to undergo surgical excision.

In surgery, mass lesion was identified at the inferior border of the pancreas just lateral to the inferior mesenteric vein, which appeared to be adherent to the posterior wall of the pancreas. Further dissection performed on the mass lesion allowed the cyst to separate quite easily from the posterior portion of the pancreas and did not have any actual pancreatic involvement. Further dissection allowed for full excision in its entirety without rupture. There was no concern for any malignancy and closure of the laparotomy was performed without any pancreatic resection. Histopathology of the lesion showed a cyst lined by benign epithelium with most of the epithelium covered in apical cilia. Slight subepithelial chronic inflammation was seen, and there was a surrounding thick muscular wall. No malignancy was present [Figure 2]. These histological findings favored a classic ciliated foregut

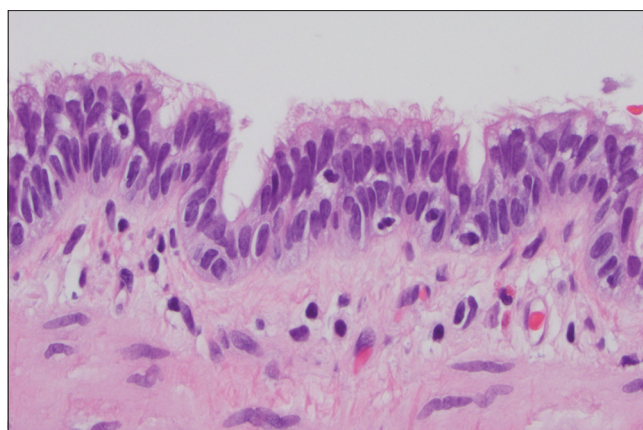


Figure 2: Histopathology of pancreatic cyst. High power (×400) on lining epithelium. Prominent cilia are present

cyst. The patient recovered postoperative and was discharged home uneventfully.

DISCUSSION

A cyst with ciliated epithelium with no other additional defining features is referred to as a ciliated foregut cyst.^[1,3-5] A majority of pancreatic foregut cysts in current literature were diagnosed as mucinous cystic neoplasm (MCN) of the pancreas in the preoperatively workup.^[3] True cysts of the pancreas are characterized by an epithelial lining that can then be classified as acquired, congenital, or developmental cysts.^[5] Although it seemed evident from the case's initial EUS-FNA cytology that a true cyst may be present, not enough information was available to truly distinguish the cyst from an intraductal papillary mucinous neoplasm (IPMN) or MCN given the elevated CEA level. It is clear however that foregut cysts can arise independent of the subdiaphragmatic organs and this may explain why the cyst in our case was easily removed from the posterior aspect of the pancreas without any evident involvement of the pancreas itself.^[6] While EUSFNA can be used as a tool to further classify pancreatic cysts, it did not seem to yield enough information to distinguish IPMN and MCN from a ciliated pancreatic foregut cyst in this case, and further classification required surgical pathology. Our case demonstrates the difficulty in identifying these cysts by the conventional imaging and cyst fluid analysis and highlights the need to recognize duplication cysts of the foregut as a differential for the pancreatic cysts with elevated CEA levels.

Financial support and sponsorship

Nil.

Conflicts of interest

There are no conflicts of interest.

REFERENCES

1. Al-Rashdan A, Schmidt CM, Al-Haddad M, McHenry L, Leblanc JK, Sherman S, *et al.* Fluid analysis prior to surgical resection of suspected mucinous pancreatic cysts. A single centre experience. *J Gastrointest Oncol* 2011;2:208-14.
2. Kaimakliotis P, Riff B, Pourmand K, Chandrasekhara V, Furth EE, Siegelman ES, *et al.* Sendai and Fukuoka consensus guidelines identify advanced neoplasia in patients with suspected mucinous cystic neoplasms of the pancreas. *Clin Gastroenterol Hepatol* 2015;13:1808-15.
3. Sharma S, Nezakatgoo N, Sreenivasan P, Vanatta J, Jabbour N. Foregut cystic developmental malformation: New taxonomy and classification – Unifying embryopathological concepts. *Indian J Pathol Microbiol* 2009;52:461-72.
4. Woon CS, Pambuccian SE, Lai R, Jessurun J, Gulbahce HE. Ciliated foregut cyst of pancreas: Cytologic findings on endoscopic ultrasound-guided fine-needle aspiration. *Diagn Cytopathol* 2007;35:433-8.
5. Gómez Mateo Mdel C, Muñoz Forner E, Sabater Ortí L, Ferrández Izquierdo A. Foregut cystic malformations in the pancreas. Are definitions clearly established? *JOP* 2011;12:420-4.
6. Sharma S, Dean AG, Corn A, Kohli V, Wright HI, Sebastian A, *et al.* Ciliated hepatic foregut cyst: An increasingly diagnosed condition. *Hepatobiliary Pancreat Dis Int* 2008;7:581-9.