

## Original Article

# Clinical Profile, Complications, Management, and Outcome of Post-Endoscopic Retrograde Cholangiopancreatography Pancreatitis: A North Indian Study

Mudasir Habib, Hilal Ahmad Dar, Mushtaq Ahmad Khan, Altaf Hussain Shah, Showkat Ali Zargar, Bhagat Singh, Nadeem Ahmad Sheikh, Aadil Ashraf, Sozia Mohammad

Department of  
Gastroenterology,  
Sher-I-Kashmir Institute of  
Medical Sciences, Srinagar,  
Jammu and Kashmir, India

## ABSTRACT

**Aim:** The aim of this study was to assess clinical profile, complications, management, and outcome of postendoscopic retrograde cholangiopancreatography (ERCP) pancreatitis. **Methods:** In this prospective study, 1320 patients were followed for the development of post-ERCP pancreatitis. Post-ERCP complications and outcome were assessed. **Results:** The percentage of post-ERCP pancreatitis in our patients was 5.3%. The mean age of patients with post-ERCP pancreatitis was 49.9 years. About 15.7% of the patients who developed post-ERCP pancreatitis experienced complications in the form of respiratory failure and sepsis. **Conclusion:** The incidence of post-ERCP pancreatitis was 5.3%. The major complications after post-ERCP pancreatitis were respiratory failure and sepsis. The outcome of post-ERCP pancreatitis was good, as there was no mortality. However, majority of patients with severe post-ERCP pancreatitis developed sepsis and received antibiotics.

**KEYWORDS:** Endoscopic retrograde cholangiopancreatography, hyperamylasemia, pancreatitis, respiratory failure, sepsis

## INTRODUCTION

Pancreatitis is the most common complication of endoscopic retrograde cholangiopancreatography (ERCP) and carries a high morbidity and mortality.<sup>[1,2]</sup> There is 3%–5% incidence of this complication as shown in various large clinical studies.<sup>[2–4]</sup> A systematic survey of 21 studies involving 16,855 patients (1987–2003) found a 3.5% occurrence of post-ERCP pancreatitis, 0.4% of patients had severe pancreatitis with 0.11% deaths.<sup>[5]</sup> The risk of post-ERCP pancreatitis is determined at least as much by the characteristics of the patient as by endoscopic techniques or maneuvers. Patient-related predictors found to be significant in one or more major studies include younger age, suspected sphincter of Oddi dysfunction, history of post-ERCP pancreatitis, and absence of elevated serum bilirubin and female gender. Papillary trauma induced by difficult cannulation has an effect independent from the number of pancreatic duct contrast injections, and pancreatitis may occur without any apparent pancreatic instrumentation. Pathogenesis

of post-ERCP pancreatitis is not completely understood. It seems to be an instrumentation and/or injection of contrast media for imaging of the pancreatic duct.<sup>[6,7]</sup> These inciting factors lead to premature intracellular activation of pancreatic proteolytic enzymes, autodigestion, and release of inflammatory cytokines that produce both local and systemic effects.<sup>[8,9]</sup> There are various mechanisms proposed in the pathogenesis of post-ERCP pancreatitis. These include mechanical injury from instrumentation of papilla and pancreatic duct thermal injury following application of electrosurgical current during biliary and pancreatic sphincterotomy, hydrostatic injury following injection of contrast media

**Address for correspondence:** Dr. Hilal Ahmad Dar, Sher-I-Kashmir Institute of Medical Sciences, Srinagar, Jammu and Kashmir, India.  
E-mail: drhilaldar@gmail.com

This is an open access journal, and articles are distributed under the terms of the Creative Commons Attribution-NonCommercial-ShareAlike 4.0 License, which allows others to remix, tweak, and build upon the work non-commercially, as long as appropriate credit is given and the new creations are licensed under the identical terms.

For reprints contact: reprints@medknow.com

**How to cite this article:** Habib M, Dar HA, Khan MA, Shah AH, Zargar SA, Singh B, *et al.* Clinical profile, complications, management, and outcome of post-endoscopic retrograde cholangiopancreatography pancreatitis: A North Indian study. *J Dig Endosc* 2018;9:155-8.

## Access this article online

## Quick Response Code:



Website: [www.jdeonline.in](http://www.jdeonline.in)

DOI: 10.4103/jde.JDE\_21\_18

into the pancreatic duct, Chemical or allergic injury following injection of contrast media into the pancreatic duct, enzymatic injury with intraluminal activation of proteolytic enzymes and infection from contaminated endoscope and accessories.<sup>[10,11]</sup> Post-ERCP pancreatitis is defined as acute pancreatitis occurring following an ERCP procedure. This consists of the development of new pancreatic-type abdominal pain associated with hyperamylasemia of three times the upper limit of normal, occurring 24 h after an ERCP requiring hospital admission. If the diagnosis of post-ERCP pancreatitis is in doubt, a contrast-enhanced abdominal computed tomography scan should be performed in the first 24–48 h. Earlier than this, important changes such as necrosis of pancreatic parenchyma and peripancreatic fluid collections may be missed.

## METHODS AND STUDY DESIGN

This study was conducted in the Department of Gastroenterology, SKIMS Srinagar, over a period of 2 years. The aim of this study was to assess clinical profile, complications, management and outcome of post-ERCP pancreatitis. It is a prospective study, and all patients who underwent ERCP were enrolled. The diagnosis of post-ERCP pancreatitis was based on the development of new pancreatic type abdominal pain associated with hyperamylasemia of three times the upper limit of normal, occurring 24 h after an ERCP requiring hospital admission. Serum amylase level was measured before and 24 h after ERCP. Diclofenac suppository was given to all patients undergoing ERCP. Parameters that were compared included clinical profile, basic laboratory parameters, severity of pancreatitis, and hospital stay and mortality. The severity of Post-ERCP pancreatitis was defined by using the consensus grading as mild post-ERCP Pancreatitis resulting in hospitalization (or prolongation of the existing hospitalization) for  $\leq 3$  days. Moderate post-ERCP Pancreatitis resulted in hospitalization (or prolongation of existing hospitalization) for 4–10 days. Severe Post-ERCP Pancreatitis resulting in hospitalization (or prolongation of existing hospitalization) for  $>10$  days, or leads to the development of pancreatic necrosis or pseudocyst, or requires additional endoscopic, percutaneous, or surgical intervention.

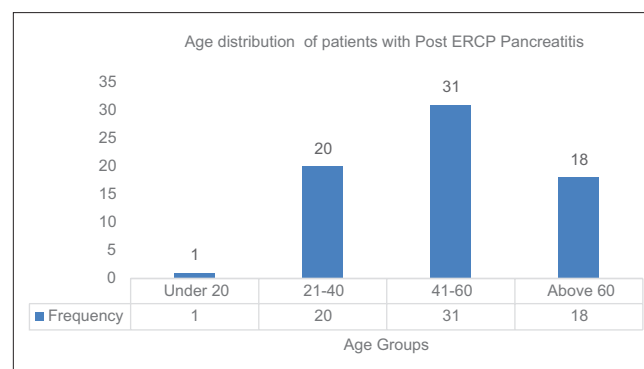
## RESULTS

In this study, a total of 1320 patients underwent ERCP and 70 patients (5.3%) developed post-ERCP pancreatitis. There were 53 females (75.71%) and 17 (24.3%) were males. The age of the patients ranged from 19 to 76 years with a mean age of 49.9 years, and the majority of patients were in the age group of 41–60 years [Figure 1]. Procedure-induced pancreatitis

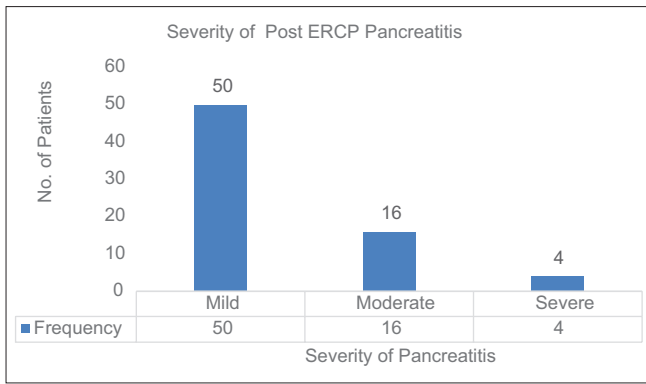
occurred in 70 patients (5.3%), it was mild in 50 patients (71.4%), moderate in 16 patients (22.9%), and severe in 4 patients (5.7%) [Figure 2]. Majority of the patients (92%) with mild pancreatitis did not develop any major complications. While 4% of patients developed septic shock and another 4% of patients developed respiratory failure. About 75% of patients with severe pancreatitis developed complications, septic shock in 25% and respiratory failure in 50% of patients and all of these patients recovered with conservative treatment [Figure 3]. The hospital stay in patients suffering from severe pancreatitis was  $>7$  days. While most of the patients suffering from mild pancreatitis recovered within 3 days. All the patients who developed post-ERCP pancreatitis recovered with conservative treatment, 92% of patients with mild pancreatitis, 68% of patients with moderate pancreatitis, and 25% of patients with severe pancreatitis were treated without antibiotics. While 8% with mild pancreatitis, 31.3% with moderate pancreatitis and 75% of patients with severe pancreatitis, respectively, received antibiotics [Figure 4]. Of the 70 patients of post-ERCP pancreatitis 37 patients (52.8%) had cholelithiasis with choledocholithiasis, 24 patients (34.2%) had choledocholithiasis, 5 patients (7.1%) had extrahepatic biliary obstruction, 2 patients (2.8%) had bile duct stricture, 1 patient (1.4%) had biliary ascariasis, and 1 patient (1.4%) had choledochal cyst [Figure 5].

## DISCUSSION

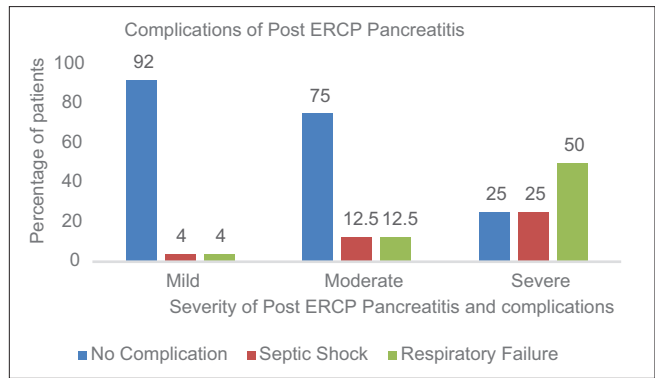
In our study, 5.3% of patients developed post-ERCP pancreatitis, similar results have been reported by Freeman *et al.*<sup>[11]</sup> All the patients recovered with conservative treatment some required antibiotics. About 92% of mild pancreatitis, 68% of moderate pancreatitis, and 25% of patients with severe pancreatitis were treated without antibiotics. While 8% of patients with mild pancreatitis, 31.3% of patients with moderate pancreatitis and 75% of patients with severe pancreatitis respectively



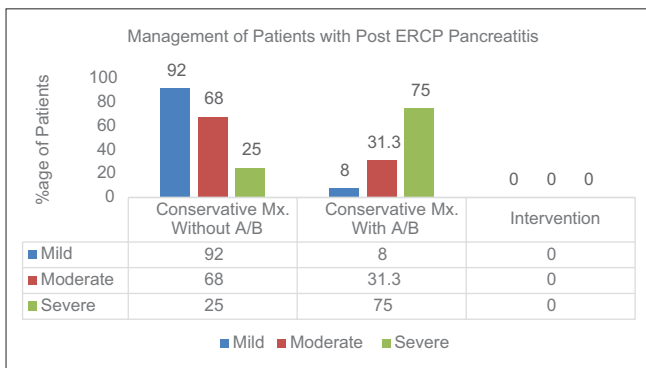
**Figure 1:** The age of the patients ranged from 19 to 76 years with mean age of 49.9 years and majority of patients were in the age group of 41–60 years



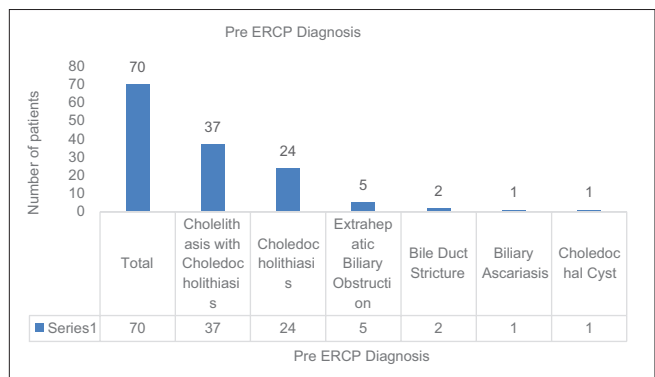
**Figure 2:** Procedure induced pancreatitis occurred in 70 patients (5.3%); it was mild in 50 patients (71.4%), moderate in 16 patients (22.9%) and severe in 4 patients (5.7%)



**Figure 3:** Majority of the patients 92% with mild pancreatitis did not developed any major complications. Patients with severe pancreatitis developed septic shock in 25% and respiratory failure in 50%, and all of these patients recovered with conservative treatment



**Figure 4:** All the patients of Post-ERCP pancreatitis recovered with conservative treatment. 92% of mild pancreatitis, 68% of moderate and 25% were treated without antibiotics. While 8% with mild pancreatitis, 31.3% with moderate pancreatitis and 75% with severe pancreatitis, respectively, received antibiotics



**Figure 5:** Of the 70 patients of Post-ERCP pancreatitis, the majority of patients 37 (52.8%) had cholelithiasis with choledocholithiasis, 24 patients (34.2%) had choledocholithiasis, 5 patients (7.1%) had extrahepatic biliary obstruction, 2 patients (2.8%) had bile duct stricture, 1 patient (1.4%) had biliary ascariasis and 1 patient (1.4%) had choledochal cyst

received antibiotics. Vandervoort *et al.*<sup>[12]</sup> study showed that 93% cases of post-ERCP pancreatitis were managed with conservative treatment only. A study conducted by Bhatia *et al.*<sup>[13]</sup> showed that 95% of patients with post-ERCP pancreatitis recovered with conservative treatment only. In our study, of the 70 patients of post-ERCP pancreatitis, the common indications of ERCP were cholelithiasis with choledocholithiasis in 37 patients (52.8%), choledocholithiasis in 24 patients (34.2%), extrahepatic biliary obstruction in 5 patients (7.1%), bile duct stricture in 2 patients (2.8%), biliary ascariasis in 1 patient (1.4%), and choledochal cyst in 1 patient (1.4%). In Suissa *et al.*<sup>[14]</sup> study, the procedure was performed with a therapeutic intention in 95% of cases because of suspicion of cholelithiasis (58%), tumor of pancreas/bile ducts (30%), postcholecystectomy bile leak or bile duct stenosis (6%), or treatment of chronic pancreatitis (1%).

**CONCLUSION**

The incidence of post-ERCP pancreatitis was 5.3%. The major complications after post-ERCP pancreatitis

were respiratory failure and sepsis. The outcome of post-ERCP pancreatitis was good, as there was no mortality. However, majority of severe pancreatitis developed sepsis and received antibiotics.

**Financial support and sponsorship**

Nil.

**Conflicts of interest**

There are no conflicts of interest.

**REFERENCES**

- Freeman ML, DiSario JA, Nelson DB, Fennerty MB, Lee JG, Bjorkman DJ, *et al.* Risk factors for post-ERCP pancreatitis: A prospective, multicenter study. *Gastrointest Endosc* 2001;54:425-34.
- Cheon YK, Cho KB, Watkins JL, McHenry L, Fogel EL, Sherman S, *et al.* Frequency and severity of post-ERCP pancreatitis correlated with extent of pancreatic ductal opacification. *Gastrointest Endosc* 2007;65:385-93.
- Cotton PB, Garrow DA, Gallagher J, Romagnuolo J. Risk factors for complications after ERCP: A multivariate analysis of 11,497 procedures over 12 years. *Gastrointest Endosc* 2009;70:80-8.

4. Glomsaker T, Hoff G, Kvaløy JT, Søreide K, Aabakken L, Søreide JA, *et al.* Patterns and predictive factors of complications after endoscopic retrograde cholangiopancreatography. *Br J Surg* 2013;100:373-80.
5. Andriulli A, Loperfido S, Napolitano G, Niro G, Valvano MR, Spirito F, *et al.* Incidence rates of post-ERCP complications: A systematic survey of prospective studies. *Am J Gastroenterol* 2007;102:1781-8.
6. Freeman ML. Adverse outcomes of ERCP. *Gastrointest Endosc* 2002;56:S273-82.
7. Demols A, Deviere J. New frontiers in the pharmacological prevention of post-ERCP pancreatitis: The cytokines. *JOP* 2003;4:49-57.
8. Karne S, Gorelick FS. Etiopathogenesis of acute pancreatitis. *Surg Clin North Am* 1999;79:699-710.
9. Christoforidis E, Goulimaris I, Kanellos I, Tsalis K, Demetriades C, Betsis D, *et al.* Post-ERCP pancreatitis and hyperamylasemia: Patient-related and operative risk factors. *Endoscopy* 2002;34:286-92.
10. Donnellan F, Byrne MF. Prevention of post-ERCP pancreatitis. *Gastroenterol Res Pract* 2012;2012:796751.
11. Freeman ML, Guda NM. Prevention of post-ERCP pancreatitis: A comprehensive review. *Gastrointest Endosc* 2004;59:845-64.
12. Vandervoort J, Soetikno RM, Tham TC, Wong RC, Ferrari AP Jr., Montes H, *et al.* Risk factors for complications after performance of ERCP. *Gastrointest Endosc* 2002;56:652-6.
13. Bhatia V, Garg PK, Tandon RK, Madan K. Endoscopic retrograde cholangiopancreatography-induced acute pancreatitis often has a benign outcome. *J Clin Gastroenterol* 2006;40:726-31.
14. Suissa A, Yassin K, Lavy A, Lachter J, Chermech I, Karban A, *et al.* Outcome and early complications of ERCP: A prospective single center study. *Hepatogastroenterology* 2005;52:352-5.