

Case Report

Endoscopic Management of an Iatrogenic Colonic Perforation Using Standard Hemoclips

Sanjeev Kumar, Saket Kumar¹, Sujit Kumar, Vijay Prakash

Department of Medical Gastroenterology, Bihar Institute of Gastroenterology, Patna, Bihar, ¹Department of Surgical Gastroenterology, King George's Medical University, Lucknow, Uttar Pradesh, India

ABSTRACT

Iatrogenic colonic perforation is an unusual but life-threatening complication of colonoscopy. The recent advancement in endoscopy technology has made nonoperative treatment a safe and effective option for managing such perforations. A 70-year-old man sustained an iatrogenic sigmoid perforation during diagnostic colonoscopy. The abdominal X-ray showed free gas under diaphragm. He was started on conservative management and intravenous antibiotics. He underwent a second colonoscopy after 2.5-h, perforation was identified and closed with standard hemoclips. He recovered well and was discharged from hospital 6 days later. There are only a handful of reports in the medical literature describing successful outcomes following endoscopic management. Most of the cases have been managed with over-the-scope clips or endoscopic sutures that are quite expensive. In the present report, an iatrogenic sigmoid perforation was managed endoscopically with standard hemoclips. The hemoclip can be an effective, yet economical method of perforation repair in selected cases.

KEYWORDS: *Endoscopic clipping, endoscopic repair, iatrogenic colonic perforation*

INTRODUCTION

Colonoscopy is a commonly performed procedure for the diagnosis and treatment of a range of colorectal diseases. Although considered safe, the overall incidence of associated colonic perforation varies between 0.016% and 5%.^[1,2] The iatrogenic colonic perforation is considered an abdominal emergency and requires urgent repair. Although effective and life-saving, surgical intervention increases the hospital stay and overall cost of treatment.^[3,4]

We report a case of colonic perforation in an elderly gentleman during a diagnostic colonoscopy that was managed with endoscopic clipping. The use of standard metallic hemoclip (with reusable applicator) resulted in the economical yet effective management of colonic perforation. The patient recovered completely and needed for a major surgery and possible temporary ileostomy was averted.

CASE REPORT

A 70-year-old man was admitted with complains of mild right iliac fossa pain, bloating sensation, and alteration of bowel habit. There was no history of fever, anorexia, weight loss or gastrointestinal bleed. Abdominal ultrasound revealed an inflammatory thickening of the caecum and ileocaecal junction along with sludge in the gallbladder lumen. The patient underwent a diagnostic colonoscopy after preparation with 2 L of polyethylene glycol-electrolyte solution. The bowel preparation was excellent. While negotiating the scope through angulated sigmoid-descending colon junction, the patient complained of sudden onset excruciating abdominal pain. A colonic rent of about 20-mm was apparent in the sigmoid colon [Figure 1]. The further procedure was abandoned, and the scope was withdrawn. An erect

Address for correspondence: Prof. Vijay Prakash, Department of Medical Gastroenterology, Bihar Institute of Gastroenterology, Patna, Bihar, India. E-mail: vprs@rediffmail.com

Video Available on: www.jdeonline.in

Access this article online

Quick Response Code:



Website: www.jdeonline.in

DOI: 10.4103/jde.JDE_23_18

This is an open access journal, and articles are distributed under the terms of the Creative Commons Attribution-NonCommercial-ShareAlike 4.0 License, which allows others to remix, tweak, and build upon the work non-commercially, as long as appropriate credit is given and the new creations are licensed under the identical terms.

For reprints contact: reprints@medknow.com

How to cite this article: Kumar S, Kumar S, Kumar S, Prakash V. Endoscopic management of an iatrogenic colonic perforation using standard hemoclips. *J Dig Endosc* 2018;9:201-4.

abdominal X-ray was obtained that showed bilateral subdiaphragmatic-free air [Figure 2].

Meanwhile, the patient remained hemodynamically stable and had only slight tenderness over the left lumbar region. In view of old age and reluctance to undergo surgery, it was decided to attempt closure of the colonic rent endoscopically.

The patient underwent the second colonoscopy after 2.5 h of the index procedure. A cap-fitted thin scope was used to provide increased maneuverability with better visualization and stability. The scope was inserted gently using minimal CO₂ insufflation. The perforation site was recognized and the spilled out enteric contents were suctioned through the rent itself. Starting from the perforation edge, one by one 10 EZ hemoclips (EZ Hemoclip standard 135°, Olympus Health, Tokyo, Japan) were applied to close the defect completely [Figure 3 and Supplementary Video 1]. The use of standard hemoclips (with reloadable deployment device) proved to be a low-cost alternative to modalities such as endoscopic suturing or over-the-scope clips. Intravenous antibiotics were continued, and the patient was kept nil per orally for the next 3 days. The patient was kept under close clinical monitoring for early detection of peritonitis. He had a fever spike (102°F) on the first postprocedure day but remained afebrile thereafter. Abdominal tenderness decreased and bowel function returned on the fourth postprocedure day. Total leukocyte counts which were elevated on days 2 and 3, (~13,000/mm³) also normalized on day 4. Antibiotics were stopped and he was discharged on the sixth postprocedure day. He remains symptom-free at a follow-up of 2 months. On repeat ultrasound, the caecum and ileocaecal region were found to be normal and thickening had resolved.

DISCUSSION

Colonic perforation is a rare but potentially lethal complication of colonoscopy. The rectosigmoid area is the most common site for iatrogenic perforations.^[4] Both intraperitoneal and extraperitoneal perforations can occur after colonoscopy. The intraperitoneal perforations are more common and necessitate the urgent closure of defect, whereas extraperitoneal perforations are rare and amenable to conservative therapy.^[5]

Most of the iatrogenic colonic perforations are identified during the procedure itself. Sudden give way sensation along with visualization of intraperitoneal structures and/or full-thickness rent in the colon wall is sufficient to diagnose the complication. Abdominal X-ray shows the presence of free intraperitoneal air and contrast imaging studies may detect extravasation of dye through colonic rent.^[5,6]

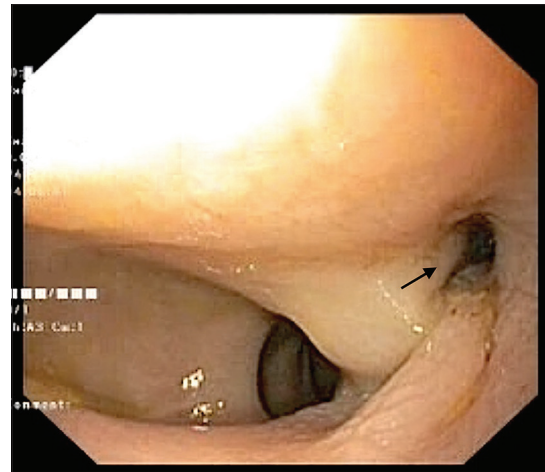


Figure 1: Colonoscopic view showing a 2-cm perforation in the sigmoid colon (arrow)

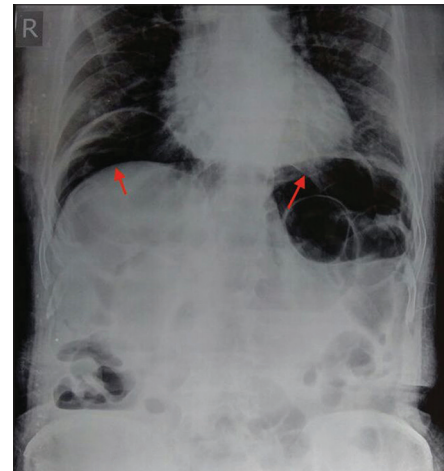


Figure 2: Abdominal X-ray showing subdiaphragmatic-free air (arrows)

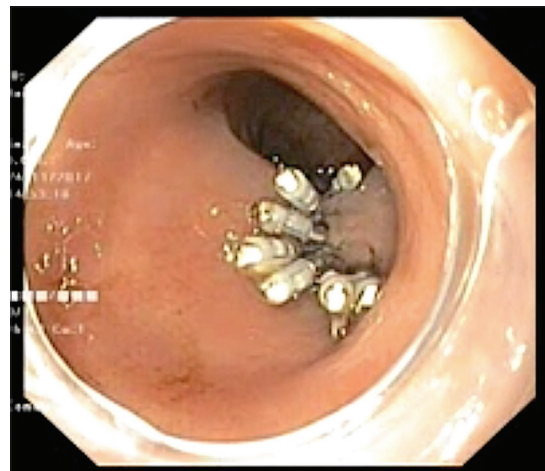


Figure 3: Closure of colonic perforation with hemoclips

Early recognition and treatment of iatrogenic colonic perforations are vital to reducing the severity of complications and death. The treatment options include conservative, operative (open or laparoscopic), and

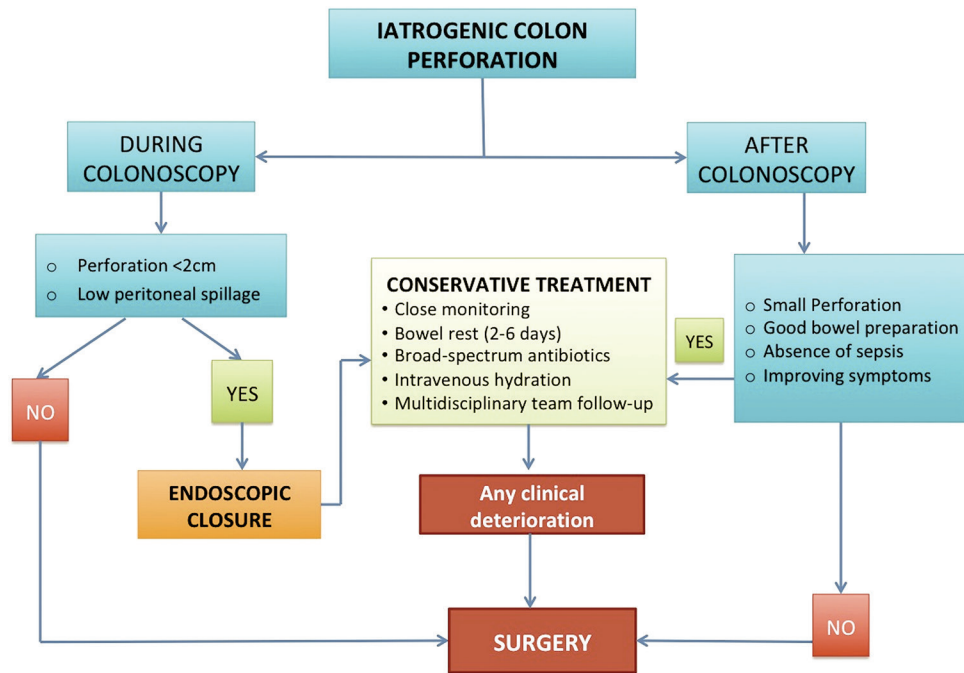


Figure 4: Algorithm for the management of iatrogenic colonoscopy perforation

endoscopic management. Surgical repair has been long considered the standard treatment for iatrogenic colonic perforations.^[7] However, recent advances in the endoscopic techniques have opened new dimensions in nonsurgical management of iatrogenic colonic perforations. Yoshikane *et al.* reported the first successful endoscopic repair of iatrogenic colonic perforation with endoclips in 1997.^[8] As the endoclip application became more widespread, several cases describing successful endoscopic closure of colonic perforations have been reported lately.^[9] The 2017 World Society of Emergency Surgery guideline [Figure 4] suggests endoscopic closure be reserved for patients with small perforations (<20 mm), good bowel preparation, and minimal peritoneal signs.^[10] With growing experience, endoscopic clipping has been applied for closure of larger (>30 mm) defects as well.^[9] Close hemodynamic monitoring, broad-spectrum antibiotics and nil per orally form an essential part of the management plan till bowel function returns.^[10] The superficial apposition of colon wall seems sufficient for the healing of perforation, and the reported success rate with this approach ranges from 69% to 93%.^[4] The risk factors associated with the need for early surgical intervention after endoscopic clip closure includes large perforation size, leukocytosis, fever, severe abdominal pain, and a large amount of free peritoneal air.^[9] Endoscopic suture closure of colonic perforations been shown to be feasible, and can even be more effective than clipping, but experience with this technique is limited.^[11]

The endoscopic clipping is a safe technique that eliminates the risk of general anesthesia and emergency surgery in patients with iatrogenic colon perforation. Although multiple clips were utilized for closure of perforation in our case, the overall cost of treatment was still low and affordable to the patient. This was due to the application of standard hemoclips with reusable deployment device instead of expensive alternatives such as endosutures or “bear claw” over-the-scope clips.

CONCLUSION

Endoscopic clipping can be an easy, safe, and effective alternative to surgery in the management of iatrogenic colonic perforation. The prerequisites for the success of this approach include early intervention, smaller defect size, prepared bowel, and minimal peritoneal contamination.

Declaration of patient consent

The authors certify that they have obtained all appropriate patient consent forms. In the form the patient(s) has/have given his/her/their consent for his/her/their images and other clinical information to be reported in the journal. The patients understand that their names and initials will not be published and due efforts will be made to conceal their identity, but anonymity cannot be guaranteed.

Financial support and sponsorship

Nil.

Conflicts of interest

There are no conflicts of interest.

REFERENCES

1. Clements RH, Jordan LM, Webb WA. Critical decisions in the management of endoscopic perforations of the colon. *Am Surg* 2000;66:91-3.
2. Repici A, Pellicano R, Strangio G, Danese S, Fagoonee S, Malesci A, *et al.* Endoscopic mucosal resection for early colorectal neoplasia: Pathologic basis, procedures, and outcomes. *Dis Colon Rectum* 2009;52:1502-15.
3. Lohsiriwat V. Colonoscopic perforation: Incidence, risk factors, management and outcome. *World J Gastroenterol* 2010;16:425-30.
4. Cai SL, Chen T, Yao LQ, Zhong YS. Management of iatrogenic colorectal perforation: From surgery to endoscopy. *World J Gastrointest Endosc* 2015;7:819-23.
5. Lüning TH, Keemers-Gels ME, Barendregt WB, Tan AC, Rosman C. Colonoscopic perforations: A review of 30,366 patients. *Surg Endosc* 2007;21:994-7.
6. Panteris V, Haringsma J, Kuipers EJ. Colonoscopy perforation rate, mechanisms and outcome: From diagnostic to therapeutic colonoscopy. *Endoscopy* 2009;41:941-51.
7. Bleier JI, Moon V, Feingold D, Whelan RL, Arnell T, Sonoda T, *et al.* Initial repair of iatrogenic colon perforation using laparoscopic methods. *Surg Endosc* 2008;22:646-9.
8. Yoshikane H, Hidano H, Sakakibara A, Ayakawa T, Mori S, Kawashima H, *et al.* Endoscopic repair by clipping of iatrogenic colonic perforation. *Gastrointest Endosc*. 1997;46:464-6.
9. Cho SB, Lee WS, Joo YE, Kim HR, Park SW, Park CH, *et al.* Therapeutic options for iatrogenic colon perforation: Feasibility of endoscopic clip closure and predictors of the need for early surgery. *Surg Endosc* 2012;26:473-9.
10. de'Angelis N, Di Saverio S, Chiara O, Sartelli M, Martínez-Pérez A, Patrizi F, *et al.* 2017 WSES guidelines for the management of iatrogenic colonoscopy perforation. *World J Emerg Surg* 2018;13:5.
11. Kantsevov SV, Bitner M, Hajiyeva G, Mirovski PM, Cox ME, Swope T, *et al.* Endoscopic management of colonic perforations: Clips versus suturing closure (with videos). *Gastrointest Endosc* 2016;84:487-93.