

## Case Report

# Giant Gastroduodenal Trichobezoar: An Endoscopic Surprise

Ashish Kumar Jha, Manish Kumar Mishra, Rakesh Kumar<sup>1</sup>, Madhur Chaudhary, Shubham Purkayastha, Praveen Jha, Nazis Raza

Departments of  
Gastroenterology and  
<sup>1</sup>Gastrointestinal Surgery,  
Indira Gandhi Institute of  
Medical Sciences, Patna,  
Bihar, India

### ABSTRACT

A trichobezoar is a rare condition, mostly seen in teenage girls with abnormal psychiatric behavior of eating hairs and nails (trichophagia). Trichobezoar may rarely present with nonspecific abdominal symptoms without obvious trichotillomania and trichophagia. Trichobezoar can be complicated with potentially serious conditions such as gastric outlet obstruction, gastric bleeding, intussusceptions, and perforation peritonitis. Conventional laparotomy is method of choice for the removal of trichobezoar. We describe a rare case of giant trichobezoar treated by laparoscopic-assisted gastrotomy and removal of bezoar. We also reviewed the literature on the current status of endoscopic treatment of trichobezoar.

**KEYWORDS:** Endoscopic treatment, Rapunzel syndrome, trichobezoar

## INTRODUCTION

A trichobezoar is a rare condition consisting of a hair ball in the proximal gastrointestinal tract. It is mostly seen in teenage girls with abnormal psychiatric behavior of eating hairs and nails (trichophagia). Trichotillomania, a psychiatric disorder characterized by the compulsory and persistent pulling out of one's hair, leads to noticeable hair loss.<sup>[1]</sup> The trichobezoar is mostly confined within the gastric lumen. Rapunzel syndrome is a rare form of trichobezoar with a long tail which may extend up to the jejunum or beyond.<sup>[2]</sup> The prevalence rate varies from 0.06% to 4%. We describe a rare case of giant trichobezoar treated by laparoscopic-assisted removal of bezoar. We also reviewed the literature on the current status of endoscopic treatment of trichobezoar.

## CASE REPORT

A 13-year-old girl presented with pain abdomen, anorexia, infrequent vomiting, weight loss, and constipation for 2 years. There was no history of abdominal distension or fever. History of prior abdominal surgery and other chronic illness was absent. Multiple soft nontender nodules were palpable in epigastrium and left hypogastrium. Abdominal computed tomography (CT)-scan showed an inhomogeneous mass with scattered calcification in stomach extending up to duodenal lumen. Endoscopy showed a large hair ball (trichobezoar) almost

completely occupied the stomach [Figure 1]. Hair ball extending from gastroesophageal junction and entered into duodenum [Figure 1a, b and c]. Distal extent of hair ball could not be visualized because endoscope was not negotiable through pylorus due to blocked pyloric opening [Figure 1c]. Diagnosis of trichobezoar was confirmed. The patient denied eating hairs, though her hair density was sparse. In view of large size of bezoar, endoscopic removal was not tried. Laparoscopic-assisted gastrotomy and removal of trichobezoar (size 26 cm × 8 cm) [Figure 2] were successfully performed. The patient was discharged in a healthy condition. The patient was referred to psychiatrist for counseling.

## DISCUSSION

The patient with trichobezoar remains asymptomatic for many years. Large-sized trichobezoar usually presents with symptoms of gastrointestinal obstruction. The most common presenting clinical symptoms and signs are abdominal pain, vomiting, constipation, and weight loss. Bezoar can be complicated with gastric ulceration,

**Address for correspondence:** Dr. Ashish Kumar Jha,  
Department of Gastroenterology, Indira Gandhi Institute  
of Medical Sciences, Sheikhpura, Patna - 14, Bihar, India.  
E-mail: ashishjhabn@yahoo.co.in

This is an open access journal, and articles are distributed under the terms of the Creative Commons Attribution-NonCommercial-ShareAlike 4.0 License, which allows others to remix, tweak, and build upon the work non-commercially, as long as appropriate credit is given and the new creations are licensed under the identical terms.

**For reprints contact:** reprints@medknow.com

**How to cite this article:** Jha AK, Mishra MK, Kumar R, Chaudhary M, Purkayastha S, Jha P, et al. Giant gastroduodenal trichobezoar: An endoscopic surprise. *J Dig Endosc* 2018;9:131-3.

### Access this article online

#### Quick Response Code:



**Website:** www.jdeonline.in

**DOI:** 10.4103/jde.JDE\_2\_18

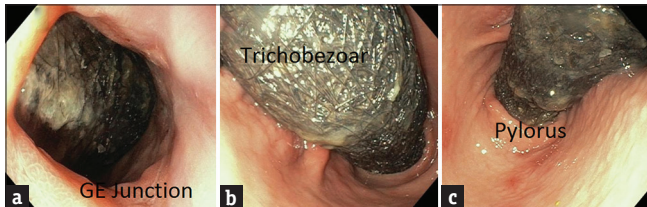
gastric bleeding, intussusceptions, perforation peritonitis, obstructive jaundice, acute pancreatitis, gastric emphysema, protein-losing enteropathy, iron deficiency, and megaloblastic anemia.<sup>[1,2]</sup>

History of associated psychiatric disorders and patchy alopecia provide useful clues for the diagnosis of trichobezoar. However, the patient may conceal history of pulling out (trichotillomania) and eating their own hair (trichophagia). History of trichophagia is absent in nearly half of the patients of trichobezoar. History of trichophagia was concealed by our patient. The investigation of choice in the diagnosis of trichobezoar is endoscopy. Endoscopic diagnosis of trichobezoar is sometimes very surprising, especially in the absence of trichotillomania and trichophagia. Abdominal ultrasound and CT scan may show inhomogeneous mass or filling defect in gastric lumen with or without calcification.

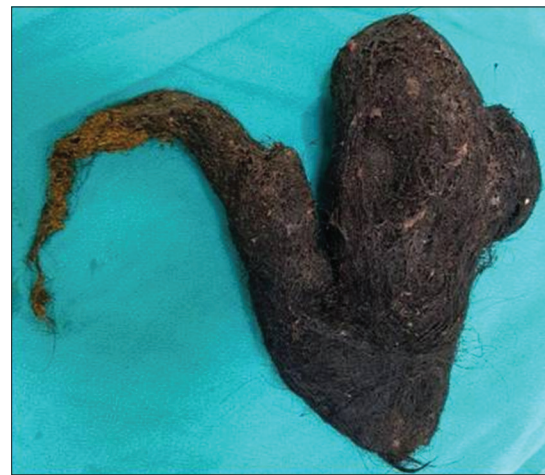The treatment may include medical, conventional laparotomy, laparoscopy, and endoscopic methods.<sup>[1]</sup> Psychiatric consultation is essential to prevent relapses. Medical treatments such as intragastric installation of enzyme, sodium bicarbonate, and coca cola have been tried without any consistent success. Conventional laparotomy is method of choice for the removal of trichobezoar.<sup>[1,2]</sup> Surgical removal is performed by

gastrostomy or enterotomy. Laparoscopy techniques have been described for removal of small- to moderate-sized bezoars.<sup>[3,4]</sup> Laparoscopic removal of large bezoars is difficult. Other problems of laparoscopy include longer operation time, the risk of migration of bezoars toward ileum, and the risk of spilling contaminated hair fragments into the abdominal cavity.<sup>[1,2]</sup>

Recently, endoscopic removal of trichobezoars of smaller size has been described in a few case reports.<sup>[5-10]</sup> Endoscopic removal is based on the use of intragastric chemical substances (sodium bicarbonate) to dissolve the material, mechanical fragmentation, and removal of bezoars with repeated endoscopy. The details of the endoscopic techniques are summarized in Table 1. Endoscopic technique has very low success rate (5%). The following factors are responsible for the poor result of endoscopic removal of trichobezoars: (a) endoscopic removal is



**Figure 1:** Endoscopy images showing giant gastroduodenal trichobezoar [(a) Gastroesophageal junction, (b) Body and antrum, and (c) Entering the duodenum through the pyloric canal]



**Figure 2:** Surgical specimen of trichobezoar casted in shape of stomach and duodenum

**Table 1: Endoscopic treatment of trichobezoar**

References	Age (years/sex)	Size (cm)	Endoscopic devices used	Sessions/number of passes of endoscope/procedure duration
Zhao et al. <sup>[5]</sup>	12/female	10.5×3.5	Endoscopic scissors, APC	Two sessions
Benatta <sup>[6]</sup>	6/female	8×4	Polypectomy snare	1 h
			Polypectomy snare, APC	15 passes
				50 min
Konuma et al. <sup>[7]</sup>	9/female	1.8×3.2×3.4	Polypectomy snare, net	Two passes
				15 min
Aybar and Safta <sup>[8]</sup>	5/female	8×7	Hot biopsy forceps, snare	25 passes
				3 h
Saeed et al. <sup>[9]</sup>	54/male	12	Two-channel endoscope, overtube, grasping forceps	Single session
				30 min
Soehendra <sup>[10]</sup>	17/female	15×7	Nd: YAG laser	>100 passes
				Three sessions of 2-3 h

APC=Argon plasma coagulation, Nd: YAG=Neodymium-doped yttrium aluminum garnet

a tedious procedure, (b) carries risk of complications such as pressure ulceration, esophagitis, and even esophageal perforation due to repeated introduction of the endoscope, and (c) hair ball can migrate distally and obstruct intestine.

In conclusion, trichobezoar is a rare and potentially serious disease. Trichobezoar may present with nonspecific abdominal symptoms without obvious trichotillomania and trichophagia. A young female presenting with unexplained abdominal symptoms should be evaluated for trichobezoar.

#### **Declaration of patient consent**

The authors certify that they have obtained all appropriate patient consent forms. In the form the patient(s) has/have given his/her/their consent for his/her/their images and other clinical information to be reported in the journal. The patients understand that their names and initials will not be published and due efforts will be made to conceal their identity, but anonymity cannot be guaranteed.

#### **Financial support and sponsorship**

Nil.

#### **Conflicts of interest**

There are no conflicts of interest.

## **REFERENCES**

1. Gorter RR, Kneepkens CM, Mattens EC, Aronson DC, Heij HA. Management of trichobezoar: Case report and literature review. *Pediatr Surg Int* 2010;26:457-63.
2. Gonuguntla V, Joshi DD. Rapunzel syndrome: A comprehensive review of an unusual case of trichobezoar. *Clin Med Res* 2009;7:99-102.
3. Nirasawa Y, Mori T, Ito Y, Tanaka H, Seki N, Atomi Y, *et al.* Laparoscopic removal of a large gastric trichobezoar. *J Pediatr Surg* 1998;33:663-5.
4. Tudor EC, Clark MC. Laparoscopic-assisted removal of gastric trichobezoar; a novel technique to reduce operative complications and time. *J Pediatr Surg* 2013;48:e13-5.
5. Zhao JL, Zhao WC, Wang YS. Endoscopic retrieval of gastric trichophytobezoar: Case report of a 12-year-old girl with trichophagia. *Medicine (Baltimore)* 2017;96:e5969.
6. Benatta MA. Endoscopic retrieval of gastric trichobezoar after fragmentation with electrocautery using polypectomy snare and argon plasma coagulation in a pediatric patient. *Gastroenterol Rep (Oxf)* 2016;4:251-3.
7. Konuma H, Fu K, Morimoto T, Shimizu T, Izumi Y, Shiyanagi S, *et al.* Endoscopic retrieval of a gastric trichobezoar. *World J Gastrointest Endosc* 2011;3:20-2.
8. Aybar A, Safta AM. Endoscopic removal of a gastric trichobezoar in a pediatric patient. *Gastrointest Endosc* 2011;74:435-7.
9. Saeed ZA, Ramirez FC, Hepps KS, Dixon WB. A method for the endoscopic retrieval of trichobezoars. *Gastrointest Endosc* 1993;39:698-700.
10. Soehendra N. Endoscopic removal of a trichobezoar. *Endoscopy* 1989;21:201.