

Case Report

Endoscopic Resection of a Giant Pedunculated Leiomyoma of the Sigmoid Colon

Gianluca Andrisani, Margherita Pizzicannella, Chiara Taffon¹, Francesco Maria Di Matteo

Digestive Endoscopy Unit,
Campus Bio-Medico,
¹Department of Pathology,
Campus Bio-Medico, Rome,
Italy

ABSTRACT

The leiomyoma is a benign smooth muscle tumor and may occur throughout the entire digestive tract, more frequently in the stomach, and small intestine, but is rarely seen in large bowel. Furthermore, a colonic giant pedunculated leiomyoma is very rare. The traditional management option for a colonic leiomyoma is surgical resection. However, the endoloop-assisted polypectomy could be the treatment of choice even for very large lesions.

KEYWORDS: *Colonoscopy, endoscopic therapy, pedunculated leiomyoma*

INTRODUCTION

Leiomyomas of the large bowel represent just 3% of all gastrointestinal leiomyomas. Moreover, pedunculated leiomyoma is rare, and the reported average size is <1 cm. A complete endoscopic resection is technically difficult in reason of its submucosal origin, especially in case of giant lesion.

CASE REPORT

A 69-year-old female for frequent abdominal pain and worsening constipation performed a virtual colonoscopy that demonstrated a 3.7 cm pedunculated polyp of the sigmoid colon [Figure 1a]. She was referred to our hospital to perform a colonoscopy that revealed a giant pedunculated polyp with long and wide stalk of the rectosigmoid junction [Figure 1b]. The overlying mucosa seems to be normal. Given the patient's symptoms and considering the size and location of the lesion, endoscopic resection was performed. First, an Endoloop (Olympus, Tokyo, Japan) was applied and released at the base of the stalk, then endoscopic resection with snare (9203F-40, Soehendra, EndoBair) was performed with a VIO-300-HF Unit (Erbe, Tubingen, Germany) set at EndoCut Q, 120W, effect 3. Two endoclips (EZ Long, Olympus) were released to close the mucosal wound [Figure 1c]. No complications occurred. Histopathological examination demonstrated a normal intestinal mucosa overlying focal crypt hyperplasia with the proliferation of smooth-muscle-fibrocells with no atypia and a negative submucosa layer. Immunohistological findings

were negative for CD34, CD117, DOG, S-100 protein, but positive for desmin and smooth muscle actin. The proliferation index Ki67 was <1% [Figure 2]. The polyp was diagnosed as a pedunculated intramucosal leiomyoma.

DISCUSSION

Leiomyoma is a benign smooth muscle tumor, first described by Virchow in 1854.^[1] It arises from the muscularis mucosa, muscularis propria, or vascular smooth muscle. Most gastrointestinal leiomyomas occur in the stomach or the small intestine, while the large bowel, accounts for only 3%,^[2] more frequently in the sigmoid and transverse colon.^[3] The majority of leiomyomas described are sessile intraluminal or intramural tumors, with a normal overlying mucosa. Pedunculated type is rare. The peak incidence occurs in the third decade of life with a slight female prevalence. Usually, colonic leiomyomas are asymptomatic and detected as occasional findings. However, they can cause abdominal pain, intestinal obstruction, rectal bleeding, and perforation.^[4]

Complete excision is mandatory for an adequate diagnosis and treatment in most patients. Endoscopic resection of leiomyomas is often unsafe, especially in case of large lesions, due to possible complications such as perforation or bleeding.

Address for correspondence: Dr. Gianluca Andrisani, Digestive Endoscopy Unit, Campus Bio-Medico, Rome, Italy.
E-mail: gianluca.andrisani@gmail.com

Access this article online

Quick Response Code:



Website: www.jdeonline.in

DOI: 10.4103/jde.JDE_68_16

This is an open access article distributed under the terms of the Creative Commons Attribution-NonCommercial-ShareAlike 3.0 License, which allows others to remix, tweak, and build upon the work non-commercially, as long as the author is credited and the new creations are licensed under the identical terms.

For reprints contact: reprints@medknow.com

How to cite this article: Andrisani G, Pizzicannella M, Taffon C, Di Matteo FM. Endoscopic resection of a giant pedunculated leiomyoma of the sigmoid colon. *J Dig Endosc* 2017;8:140-1.

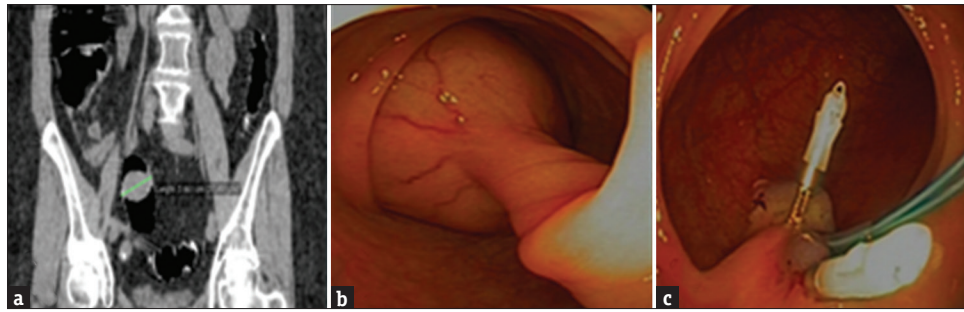


Figure 1: (a) Virtual colonoscopy showing the 3.7 cm pedunculated polyp of the sigmoid colon; (b) Endoscopic image of the giant pedunculated polyp; (c) Endoscopic image after polyp resection with the Endoloop (Olympus, Tokyo, Japan) at the base of the stalk and two endoclips (EZ Long, Olympus) closing the mucosal wound




Figure 2: Histopathological findings (a) H and E, ×2 showing normal intestinal mucosa overlying focal crypt hyperplasia and the smooth-muscle-fibrocells proliferation; (b) Immunohistology positive for smooth muscle actin; (c) H and E, ×20: Magnification of the smooth-muscle-fibrocells

Our case is notable because the peduncolated leiomyomas^[5] are rare and the endoscopic resection is described only for few cases with size less than 1 cm. This case illustrates the safety and feasibility of endoloop-assisted polypectomy of giant pedunculated leiomyomas. The procedure took about 10 min, and there were no complications. Therefore, we suggest to evaluate, in case of large pedunculated polyps, the feasibility of endoloop-assisted polypectomy for both treatment and diagnosis.

Financial support and sponsorship

Nil.

Conflicts of interest

There are no conflicts of interest.

REFERENCES

1. Xu GQ, Zhang BL, Li YM, Chen LH, Ji F, Chen WX, *et al.* Diagnostic value of endoscopic ultrasonography for gastrointestinal leiomyoma. *World J Gastroenterol* 2003;9:2088-91.
2. Baker HL Jr., Good CA. Smoothmuscle tumors of the alimentary tract; Their roentgen manifestations. *Am J Roentgenol Radium Ther Nucl Med* 1955;74:246-55.
3. Hatch KF, Blanchard DK, Hatch GF 3rd, Wertheimer-Hatch L, Davis GB, Foster RS Jr., *et al.* Tumors of the appendix and colon. *World J Surg* 2000;24:430-6.
4. Chow WH, Kwan WK, Ng WF. Endoscopic removal of leiomyoma of the colon. *Hong Kong Med J* 1997;3:325-7.
5. Kemp CD, Arnold CA, Torbenson MS, Stein EM. An unusual polyp: A pedunculated leiomyoma of the sigmoid colon. *Endoscopy* 2011;43 Suppl 2 UCTN:E306-7. doi: 10.1055/s-0030-1256640.