

## Case Report

# Bilioptysis – Two Case Reports of Broncho Biliary Fistula

Pugazhendhi Thangavelu, Manoj Munirathinam, Ratnakar Kini

Institute of Medical  
Gastroenterology,  
Rajiv Gandhi Government  
General Hospital,  
Madras Medical College,  
Chennai, Tamil Nadu, India

ABSTRACT

Bronchobiliary fistula (BBF) is a tract between the biliary system and bronchial tree with the presence of bile in the bronchus and the sputum. They are rare but serious complications. In most cases, they are caused by hepatic or subphrenic abscesses, resulting from different conditions. Pulmonary symptoms dominate the clinical picture, and the main manifestations are chronic irritant cough, production of greenish sputum, bronchopneumonia, and dyspnea. The diagnosis of BBF can be confirmed by imaging procedures such as biliary scintigraphy with hepatobiliary iminodiacetic acid, percutaneous transhepatic cholangiography, or endoscopic retrograde cholangiopancreatography. Bronchoscopy can demonstrate the presence of bile in the bronchial tree and may delineate the site of fistula. The treatment strategy for patients with BBF and biliary tract obstruction is the reestablishment of bile drainage, which allows the fistula to heal by reducing intrabiliary pressure. We present two cases of biliary-bronchial fistula, one related to hepatic abscess and the other due to percutaneous transhepatic biliary drainage for common bile duct obstruction secondary to inoperable hilar cholangiocarcinoma.

**KEYWORDS:** *Bilioptysis, bronchobiliary fistula, hepatobiliary iminodiacetic acid scan*

## INTRODUCTION

Bronchobiliary fistula is a very rare entity seen in clinical practice. Bilioptysis (coughing up of green coloured sputum containing bile) is a pathognomonic sign. We report two interesting patients presenting with bronchobiliary fistula to our hospital.

## CASE REPORTS

### Case report 1

A 39-year-old male presented with cough and copious greenish sputum (about 150 ml/day) and breathlessness of 1-month duration. He also had abdominal discomfort, and there was no hemoptysis. He had liver abscess complicated by jaundice, and surgical drainage was done 2 years back following which he did not have relief of symptoms. Hence, he underwent laparotomy with peritoneal lavage and external drainage with cholecystostomy was performed following which he developed controlled external biliary fistula. Subsequently, a Roux-en-Y fistula-jejunostomy was done. He remained asymptomatic for almost a year before he developed cough and greenish sputum. On

examination, he had a scarred abdomen and incisional hernia due to previous surgeries. Bronchoscopy revealed bile in bronchi and trachea. Magnetic resonance imaging/magnetic resonance cholangiopancreatography (MRCP) showed right anterior prehepatic collection with a fistulous communication between the collection and right lobe liver along with collapse consolidation of right middle lobe of the lung. Hepatobiliary iminodiacetic acid (HIDA) scan revealed abnormal tracer tracking upward from the liver into the right bronchus and trachea reaching up to the mouth [Figure 1]. The patient had presented about a year after fistulojejunostomy probably due to nonfunctioning or anastomotic stricture of the fistulojejunostomy. He was subjected to endoscopic retrograde cholangiopancreatography (ERCP), and single 7-Fr 8 cm double pigtail stent was placed in the right hepatic system. His sputum production gradually decreased, and from the 10<sup>th</sup> day of stenting, he had

**Address for correspondence:** Dr. Manoj Munirathinam,  
No. 14, Nolambur Phase 2, Mogappair West, Chennai - 600 037,  
Tamil Nadu, India.  
E-mail: medmanoj@yahoo.co.in

Access this article online

Quick Response Code:



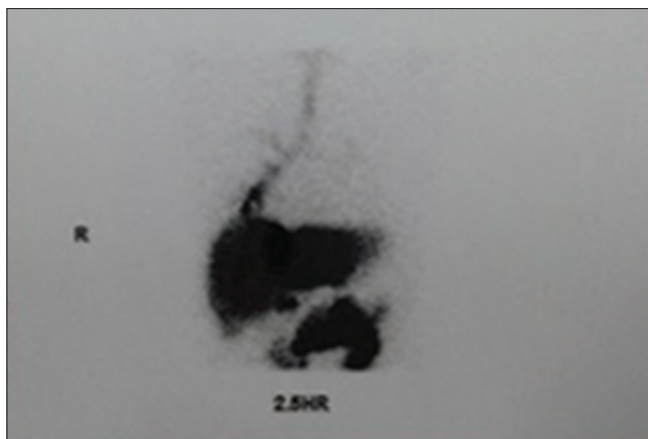
Website: [www.jdeonline.in](http://www.jdeonline.in)

DOI: 10.4103/jde.JDE\_6\_17

This is an open access article distributed under the terms of the Creative Commons Attribution-NonCommercial-ShareAlike 3.0 License, which allows others to remix, tweak, and build upon the work non-commercially, as long as the author is credited and the new creations are licensed under the identical terms.

For reprints contact: [reprints@medknow.com](mailto:reprints@medknow.com)

**How to cite this article:** Thangavelu P, Munirathinam M, Kini R. Bilioptysis – Two case reports of broncho biliary fistula. *J Dig Endosc* 2017;8:190-2.



**Figure 1:** Hepatobiliary iminodiacetic acid scan showing abnormal clearance of tracer and fistulous communication tracking upward to the lung

total relief. Patient is on regular follow-up, and stent exchange has been twice till date.

### Case report 2

A 35-year-old male had extrahepatic cholestasis since 2 months, and MRCP revealed stricturous lesion involving both hepatic ducts and common bile duct consistent with hilar cholangiocarcinoma. Diagnostic laparoscopy showed multiple liver metastasis and minimal ascites. Hence, percutaneous transhepatic biliary drainage (PTBD) (internal and external) was performed as a palliative measure. Four weeks later, he developed right lower lobe consolidation with cough/greenish sputum and breathlessness. His sputum analysis showed presence of bile. Bronchoscopy also confirmed the presence of bile in the right bronchus. The liver function test revealed an elevated serum alkaline phosphatase (513 IU/L). His chest X-ray showed right lower zone haziness. Since the drain was obstructed, he was referred for endotherapy. ERCP showed collection of contrast in subdiaphragmatic region. His PTBD drain was removed and 7-Fr 8 cm double pigtail stents were placed in each system. Subsequently, consolidation was gradually resolved, and symptoms improved over next 2 weeks. He had minimal ooze of bile from the cutaneous fistulous tract of PTBD site which also resolved spontaneously. Patient had reviewed a month after the procedure and was doing well but was lost to follow up since then.

### DISCUSSION

A bronchobiliary fistula (BBF) is defined as an abnormal communication between the bronchial tree and the biliary system.<sup>[1,2]</sup> BBF may be caused by hepatic abscess, trauma, surgery, neoplasm, and echinococcus of the liver. Peacock was the first person to describe a case of BBF in a patient with hydatid disease of the liver in the year 1850. Bilioptysis is the presence of bile in the sputum and is a pathognomonic sign of a BBF.<sup>[3-5]</sup>

The most common cause of a BBF is a liver abscess.<sup>[1]</sup> The pathogenesis of BBF caused by bile duct obstruction probably involves a local inflammatory processes (cholangitis), followed by intrahepatic abscess formation and rupture of these abscess into the pleural space or if adhesions exist, into the bronchial tree. This explains the preferential location of BBFs in the right side of the chest. Most fistulae involve the right basilar segments of the lung. The intense inflammatory reaction of the bronchial mucosa secondary to bile can cause acute pneumonitis or bronchiolitis or even chronic bronchopneumonia. The classic clinical presentation is irritant cough. There are two mechanisms involved in the pathogenesis. In the first mechanism, the biliary tract obstruction is the primary reason for fistula formation. The obstruction may be due to scars (trauma, surgery, postradiation, etc.), inflammatory diseases, foreign bodies, primary tumors, metastases, or granulomas of different etiologies, which obstruct the bile ducts. The result is the retention of bile proximal to the barrier, the formation of a liver biloma, and subsequently the abscess formation. By increasing, the abscess gradually erodes the diaphragm. In case of adhesions between the lower lung lobe and the diaphragm (due to previous pleural or lung pathology), the abscess erodes directly into the lung parenchyma until it reaches the nearest bronchus and a BBF is formed. When no previous pleural pathology is present, the abscess gradually erodes into the pleural space and a pleurobiliary fistula (PBF) with pleural empyema is formed. In the second case, the formation of a thoracobiliary fistula takes place without biliary tract obstruction. In this case, a hydatid cyst or a liver abscess is the primary reason for the fistula formation. The abscess can be echinococcus (most often), amoebic, or pyogenic in origin. As described above, the cyst or the abscess gradually enlarges and erodes the diaphragm. Depending on the previous state of the pleural space, a BBF or a PBF is formed. The predilection point for the fistula formation is the posteromedial part of the right hemidiaphragm. The diagnosis can be confirmed by imaging procedures such as biliary scintigraphy with HIDA scan, percutaneous transhepatic cholangiography (PTC), or ERCP. Bronchoscopy rarely demonstrates the fistula, but in our case, it was helpful because bile was found in the right bronchial tree. Ultrasonography and computed tomography abdomen can help in the detection of associated pathological conditions such as abscess, biloma, stones, or tumors. However, PTC and ERCP are the diagnostic studies of choice and offer the possibility of therapeutic intervention. The most definitive and curative procedure for BBF is surgical fistulectomy with soft tissue reconstruction, but this approach is accompanied by significant morbidity,

mortality, and frequent reoperations.<sup>[1]</sup> Hence, in recent days, conservative interventions have been the preferred modality of treatment. Most of the interventions aim to lower biliary tract pressure; endoscopic biliary drainage or PTBD is the preferred approach.<sup>[3]</sup> Most patients respond well to these approaches.

Nasobiliary drainage or endoscopic sphincterotomy with biliary endoprosthesis is the techniques available currently. These techniques have excellent results in the treatment of postoperative and posttraumatic biliary leaks<sup>[6-9]</sup> and the initial treatment of choice in these conditions. The main objective of these endoscopic interventions in bile leaks or fistulas is to abolish the pressure gradient across the sphincter of Oddi, thereby promoting preferential bile flow into the duodenum and allowing the leak to heal.<sup>[10]</sup> Nasobiliary drainage<sup>[11-13]</sup> or endoscopic sphincterotomy with or without stenting<sup>[14]</sup> has been reported to be successful in treating BBFs.

Endoscopic sphincterotomy alone or combination of papillotomy plus stenting may be done to abolish the pressure gradient across the sphincter of Oddi and facilitate biliary drainage. The complications of the procedure are post-ERCP pancreatitis, hemorrhage, or duodenal perforation.

Other alternative interventional approaches have also been proposed for the treatment of BBF. Successful percutaneous embolization was done in three patients with biliary fistulas by Hunt *et al.* using different types of coils where other techniques were contraindicated.<sup>[15]</sup> Görich *et al.*<sup>[16]</sup> have reported the definite treatment of biliary fistulas in four patients by percutaneous transhepatic embolization using tissue adhesives.

## CONCLUSION

If a malignant disease causing BBF is diagnosed, conservative approaches such as biliary stent or biliary decompression with endoscopic sphincterotomy may provide sufficient palliation since the life expectancy is short. However, in patients whom the obstruction is due to a benign disease, such as lithiasis or hydatid cyst, and sufficient drainage cannot be achieved, surgical intervention which has a higher success rate may be recommended.<sup>[11,17]</sup> In our report, we emphasize the role of ERCP and stenting as one of the important nonsurgical modalities of the treatment of BBF.

## Financial support and sponsorship

Nil.

## Conflicts of interest

There are no conflicts of interest.

## REFERENCES

- Borrie J, Shaw JH. Hepatobronchial fistula caused by hydatid disease. The Dunedin experience 1952-79. *Thorax* 1981;36:25-8.
- Rose DM, Rose AT, Chapman WC, Wright JK, Lopez RR, Pinson CW. Management of bronchobiliary fistula as a late complication of hepatic resection. *Am Surg* 1998;64:873-6.
- Khandelwal M, Inverso N, Conter R, Campbell D. Endoscopic management of a bronchobiliary fistula. *J Clin Gastroenterol* 1996;23:125-7.
- Gerazounis M, Athanassiadi K, Metaxas E, Athanassiou M, Kalantzi N. Bronchobiliary fistulae due to echinococcosis. *Eur J Cardiothorac Surg* 2002;22:306-8.
- Chua HK, Allen MS, Deschamps C, Miller DL, Pairolero PC. Bronchobiliary fistula: Principles of management. *Ann Thorac Surg* 2000;70:1392-4.
- Chow S, Bosco JJ, Heiss FW, Shea JA, Qaseem T, Howell D. Successful treatment of post-cholecystectomy bile leaks using nasobiliary tube drainage and sphincterotomy. *Am J Gastroenterol* 1997;92:1839-43.
- Sugiyama M, Atomi Y, Matsuoka T, Yamaguchi Y. Endoscopic biliary stenting for treatment of persistent biliary fistula after blunt hepatic injury. *Gastrointest Endosc* 2000;51:42-4.
- Rauws EA, Gouma DJ. Endoscopic and surgical management of bile duct injury after laparoscopic cholecystectomy. *Best Pract Res Clin Gastroenterol* 2004;18:829-46.
- Katsinelos P, Kountouras J, Paroutoglou G, Beltsis A, Zavos C, Chatzimavroudis G, *et al.* The role of endoscopic treatment in postoperative bile leaks. *Hepatogastroenterology* 2006;53:166-70.
- Bjorkman DJ, Carr-Locke DL, Lichtenstein DR, Ferrari AP, Slivka A, Van Dam J, *et al.* Postsurgical bile leaks: Endoscopic obliteration of the transpapillary pressure gradient is enough. *Am J Gastroenterol* 1995;90:2128-33.
- Partrinou V, Dougenis D, Kritikos N, Polydorou A, Vagianos C. Treatment of postoperative bronchobiliary fistula by nasobiliary drainage. *Surg Endosc* 2001;15:758.
- Ragozzino A, De Rosa R, Galdiero R, Maio A, Manes G. Bronchobiliary fistula evaluated with magnetic resonance imaging. *Acta Radiol* 2005;46:452-4.
- Ertugrul I, Köklü S, Köksal AS, Coban S, Basar O, Ibis M, *et al.* Treatment of bronchobiliary fistula due to an infected hydatid cyst by a nonsurgical approach. *Dig Dis Sci* 2004;49:1595-7.
- D'Altorio RA, McAllister JD, Sestric GB, Cichon PJ. Hepatopulmonary fistula: Treatment with biliary metallic endoprosthesis. *Am J Gastroenterol* 1992;87:784-6.
- Hunt JA, Gallagher PJ, Heintze SW, Waugh R, Shiel GR. Percutaneous microcoil embolization of intraperitoneal intrahepatic and extrahepatic biliary fistulas. *Aust N Z J Surg* 1997;67:424-7.
- Görich J, Rilinger N, Sokiranski R, Siech M, Vogel J, Wikström M, *et al.* Percutaneous transhepatic embolization of bile duct fistulas. *J Vasc Interv Radiol* 1996;7:435-8.
- Johnson MM, Chin R Jr., Haponik EF. Thoracobiliary fistula. *South Med J* 1996;89:335-9.