

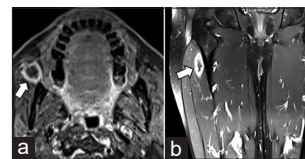
## Letter to the Editor

### Metachronous muscle metastasis in a case of metastatic gallbladder cancer with TP35 gene mutation: A rare case report

DOI: 10.4103/sajc.sajc\_139\_19

Dear Editor,

Gallbladder carcinoma (GBCA) is the most common and aggressive type of biliary tract cancer. Surgery offers the only chance of cure. However, only 10% of patients have resectable disease at presentation.<sup>[1]</sup> The spread modes of GBCA are direct, lymphatic, vascular, neural, intraperitoneal, and intraductal. Liver and lymph nodes are the two most common sites of metastasis of GBCA.<sup>[2,3]</sup> Metastasis to other organs such as bone and lung is very uncommon.<sup>[4]</sup> Here, we present a case of GBCA who developed muscle metastasis twice during his treatment. This is an extremely rare finding, and only a single case report exists before this publication.<sup>[5]</sup>



**Figure 1: (a) Axial T1-weighted fat-saturated contrast-enhanced magnetic resonance imaging of the face showing a small peripherally enhancing nodule (arrow) in the anterior portion of the right masseter muscle; (b) coronal T1-weighted fat-saturated contrast-enhanced magnetic resonance imaging of thighs showing a similar peripherally enhancing elongated nodule (arrow) in the quadriceps femoris muscle**

In January 2018, a 55-year-old male, hypertensive, presented to us with the complaints of right upper quadrant abdominal pain for 2 months. He also had a weight loss of 10 kg in the last 3 months. Ultrasound of the abdomen showed a gallbladder lesion of size 6.3 cm × 6.1 cm in the right lobe of the liver close to gallbladder fossa. He was evaluated at our center with a contrast-enhanced magnetic resonance imaging (MRI) scan of the upper abdomen, which showed a mass in segment 4a/4b/5 of

*(Continue on page 246...)*

(Letter to the editor continue from page 240...)

the liver with heterogeneous peripheral enhancement and filling in on delayed sequences with peripheral restricted diffusion features, suggestive of GBCA. A small lesion in segment V of the liver was also seen, which was consistent with metastasis. Baseline staging with contrast computed tomography (CT) was done, which did not show any distant metastasis. A guided biopsy confirmed adenocarcinoma, consistent with GBCA. Focused exome sequencing revealed that he was positive for in-del mutation in exon 8 of the TP53 gene.

His routine complete blood counts were normal; renal function as well as liver functions were normal, except mildly elevated alkaline phosphatase of 465 (38–126) U/L. However, he did not have any bone pain. Considering the diagnosis of metastatic GBCA, he was started on systemic chemotherapy with palliative intent, with doublet gemcitabine and oxaliplatin (mGEMOX) from February 2018. He tolerated his chemotherapy cycles well.

After the first cycle of chemotherapy, he complained of pain in the right cheek with a hard painful swelling, leading to trismus. On examination, he has a hard swelling fixed to the masseter muscle. MRI of the face revealed a well-defined complex lesion measuring 1.7 cm × 1.7 cm × 1.6 cm with cystic and solid components within the buccal space anterior to the right masticator muscle and showed peripheral thick-walled enhancement postcontrast [Figure 1a]. Cytology from the mass revealed poorly differentiated adenocarcinoma, consistent with metastasis from GBCA. He was continued on systemic chemotherapy and was offered palliative radiotherapy to the buccal lesion, to which he responded well. After 6 cycles of chemotherapy, response evaluation was done, which showed stable disease. He was continued on the same regimen till cycle 11, after which he developed grade II peripheral motor neuropathy. Hence, oxaliplatin was stopped and he was maintained on gemcitabine, with response evaluation every 3

monthly. In December 2018, after 21 cycles of the first-line chemotherapy, he complained of increasing pain in the abdomen. A restaging CT scan showed progressive disease with an increase in the liver lesions. After a progression-free interval of 11 months, his chemotherapy was changed capecitabine with irinotecan as the second line, considering his good performance status. Response evaluation after six cycles has revealed stable disease. However, in April 2019, he complained of dull-aching pain in the right thigh anterolateral aspect. Examination revealed a hard tender mass, fixed to the underlying bone. MRI of the thigh was done, which showed a vertically elongated oval altered signal intensity lesion in the intermuscular plane between the right vastus intermedius and right vastus lateralis in the proximal one-third of the right thigh as described –likely a metastatic deposit [Figure 1b]. Guided aspiration biopsy was done which showed deposits of metastatic adenocarcinoma, consistent with GBCA. He is still quite well preserved after 15 months of systemic chemotherapy and has been planned for the third-line chemotherapy with docetaxel.

Metastatic GBCA has very poor outcomes. Conventionally, the treatment of advanced GBCA was single-agent gemcitabine. After the report of the ABC 02 trial, doublet-agent gemcitabine with cisplatin (GEMCIS) became the standard with significant improvement in progression-free survival (PFS). The median PFS was 8.0 months in the cisplatin–gemcitabine group and 5.0 months in the gemcitabine-only group ( $P < 0.001$ ).<sup>[6]</sup> A randomized trial by Sharma *et al.* from India showed that six cycles of mGEMOX is equivalent to eight cycles of GEMCIS and one of these may be chosen for initial treatment.<sup>[7]</sup> Another matched-pair analysis of mGEMOX and GEMCIS also showed that both have equal efficacy.<sup>[8]</sup> Our patient received standard chemotherapy with mGEMOX. He had a reasonable PFS of 15 months, even though the median PFS of GBCA is in the range of 4–6 months.<sup>[6,7]</sup>

(Continue on page 254...)

(Letter to the editor continue from page 246...)

Our patient also has intramuscular metastasis to begin with, which is extremely rare. The usual sites are liver, lymph nodes, and peritoneum and, in very rare cases, lung. Even skeletal disease is also rare.<sup>[4]</sup> We could find only a single case report other than ours that has intramuscular metastasis.<sup>[5]</sup> In contrast to the previous report, where a single metastasis was found in the PET scan, our case shows that the disease can also have metachronous progression with development of musculoskeletal metastasis during treatment at a site quite distant from the previous metastasis.

Molecular analysis revealed that our patient had TP53 mutation positive. The existing literature has reported mutations of the TP53 gene in between approximately 27%–70% of GBCAs. The most common exons involved were exon 5 and 8. Our patient had exon 8. TP53 mutation is associated with high-grade pathology and more aggressive tumors. This may have explained the unusual sites of metastasis in our patient.

Musculoskeletal metastasis in GBCA is extremely rare. A high degree of clinical suspicion is of paramount importance. TP53 mutation may be associated with aggressive behavior. Some of these patients may show exceptional good responses, like the present case.

#### Declaration of patient consent

The authors certify that they have obtained all appropriate

patient consent forms. In the form the patient(s) has/have given his/her/their consent for his/her/their images and other clinical information to be reported in the journal. The patients understand that their names and initials will not be published and due efforts will be made to conceal their identity, but anonymity cannot be guaranteed.

#### Financial support and sponsorship

Nil.

#### Conflicts of interest

There are no conflicts of interest.

**Joydeep Ghosh, Sandip Ganguly, Deepak Dabkara, Bivas Biswas, Arghya Chatterjee<sup>1</sup>, Sumit Mukhopadhyay<sup>1</sup>, Aditi Chandra<sup>1</sup>, Saugata Sen<sup>1</sup>, Debdeep Dey<sup>2</sup>**

Departments of Medical Oncology, <sup>1</sup>Radiology and <sup>2</sup>Pathology, Tata Medical Center, Kolkata, West Bengal, India

Correspondence to: Dr. Joydeep Ghosh,  
E-mail: joydeep.ghosh@tmckolkata.com

#### References

1. Zhu AX, Hong TS, Hezel AF, Kooby DA. Current management of gallbladder carcinoma. *Oncologist* 2010;15:168-81.
2. Kokudo N, Makuuchi M, Natori T, Sakamoto Y, Yamamoto J, Seki M, *et al.* Strategies for surgical treatment of gallbladder carcinoma based on information available before resection. *Arch Surg* 2003;138:741-50.
3. Ohtani T, Shirai Y, Tsukada K, Muto T, Hatakeyama K. Spread of gallbladder carcinoma: CT evaluation with pathologic correlation. *Abdom Imaging* 1996;21:195-201.

(Continue on page 257...)

*(Letter to the editor continue from page 254...)*

4. Singh S, Bhojwani R, Singh S, Bhatnagar A, Saran RK, Agarwal AK, *et al.* Skeletal metastasis in gall bladder cancer. *HPB (Oxford)* 2007;9:71-2.
5. Gilardi L, Paganelli G. Muscle metastases from gallbladder cancer. *Ecancermedicalscience* 2011;5:236.
6. Valle J, Wasan H, Palmer DH, Cunningham D, Anthony A, Maraveyas A, *et al.* Cisplatin plus gemcitabine versus gemcitabine for biliary tract cancer. *N Engl J Med* 2010;362:1273-81.
7. Sharma A, Shukla NK, Chaudhary SP, Sahoo R, Mohanti B, Deo SV, *et al.* Final results of a phase III randomized controlled trial comparing modified gemcitabine+oxaliplatin (mGEMOX) to gemcitabine+cisplatin in management of unresectable gall bladder cancer (GBC). *J Clin Oncol* 2016;34 Suppl 15:4077.
8. Ramaswamy A, Ostwal V, Pinninti R, Kannan S, Bhargava P, Nashikkar C, *et al.* Gemcitabine-cisplatin versus gemcitabine-oxaliplatin doublet

chemotherapy in advanced gallbladder cancers: A match pair analysis. *J Hepatobiliary Pancreat Sci* 2017;24:262-7.

---

This is an open access journal, and articles are distributed under the terms of the Creative Commons Attribution-NonCommercial-ShareAlike 4.0 License, which allows others to remix, tweak, and build upon the work non-commercially, as long as appropriate credit is given and the new creations are licensed under the identical terms.

**How to cite this article:** Ghosh J, Ganguly S, Dabkara D, Biswas B, Chatterjee A, Mukhopadhyay S, *et al.* Metachronous muscle metastasis in a case of metastatic gallbladder cancer with TP35 gene mutation: A rare case report. *South Asian J Cancer* 2019;8:240-57.

© 2019 The South Asian Journal of Cancer | Published by Wolters Kluwer - Medknow