

Letter to the Editor

Use of lorlatinib subsequent to crizotinib in anaplastic lymphoma kinase-positive non-small cell lung cancer: Indian experience

DOI: 10.4103/sajc.sajc_169_19

Dear Editor,

Lung cancer treatment is a rapidly evolving and an excellent example of precision medicine. The outcome of anaplastic lymphoma kinase (ALK)-positive non-small cell lung cancer (NSCLC) has improved significantly with recent report showing the survival of 56% at 4 years.^[1] This has been possible due to the availability of effective sequential treatment. One of the important drugs has been lorlatinib. This has found to be effective in second-line setting after crizotinib.^[2] There has been no data from India. We retrospectively analyzed the data of patients receiving lorlatinib in our hospital. Patients diagnosed with ALK-positive advanced NSCLC who have received lorlatinib between January 2018 and February 2019 patients who have progressed on crizotinib were included in the study. Lorlatinib (Pfizer Oncology, Groton, CT, USA) was administered orally in a tablet form at a starting dose of 100 mg once daily continuously in 21-day cycles.

The details of these patients were obtained from the prospective lung cancer audit database that is maintained in the department of medical oncology. Demography (age, gender, comorbidity, and smoking status), disease status, and therapy details were recorded. ALK amplified status was ascertained either by immunohistochemistry (monoclonal antibody D5F3 [Ventana Medical Systems, Tucson, AZ, USA]) or fluorescent *in situ* hybridization analysis (Abbott Molecular platform). Response assessment was performed every 2–4 months as per the

Table 1: Baseline characteristics of patients treated with lorlatinib

Demographic (n=10)	Patients (n=10)
Median age, years (range)	52 (23-67)
Gender, n (%)	
Female	5 (50)
Male	5 (50)
History of smoking/tobacco use, n (%)	
Yes	2 (20)
No	8 (80)
Histopathology, n (%)	
Adenocarcinoma	6 (60)
Adenosquamous carcinoma	2 (20)
Adenocarcinoma with neuroendocrine	2 (20)
Comorbidities, n (%)	
Diabetes mellitus	1 (10)
Hypertension	1 (10)
Chronic lung disease	1 (10)
Multiple	1 (10)
None	6 (60)
ALK positivity, n (%)	
FISH alone	1 (10)
IHC alone	1 (10)
Both	8 (80)
Line of lorlatinib use, n (%)	
3	4 (40)
4	4 (40)
5	1 (10)
6	1 (10)
Best responses (total evaluable - 9), n (%)	
Complete response	2 (20)
Partial response	5 (50)
Stable disease	2 (20)

ALK=Anaplastic lymphoma kinase, FISH=Fluorescent *in situ* hybridization, IHC=Immunohistochemistry

(Continue on page 217...)

(Letter to the editor continue from page 211...)

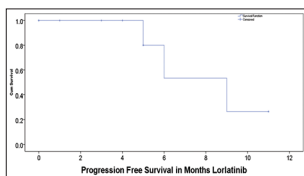


Figure 1: Median progression-free survival in patients on lorlatinib of 9.0 months (range: 5.6–12.3 months)

Table 2: Adverse effects of lorlatinib

Adverse event (all grade)	n (%)
Transaminitis	5 (50)
Hypercholesterolemia	7 (70)
Hypertriglyceridemia	7 (70)
Anemia	4 (40)
Nausea	5 (50)
Hypophosphatemia	1 (10)
Edema	2 (20)
Increased lipase/amylase	1 (10)

Table 3: Patient-wise line therapy received with median progression-free survival

Patient	Age	Sex	First line (PFS*)	Second line (PFS*)	Third line (PFS*)	Fourth line (PFS*)	Fifth line	Response
1	51	Female	Crizotinib (21)	Ceritinib (2)	Pem-Carbo [#] (7)	Gemcitabine (1)	Lorlatinib	Not evaluated
2	67	Male	Crizotinib (16)	Ceritinib (4)	Lorlatinib (11)	Ongoing		Complete
3	57	Female	Pem-Carbo [#] (3)	Crizotinib (15)	Ceritinib (3)	Pem-Carbo [#] + crizotinib (2)	Lorlatinib	Partial
4	64	Female	Pem-Carbo [#] (4)	Crizotinib (13)	Ceritinib (25)	Lorlatinib (5)	Ongoing	Complete
5	64	Male	Crizotinib (8)	Ceritinib (16)	Lorlatinib (3)	Ongoing		Stable
6	28	Male	Crizotinib (20)	Ceritinib (3)	Lorlatinib (9)	Ongoing		Partial
7	44	Male	Pem-Carbo [#] (18)	Crizotinib (20)	Ceritinib (2)	Lorlatinib	Ongoing	Partial
8	54	Male	Crizotinib (13)	Ceritinib (3)	Lorlatinib (ongoing)			Partial
9	39	Female	Pem-Carbo [#] (7)	Docetaxel (2)	Ceritinib (3)	Lorlatinib	Ongoing	Partial
10	23	Female	Crizotinib (9)	Pem-Carbo [#] + crizotinib (2)	Ceritinib (4)	Lorlatinib (6)	alectinib	Stable

*Months, [#]Pemetrexed and carboplatin combination chemotherapy. PFS=Progression-free survival

(Continue on page 225...)

institutional practice and evaluated by RECIST 1.1 criteria. Toxicity during this period was evaluated in accordance with the Common Terminology Criteria for Adverse Events version 4.02 Lorlatinib (Pfizer Oncology, Groton, CT, USA). Date of disease progression, date of change in treatment, and date of death were recorded. SPSS version 21 was used for analysis, and response rate, progression-free survival (PFS), and overall survival were calculated.

Tables 1 and 2 tabulate baseline characteristics and side effects of lorlatinib. The estimated median PFS in our study was 9.0 months (range: 5.6 months–12.3 months) [Figure 1]. Out of 9 evaluable patients, 2 (20%) and 5 (50%) has complete and partial responses, respectively [Table 1]. Our results are comparable to that reported in the literature.^[2] However, median duration of response in our cohort was lesser (9 months) in comparison to that reported in literature (12.5 months). Reason for such discrepant data

(Letter to the editor continue from page 217...)

can be explained in view of lorlatinib used in those with extensive disease progressed on multiple lines of therapy and ongoing responses [Table 3]. We report clinical outcomes on patients with crizotinib-resistant disease treated with lorlatinib and find it an important new treatment option for those patients whose disease has progressed after treatment with crizotinib or second-generation ALK tyrosine kinase inhibitors.

Financial support and sponsorship

Nil.

Conflicts of interest

There are no conflicts of interest.

**Vikas T. Talreja, Vanita Noronha, Amit Joshi,
Vijay Patil, Abhishek Mahajan,
Kumar Prabhash**

Department of Radiodiagnosis, Tata Memorial Hospital,
Mumbai, Maharashtra, India

Correspondence to: Dr. Vanita Noronha,
E-mail: vanita.noronha@gmail.com

References

1. Solomon BJ, Kim DW, Wu YL, Nakagawa K, Mekhail T, Felip E, *et al.* Final overall survival analysis from a study comparing first-line crizotinib versus chemotherapy in ALK-mutation-positive non-small-cell lung cancer. *J Clin Oncol* 2018;36:2251-8.
2. Solomon BJ, Besse B, Bauer TM, Felip E, Soo RA, Camidge DR, *et al.* Lorlatinib in patients with ALK-positive non-small-cell lung cancer: Results from a global phase 2 study. *Lancet Oncol* 2018;19:1654-67. Erratum in: *Lancet Oncol* 2019;20:e10.

This is an open access journal, and articles are distributed under the terms of the Creative Commons Attribution-NonCommercial-ShareAlike 4.0 License, which allows others to remix, tweak, and build upon the work non-commercially, as long as appropriate credit is given and the new creations are licensed under the identical terms.

How to cite this article: Talreja VT, Noronha V, Joshi A, Patil V, Mahajan A, Prabhash K. Use of lorlatinib subsequent to crizotinib in anaplastic lymphoma kinase-positive non-small cell lung cancer: Indian experience. *South Asian J Cancer* 2019;8:211-25.

© 2019 The South Asian Journal of Cancer | Published by Wolters Kluwer - Medknow