

---

## Letter to the Editor

### Sequential treatment with alectinib in crizotinib-resistant non-small-cell lung cancer

DOI: 10.4103/sajc.sajc\_199\_18

Dear Editor,

Alectinib is a highly selective, potent inhibitor of anaplastic lymphoma kinase (ALK). Phase 2 data suggest that alectinib elicits response in 46% with crizotinib-resistant disease,<sup>[1]</sup> making it a better alternative to chemotherapy. We describe

a case of crizotinib-resistant ALK + non-small-cell lung cancer (NSCLC) and our experience with alectinib as third-line tyrosine kinase inhibitor (TKI) therapy.

A 47 year-old female was evaluated for cough in September 2014. Supraclavicular node biopsy confirmed lung cancer of adenosquamous histology and ALK was amplified on fluorescence *in situ* hybridization. Positron emission tomography-computed tomography (CT) and magnetic resonance imaging brain showed right-lobe lung lesion, nodal metastasis, and brain metastasis. She was started on crizotinib in October 2014. She had clinical

(Continue on page 199...)

(Letter to the editor continue from page 194...)

and radiological response sustained until December 2015. Serial CT scan done thereafter showed gradual radiological progression at single disease site. Crizotinib was continued as she remained asymptomatic. In July 2016, ceritinib was started in view of a significant increase in radiological burden of disease.. There was clinical and radiological progression of disease within 2 months of therapy. She began chemotherapy with pemetrexed-carboplatin.

In June 2017, she had new-onset pleural effusion. Alectinib 300 mg twice daily was started as third-line TKI. There was clinical benefit with no reported toxicity on subsequent follow-up. By RECIST criteria, she had partial response at 2 months which was sustained until December 2017. She presented after 6 months of therapy with alectinib with worsening cough and breathlessness. CECET scan confirmed radiological progression [Figures 1-3]. Interestingly, she was never symptomatic for CNS disease despite failure of crizotinib and alectinib. She is presently planned for lorlatinib.

This case highlights the utility of second-generation TKI in ALK-positive NSCLC, especially in crizotinib refractory NSCLC. She tolerated crizotinib with sustained clinical benefit of 14 months. Ceritinib, her subsequent line of therapy, failed to control disease with progression within 2 months of initiation. With this background, alectinib has shown remarkable active in controlling an innately resistant disease for more than 6 months with no reported toxicity. Acquired mutations in ALK gene and P-glycoprotein overexpression have been reported mechanisms of crizotinib and certinib resistance which are overcome by alectinib. As our patient was unwilling for repeat biopsy, we were unable to identify resistant pathways which may help us choose from third-generation TKI.<sup>[2]</sup> Two single-arm phase 2 studies (Shaw *et al.* and Ou *et al.*)<sup>[1,3]</sup> evaluating alectinib in crizotinib-resistant disease showed PFS of 8.1 and 8.9 months and duration of response of 13.5 and 11.2 months, respectively. However, our patient had a PFS of only 6 months with alectinib.

In conclusion, sequential ALK suppression despite progression on TKI is the key to managing patients with ALK + NSCLC. Despite a shorter PFS than reported in literature, our patient had response to alectinib after two prior lines of ALK inhibitors. Future research should be directed at identifying mechanisms of resistance to ALK inhibitors which can help us choose the most appropriate TKI for our patients.

#### Declaration of patient consent

The authors certify that they have obtained all appropriate patient consent forms. In the form the patient(s) has/have given his/her/

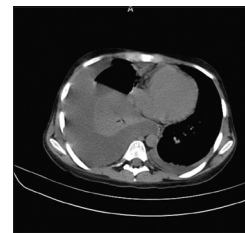


Figure 1: Contrast-enhanced computed tomography thorax: June 2017: before starting alectinib

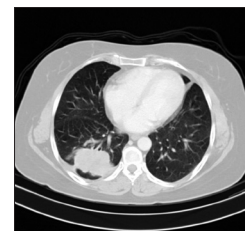

Figure 2: Contrast-enhanced computed tomography thorax: August 2017 – after 2 months of treatment with alectinib: complete resolution of pleural effusion

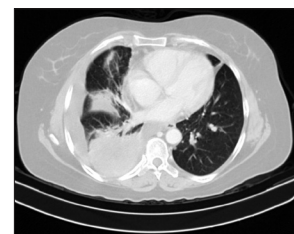

Figure 3: Contrast-enhanced computed tomography thorax: December 2017 – after 6 months of therapy with alectinib: multiple new lesions and new-onset pleural effusion

their consent for his/her/their images and other clinical information to be reported in the journal. The patients understand that their names and initials will not be published and due efforts will be made to conceal their identity, but anonymity cannot be guaranteed.

#### Financial support and sponsorship

Nil.

#### Conflicts of interest

There are no conflicts of interest.

**Swaratika Majumdar, Vanita Noronha, Amit Joshi, Vijay Patil, Rajiv Kumar<sup>1</sup>, Vaibhavi Trivedi<sup>1</sup>, Kumar Prabhash**

Departments of Medical Oncology and <sup>1</sup>Pathology, Tata Memorial Hospital, Mumbai, Maharashtra, India

Correspondence to: Dr. Kumar Prabhash,

E-mail: kprabhash1@gmail.com

(Continue on page 202...)

(Letter to the editor continue from page 199...)

## References

1. Shaw AT, Gandhi L, Gadgeel S, Riely GJ, Cetnar J, West H, *et al.* Alectinib in ALK-positive, crizotinib-resistant, non-small-cell lung cancer: A single-group, multicentre, phase 2 trial. *Lancet Oncol* 2016;17:234-42.
2. Mezquita L, Besse B. Sequencing ALK inhibitors: Alectinib in crizotinib-resistant patients, a phase 2 trial by Shaw *et al.* *J Thorac Dis* 2016;8:2997-3002.
3. Ou SH, Ahn JS, De Petris L, Govindan R, Yang JC, Hughes B, *et al.* Alectinib in crizotinib-refractory ALK-rearranged non-small-cell lung cancer: A phase II global study. *J Clin Oncol* 2016;34:661-8.

This is an open access journal, and articles are distributed under the terms of the Creative Commons Attribution-NonCommercial-ShareAlike 4.0 License, which allows others to remix, tweak, and build upon the work non-commercially, as long as appropriate credit is given and the new creations are licensed under the identical terms.

**How to cite this article:** Majumdar S, Noronha V, Joshi A, Patil V, Kumar R, Trivedi V, *et al.* Sequential treatment with alectinib in crizotinib-resistant non-small-cell lung cancer. *South Asian J Cancer* 2018;7:194-202.

© 2018 The South Asian Journal of Cancer | Published by Wolters Kluwer - Medknow

**4<sup>th</sup> AMMO Conference**  
**11-12 August 2018, Nashik**  
**Dr Shailesh Bondarde - shaileshbondarde@yahoo.com**  
**www.medintelservices.com**  
**Conference Organizer : Kashish Parikh**  
**+91-98190-25850 and kashishparikh@gmail.com**