

Transarterial radioembolization with Iodine-131-Lipiodol for hepatic metastases from gastrointestinal malignancies – Experience in tertiary care oncology center in India

Vidya Bhargavi, Indusekhar Subbanna, K. G. Kallur¹, Aakash Patel², Shivakumar Swamy, Shekar Patil³

Abstract

Context: Unresectable colorectal hepatic metastases can be treated with radioembolization. **Aims:** The aim of this study is to analyze the response and survival benefits of transarterial radioembolization (TARE) with Iodine-131 (¹³¹I) Lipiodol for hepatic metastases from gastrointestinal malignancies. **Settings and Design:** Retrospective study of 20 patients with pathologically proven hepatic metastases from primary gastrointestinal malignancies referred for palliative therapy with TARE. **Subjects and Methods:** At baseline, standard laboratory and imaging data were recorded. All patients fulfilling the inclusion/exclusion criteria underwent TARE with ¹³¹I Lipiodol. Post procedure, the patients were reviewed after 1 month with follow-up positron emission tomography-computed tomography and tumor marker levels to evaluate treatment response with continued follow-up till December 2016 and overall survival calculated. **Statistical Analysis Used:** Data were analyzed using a statistical analysis package (Social sciences, version 15.0 for Windows; SSPS Inc.). Survival data were plotted using Kaplan–Meier survival curves. **Results:** At the end of follow-up period, 15 of 20 patients were alive. The mean and median survival was 38.88 ± 5.0 months (95% confidence interval [CI], 29.03–48.74 months, *P* = 0.17) and 49.3 ± 12.4 months (95% CI, 25.0–73.7 months, *P* = 0.17), respectively. 66 months survival was 75%. Response evaluation in 10 patients showed partial response in 3 (30%), stable disease in 2 (20%) and progressive disease in 5 (50%) patients. All patients with partial response showed a reduction in serum tumor marker levels. **Conclusions:** TARE with ¹³¹I-Lipiodol is highly effective with a significant survival benefit in refractory cases of hepatic metastases from gastrointestinal malignancies.

Key words: Iodine-131-Lipiodol, hepatic metastases, transarterial radioembolization

Introduction

The liver is the second most common site for metastatic spread from primary gastrointestinal malignancies, after the lymphnodes. Hepatic metastases are 18–40 times more common than primary liver tumors.^[1] Although surgical resection is the treatment of choice in metastatic hepatic disease, surgical resection is often not feasible with possibility in <20% of patients.^[2]

Transarterial radioembolization (TARE) with Yttrium-90 (⁹⁰Y) microspheres is approved by the Food and Drug Administration for patients with primary and metastatic liver cancer. Although ⁹⁰Y radioembolization is currently the preferred method for treating liver metastases compared to Iodine-131 (¹³¹I)-Lipiodol, it has few disadvantages.^[3] Most of the published data on TARE in hepatic metastases is based on ⁹⁰Y microspheres with limited studies using ¹³¹I-Lipiodol. The available studies on TARE with ¹³¹I-Lipiodol are on small sample size, stressing the need for a more elaborate study on its use in hepatic metastases. We present the response and survival benefits of TARE with ¹³¹I-Lipiodol in 20 patients with hepatic metastases from gastrointestinal malignancies.

Subjects and Methods

Approval was taken from the Institutional Ethics Committee and written informed consent was obtained from all patients. This is a retrospective study in patients with hepatic metastases from gastrointestinal malignancies who underwent TARE between May 2011 and December 2016. Patients with pathologically proven hepatic metastases from primary gastrointestinal malignancies who were not candidates for surgery were included in the study. For all patients, baseline laboratory workup including tumor marker assays (carcinoembryonic

antigen [CEA] and carbohydrate antigen 19–9) and imaging (computed tomography (CT)/Positron emission tomography-computed tomography [PET-CT/MRI]) were performed. The prior treatment history, Eastern Cooperative Oncology Group performance scores and pain visual analog scores of the patients were recorded. The presence of nodal spread was noted.

Patient selection

A total of 20 patients (15 males, 5 females, mean age of 55 years [age range: 34–81 years]) with pathologically proven hepatic metastases from primary gastrointestinal malignancies out of 70 patients with metastases from various primary malignancies were considered for intraarterial ¹³¹I-Lipiodol therapy. Patients who were inoperable for hepatic metastases and had undergone multiple cycles of the 1st- and 2nd-line chemotherapy and other treatments with poor response/progressive disease were considered for intraarterial ¹³¹I-Lipiodol therapy. Patients with life expectancy <1 month, hepatic encephalopathy, demonstrable arterio-venous or arterio-portal shunting on CT or digital subtraction angiography (DSA), uncorrectable coagulopathy, and renal failure were excluded from the study.

Technique

Isotopic exchange is used to label iodine rich Lipiodol with ¹³¹I in our cyclotron to prepare ¹³¹I-lipiodol. Intraarterial ¹³¹I-Lipiodol therapy was performed under local anesthesia through transfemoral approach. 5F introducer sheath (Terumo, Europe N. V.) was used to access the femoral artery. Celiac artery and superior mesenteric artery were catheterized using 4F Yashiro catheter (Terumo, Europe N. V.) or 4F Renal

This is an open access journal, and articles are distributed under the terms of the Creative Commons Attribution-NonCommercial-ShareAlike 4.0 License, which allows others to remix, tweak, and build upon the work non-commercially, as long as appropriate credit is given and the new creations are licensed under the identical terms.

For reprints contact: reprints@medknow.com

How to cite this article: Bhargavi V, Subbanna I, Kallur KG, Patel A, Swamy S, Patil S. Transarterial radioembolization with Iodine-131-Lipiodol for hepatic metastases from gastrointestinal malignancies – Experience in tertiary care oncology center in India. South Asian J Cancer 2019;8:31-4.

Access this article online

Quick Response Code:



Website: www.sajc.org

DOI: 10.4103/sajc.sajc_205_17

Departments of Interventional Radiology, ¹Nuclear Medicine and ³Medical Oncology, Health Care Global Hospitals, Bengaluru, Karnataka, ²Department of Radiology, Shalby Hospitals, Ahmedabad, Gujarat, India
Correspondence to: Dr. Vidya Bhargavi,
 E-mail: bhargavi_vidya@yahoo.in

curve catheter (Terumo, Europe N. V.) and digital subtraction angiogram (DSA) obtained to delineate vascular anatomy and identify vessels supplying the tumor including vascular anatomical variants. The procedure was abandoned if there was arterio-venous or arterio-portal shunting. The vessels supplying the tumor bed were super selectively catheterized using 4F Yashiro catheter (Terumo, Europe N. V.) or 4F Renal curve catheter (Terumo, Europe N. V.) or co-axial 2.7F microcatheter (Progreat, Terumo, Europe N. V.) depending on the vascular anatomy. Post selective catheterization, 20 mg Doxorubicin (Fresenius Kabi, India) was injected as a radio sensitizer which was followed by slow injection of 7–10 cc ¹³¹I-Lipiodol (approximately 50 mCi) under fluoroscopic control with adequate radiation protection. In cases with extensive bilateral disease, ¹³¹I-Lipiodol was slowly injected with catheter tip in the right and left hepatic arteries, respectively. The injection was stopped when the lesion showed adequate lipiodol fixation or if there was reflux into the normal branches. The entry site was closed using a closure device (Star closure device, Abbott vascular, IL, USA) and all the used materials were disposed as per radiation safety rules. Post procedure, the patient was isolated for 5–7 days and discharged after confirming the emitted gamma radiation levels to be <5 mR/h. A scintigraphy scan was obtained 4 days after therapy to confirm tumor uptake of ¹³¹I-Lipiodol.

Patients did not receive any additional therapy after TARE for 6–8 weeks. All patients underwent clinical, biochemical (tumor marker assays), and radiological examination to evaluate tumor response after 4 weeks. Tumor response was graded according to the European Association for the Study of Liver response criteria.^[4]

Survival of patients was calculated up to either death or conclusion of the study in December 2016. Survival in patients who did not come for follow-up was calculated on the basis of information provided by patient's kin through telephonic calls.

Statistical analysis

Data were analyzed using a statistical analysis package (SPSS 20, IBM, Armonk, New York, United States of America). Survival data were plotted using Kaplan–Meier survival curves.

Results

A total of 20 patients (15 males (75%), 5 females (25%]) with a mean age of 55 years (Age range: 34–81 years) underwent intraarterial ¹³¹I-Lipiodol therapy. All patients had hepatic metastases from primary gastrointestinal malignancies and had undergone prior treatment (two patients-metastasectomy, 3-only chemotherapy, 11-resection and chemotherapy, 2-chemotherapy and cyberknife, and 2-chemotherapy and neoadjuvant chemotherapy) with mean treatment duration of 11 months (range: 1–36 months). Three patients (15%) had solitary lesion whereas 17 patients (85%) had multiple lesions at the time of selection for intraarterial ¹³¹I-Lipiodol therapy. Mean tumor size was 2.7 cm (range: 1.5–11.5 cm). In patients with multiple lesions, the size of the largest lesion was taken into consideration. 11 patients (55%) had tumor of size <5 cm, 7 patients (35%) had tumor of size 5–10 cm and two patients (10%) had tumor of size >10 cm. 11 patients (55%) had lymph nodal/extrahepatic spread on imaging while 9 patients (45%) had no nodal/extrahepatic spread.

Overall, the procedure was well tolerated by all our patients with mild procedural/post procedural toxicities (10%) ranging

from pain, fever, nausea, vomiting, and loss of appetite which lasted for a duration of 2 days.

Survival data

At the end of the follow-up period (between May 2011 and December 2016), 5 of 20 patients died and remaining 15 patients under follow-up. The mean duration of survival from the date of intraarterial ¹³¹I-Lipiodol therapy was found to be 38.88 ± 5.0 months (95% confidence limit, 29.03–48.74 months, *P* = 0.17). The median duration of survival was found to be 49.3 ± 12.4 months (95% confidence limit, 25.0–73.7 months, *P* = 0.17). 66 months survival was 75%.

Response evaluation

Response evaluation with imaging could not be done in 10 patients. Survival in these 10 patients was calculated on the basis of information provided by patient's kin through telephonic calls. In rest of the 10 patients who underwent follow-up imaging, 3 patients (30%) showed partial response [Figure 1 and 2], 2 patients (20%) showed stable disease and 5 patients (50%) showed progressive diseases. All patients showed reduction in serum tumor marker levels (CEA and CA 19-9).

On follow-up, 1 patient received additional treatment with the 2nd-line chemotherapy.

Discussion

The liver has a rich and dual blood supply through the hepatic artery and the portal vein favoring high incidence of metastases. The endothelium of the liver sinusoids have fenestrations that trap the tumor emboli within the arriving blood stream in the space of Disse.^[5] Primary sites most commonly metastasizing to the liver are from the gastrointestinal tract via the portal circulation. Other common primary sites include breast, lung, genitourinary, melanoma, and sarcoma.^[6] Essentially, all metastatic solid malignancies have a pattern of generalized dissemination, while isolated hepatic metastases are more common in colorectal and neuroendocrine tumors. The tumors are predominantly supplied by hepatic artery while the spread is through portal circulation.

Among patients with metastatic colorectal cancers, approximately 20% have hepatic metastases at the time of primary diagnosis and 50% develop hepatic metastases even after surgical resection and chemotherapy.^[7] The survival in patients with metastatic colorectal cancers is related to the extent of liver involvement. The median survival of untreated patients with a solitary metastases is approximately 17 months compared with <6 months in those with multiple bilobar disease.^[8] The unresectable colorectal hepatic metastases can be treated with radioembolization.

TARE is defined as the administration of micron-sized embolic particles loaded with a radioisotope by use of percutaneous transarterial techniques in order to deliver high focal doses of radiation to cancers. TARE with ⁹⁰Y microspheres is extensively used and approved by the Food and Drug Administration for patients with primary and metastatic liver cancer. Although ⁹⁰Y radioembolization is currently the preferred method for treating liver metastases compared to ¹³¹I-Lipiodol, it has few disadvantages. First, severe liver dysfunction is a contraindication because of its embolic nature. Second, techniques using ⁹⁰Y-labeled products tend to cost up to 10 times more than therapy with ¹³¹I-Lipiodol.^[3] Third, Iodine is an integral constituent

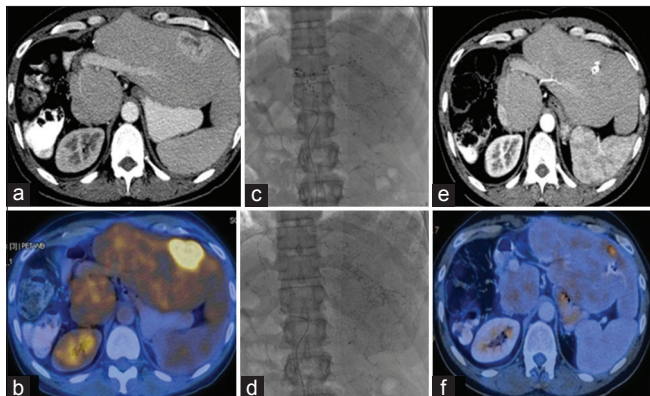


Figure 1: A 52 year old male patient with right hepatectomy status and hepatic metastases from gastrointestinal malignancy (colorectal malignancy). Contrast enhanced CT (a) showed a hypervascular lesion in left lobe of liver with significant activity on PET scan (b). Patient underwent TARE with ¹³¹I-Lipiodol (c, d). Follow up scan demonstrates lipiodol deposition after TARE with ¹³¹I-Lipiodol within the hyper vascular lesion and reduction in size and enhancement of lesions (e) with significantly reduced PET activity (f)

of lipiodol, hence ¹³¹I-lipiodol which is produced by isotopic exchange and the radioisotope remains a stable constituent of the lipiodol, limiting leaching and unintended systemic therapy; in contrast, early ⁹⁰Y devices had high rates of leaching of ⁹⁰Y from the compounds, resulting in significant bone marrow toxicity.

TARE with ¹³¹I-Lipiodol has been proposed as an alternative to Yttrium-90. ¹³¹I is a beta-emitting radionuclide with mean beta particle energy of 0.192MeV, additionally emits a principal gamma photon of 364 keV. The beta radiation of ¹³¹I is responsible for its therapeutic effects while gamma radiation makes the distribution of the radiopharmaceutical visible. Lipiodol is a mixture of iodized esters of poppy seed oil fatty acids. Isotopic exchange is used to label iodine-rich Lipiodol with ¹³¹I. Advantages of ¹³¹I-Lipiodol over ⁹⁰Y are cost effectiveness, selective cytotoxicity for the tumor cells, inability of tumor cells to expel Lipiodol further enhancing its cytotoxic effect and long half-life of 8 days.^[3]

Few published data on TARE in hepatic metastases is based on ⁹⁰Y microspheres with limited studies using ¹³¹I-Lipiodol. The studies have smaller sample size and studies vary with respect to criteria for assessing response and disease categories, hence limiting comparison.

In a series of 72 patients with unresectable hepatic colorectal metastases, Mulcahy *et al.* investigated the safety and efficacy of ⁹⁰Y radioembolization.^[9] The CT response rate was 40.3%; PET response rate was 77%, and the median response duration and time to hepatic progression was 15 and 15.4 months, respectively. Overall survival was 14.5 months from first treatment date.

In a recent multicenter phase II trial, Cosimelli *et al.* found that radioembolization with ⁹⁰Y produced meaningful responses and disease stabilization in patients with advanced, unresectable, and chemorefractory metastatic colorectal cancer.^[10] By response evaluation criteria, complete response, partial response, stable disease and progressive disease were noted in 22%, 24%, 44%, and 8% of patients, respectively. Median overall survival was 12.6 months.

Murthy *et al.* reported on 12 patients with advanced unresectable colorectal hepatic metastases treated with selective

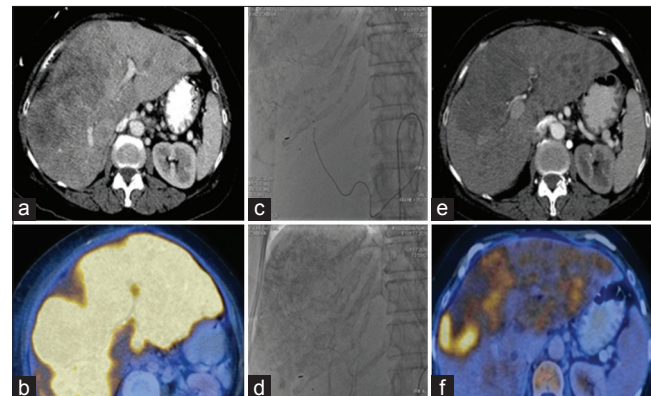


Figure 2: 60yearold female patient with postoperative status for carcinoma rectosigmoid junction and hepatic metastases. Contrastenhanced computed tomography (a) Multiple hypervascular lesions in both lobes of liver with significant activity on positron emission tomography scan (b) Patient underwent transarterial radioembolization with Iodine¹³¹lipiodol (c and d). Followup scan demonstrates Lipiodol deposition after transarterial radioembolization with Iodine¹³¹Lipiodol within the hyper vascular lesions and reduction in size and enhancement of lesions (e) with significantly reduced positron emission tomography activity (f)

internal radiation-Spheres.^[11] Radiological response was stable in five of nine patients (56%) and CEA levels decreased in four of seven patients (57%). Median survival times from diagnosis and treatment were 24.6 and 4.5 months, respectively.

In our study of 20 patients with hepatic metastases from primary gastrointestinal malignancies, 5 patients had died with 15 patients alive. 66 months survival was 75%. The mean duration of survival was found to be 38.88 ± 5.0 months (95% confidence limit, 29.03–48.74 months, $P = 0.17$) in patients with gastrointestinal malignancies. The median duration of survival was found to be 49.3 ± 12.4 months (95% confidence limit, 25.0–73.7 months, $P = 0.17$).

In 10 patients with tumor response graded according to EASL response criteria, 13 patients (30%) showed partial response, 2 patients (20%) showed stable disease and 5 patients (50%) showed progressive disease. All patients with partial response showed reduction in serum tumor marker levels.

Conclusions

All patients with hepatic metastases from primary gastrointestinal malignancies underwent multiple cycles of the 1st- and 2nd-line chemotherapy and other treatments with poor response/progressive disease. In this background, the treatment with ¹³¹I Lipiodol has shown improved response both clinically, biochemically and radiologically. TARE with ¹³¹I-Lipiodol is highly effective in patients with hepatic metastases, especially in those with poor response to other treatments and has shown significant survival benefit and better quality of life. TARE with ¹³¹I-Lipiodol has an added advantage of being cost effective compared to TARE with ⁹⁰Y embedded microspheres in developing countries like India.

Declaration of patient consent

The authors certify that they have obtained all appropriate patient consent forms. In the form the patient(s) has/have given his/her/their consent for his/her/their images and other clinical information to be reported in the journal. The patients understand that their names and initials will not be published and due efforts will be made to conceal their identity, but anonymity cannot be guaranteed.

Financial support and sponsorship

Nil.

Conflicts of interest

There are no conflicts of interest.

References

1. Namasivayam S, Martin DR, Saini S. Imaging of liver metastases: MRI. *Cancer Imaging* 2007;7:2-9.
2. Sasson AR, Sigurdson ER. Surgical treatment of liver metastases. *Semin Oncol* 2002;29:107-18.
3. Ahmadzadehfar H, Sabet A, Biersack HJ, Risse J. Therapy of hepatocellular carcinoma with iodine-131-lipiodol. In: Lau JW, editor. *Hepatocellular Carcinoma – Clinical Research*. InTech; 2012.
4. Bruix J, Sherman M, Llovet JM, Beaugrand M, Lencioni R, Burroughs AK, *et al.* Clinical management of hepatocellular carcinoma. Conclusions of the barcelona-2000 EASL conference. European association for the study of the liver. *J Hepatol* 2001;35:421-30.
5. Adam A. Interventional radiology in the treatment of hepatic metastases. *Cancer Treat Rev* 2002;28:93-9.
6. Doherty GM, Way LW. *Current Surgical Diagnosis & Treatment*. McGraw-Hill Medical; 2006.
7. Landis SH, Murray T, Bolden S, Wingo PA. Cancer statistics, 1998. *CA Cancer J Clin* 1998;48:6-29.
8. Oxley EM, Ellis H. Prognosis of carcinoma of the large bowel in the presence of liver metastases. *Br J Surg* 1969;56:149-52.
9. Mulcahy MF, Lewandowski RJ, Ibrahim SM, Sato KT, Ryu RK, Atassi B, *et al.* Radioembolization of colorectal hepatic metastases using yttrium-90 microspheres. *Cancer* 2009;115:1849-58.
10. Cosimelli M, Golfieri R, Cagol PP, Carpanese L, Sciuto R, Maini CL, *et al.* Multi-centre phase II clinical trial of yttrium-90 resin microspheres alone in unresectable, chemotherapy refractory colorectal liver metastases. *Br J Cancer* 2010;103:324-31.
11. Murthy R, Xiong H, Nunez R, Cohen AC, Barron B, Szklaruk J, *et al.* Yttrium 90 resin microspheres for the treatment of unresectable colorectal hepatic metastases after failure of multiple chemotherapy regimens: Preliminary results. *J Vasc Interv Radiol* 2005;16:937-45.