

Letter to the Editor

A rare case of pinealoblastoma in adult with complete response to treatment

DOI: 10.4103/sajc.sajc_262_18

Dear Editor,

Supratentorial primitive neuroectodermal tumors (SPNETs) usually arise from cerebrum or pineal gland and accounts for about 2.5% of pediatric brain tumors.^[1] SPNET arising from the pineal gland is known as pinealoblastomas, which are highly malignant embryonal tumors usually affects children and adolescents and are very rare in adults.^[2]

A 42-year-old male patient presented with a history of a headache and blurring of vision for 15 days. There was no history suggestive of any focal neurological deficits. Neuroimaging [Figure 1] showed a well-defined mass lesion of size 2 cm × 1.5 cm in the posterior aspect of the third ventricle along the hypothalamo-pineal axis possibly a pineal gland tumor.

He underwent craniotomy and maximal safe resection of the tumor. Histopathological analysis showed pinealoblastoma (the WHO Grade IV) with MIB index of 30%. Immunohistochemistry was done which showed synaptophysin and chromogranin positivity. The postoperative imaging showed residual mass lesion with involvement of medial thalamus. The patient received craniospinal irradiation with vincristine-based concurrent chemotherapy (five cycles). Imaging at re-evaluation showed near-complete resolution of the tumor [Figure 2]. The patient received six cycles of adjuvant chemotherapy with vincristine, procarbazine, and lomustine. The imaging at the completion of the treatment showed complete resolution of the lesion with no residual abnormalities.

Pinealoblastomas in an adult is a rare entity. In a retrospective review of 48 patients with the pineal gland tumors over 10 years, which included 35 children and 13 adults, pinealoblastoma was diagnosed only in six (12.5%) cases.^[3] In a review of treatment outcomes in pinealoblastoma from tertiary cancer hospital in India,

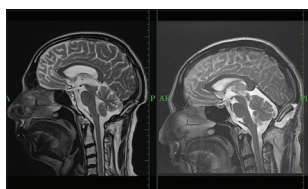


Figure 1: Right: Presurgery: A circumscribed lesion with well-defined margins is seen involving the pineal gland, which has mixed intermediate and high signal on sagittal T2-weighted images. Left: Postsurgery/postchemotherapy/radiotherapy: Evidence of craniotomy and postoperative defect is noted in occipital bone. No altered signal intensity lesion is appreciated

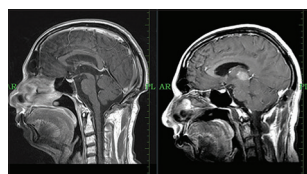


Figure 2: Right: Presurgery: A well circumscribed tumor arising from the pineal gland shows contrast enhancement on sagittal T1- weighted image. Left: Postsurgery/postchemotherapy/radiotherapy: Evidence of craniotomy and postoperative defect is noted in occipital bone. No altered signal intensity lesion is appreciated

there were 17 patients of pinealoblastoma with a median age of 14 years.^[4] After a median follow-up of 30 months following surgery and adjuvant chemoradiotherapy, disease recurrence and death were noted in 7 (41%) and 3 (17%) patients, respectively, with estimated median recurrence-free survival of 5.4 years. There were no standard guidelines to manage this malignancy in adults.

This case depicts a rare malignancy of the central nervous system which presented in an uncommon age group of the fifth decade. Although there are no standard guidelines for treatment of pinealoblastoma in an adult, surgical resection followed by craniospinal irradiation with boost to tumor bed along with chemotherapy gives a good response. Clinical trials with a larger number of patients are needed to look for the best treatment modality.

Declaration of patient consent

The authors certify that they have obtained all appropriate patient consent forms. In the form the patient(s) has/have given his/her/their consent for his/her/their images and other clinical information to be reported in the journal. The patients understand that their names and initials will not be published and due efforts will be made to conceal their identity, but anonymity cannot be guaranteed.

Financial support and sponsorship

Nil.

Conflicts of interest

There are no conflicts of interest.

Amrith Patel, Sumit Goyal, Udip Maheshwari, Manish Sharma, Ankush Jajodia¹, Venkata Pradeep Babu Koyyala

Departments of Medical Oncology and ¹Radiology, Rajiv Gandhi Cancer Institute and Research Centre, New Delhi, India

Correspondence to: Dr.Venkata Pradeep Babu Koyyala, E-mail: pradeepbabu.koyyala@gmail.com

References

- Gaffney CC, Sloane JP, Bradley NJ, Bloom HJ. Primitive neuroectodermal tumours of the cerebrum. Pathology and treatment. *J Neurooncol* 1985;3:23-33.
- Villà S, Miller RC, Krengli M, Abusaris H, Baumert BG, Servagi-Vernat S, *et al*. Primary pineal tumors: Outcome and prognostic factors – A study from the rare cancer network (RCN). *Clin Transl Oncol* 2012; 14:827-34.
- Cho BK, Wang KC, Nam DH, Kim DG, Jung HW, Kim HJ, *et al*. Pineal tumors: Experience with 48 cases over 10 years. *Childs Nerv Syst* 1998; 14:53-8.
- Biswas A, Mallick S, Purkait S, Gandhi A, Sarkar C, Singh M, *et al*. Treatment outcome and patterns of failure in patients of pinealoblastoma: Review of literature and clinical experience from a regional cancer centre in North India. *Childs Nerv Syst* 2015;31: 1291-304.

This is an open access journal, and articles are distributed under the terms of the Creative Commons Attribution-NonCommercial-ShareAlike 4.0 License, which allows others to remix, tweak, and build upon the work non-commercially, as long as appropriate credit is given and the new creations are licensed under the identical terms.

How to cite this article: Patel A, Goyal S, Maheshwari U, Sharma M, Jajodia A, Babu Koyyala VP. A rare case of pinealoblastoma in adult with complete response to treatment. *South Asian J Cancer* 2018;7:262.

© 2018 The South Asian Journal of Cancer | Published by Wolters Kluwer - Medknow