

Metastatic gastrointestinal stromal tumor: A regional cancer center experience of 44 cases

M. C. Suresh Babu, Tamojit Chaudhuri, K. Govind Babu, K. C. Lakshmaiah, D. Lokanatha, Linu Abraham Jacob, A. H. Rudresha, K. N. Lokesh, L. K. Rajeev

Abstract

Background: Gastrointestinal stromal tumors (GISTs) are the most common mesenchymal neoplasms of the gastrointestinal tract. Historically, a poor prognosis for metastatic disease has been reported with systemic chemotherapy. Significant advances have been made in the last decade, since the introduction of different tyrosine kinase inhibitors (TKIs). Unfortunately, even though the TKIs have been used for a long time, there are very few published data of the experience of TKI therapy in metastatic GIST from India. **Materials and Methods:** Patients diagnosed with metastatic GIST from January 2005 to October 2016 at our center, who received first-line therapy with imatinib 400 mg/day, were reviewed retrospectively. Patients' profile, response to treatment, toxicity of TKI therapy, time to progression, and survival were evaluated. **Results:** Of the 44 metastatic GIST patients, 23 (52.2%) were males. Median age at diagnosis was 48 years. The most common presenting symptom was an abdominal pain (52%), followed by weight loss (23%). Most frequently affected metastatic site was liver (57%), followed by peritoneum (16%), and lungs (4.5%). Metastases to both liver and peritoneum were found in 10 patients (22.5%). All patients were initially treated with imatinib at a dose of 400 mg/day. Disease stabilization was documented in 21 cases (48%), and 13 patients (29%) achieved a partial response. TKI therapy was well-tolerated in most cases. Median progression-free survival (PFS) was 26 months, and estimated median survival was 48 months. Patients with lung metastases have a significantly inferior median PFS and overall survival, in comparison to patients with other metastatic sites ($P < 0.05$). **Conclusions:** Imatinib therapy was well tolerated and induced a sustained clinical benefit in more than half of the patients with metastatic GIST. Lung metastases seemed to be a poor prognostic factor in this patient population.

Key words: c-KIT, gastrointestinal stromal tumors, tyrosine kinase inhibitors

Introduction

Gastrointestinal stromal tumors (GISTs) are the most common mesenchymal malignancy of the gastrointestinal tract.^[1] They represent 1% of malignant tumors of the digestive tract and derive from the interstitial cells of Cajal, which serve as a gut pacemaker by creating the basal electrical rhythm leading to peristalsis.^[2] GIST most commonly occur in the stomach (60%–70%), followed by the small intestine (20%–30%) and colorectum (5%–10%); they are also rarely found elsewhere in the abdominal cavity, such as in the mesentery, the omentum, or the retroperitoneum.^[3] More than 95% of GISTs express the KIT protein (CD 117), and recently discovered on GIST1 (DOG 1) has also been suggested as a useful diagnostic marker.^[4] These two immunohistochemical markers are considered to be the most specific and sensitive markers for GIST.^[4] As for the genetic aberrations, approximately, 80% of GISTs have a c-KIT mutation, 8%–10% have mutations in the gene encoding the platelet-derived growth factor receptor alpha (PDGFR- α), and the remaining are wild type for both c-KIT and PDGFR- α genes.^[5] The gain-of-function mutations of these genes are critical in the pathogenesis of GIST. The prognosis and genetic features are distinguishable according to the anatomical location; a gastric GIST has a better prognosis and a higher incidence of an exon 11 mutation of c-KIT.^[6] Historically, there were limited options for the medical management of GIST, with tumor recurrence frequently observed following complete surgical resection of the primary tumor and a grim prognosis for patients with the unresectable or metastatic disease. However, the introduction of the tyrosine kinase inhibitor (TKI) imatinib mesylate has had a major impact on treatment outcomes for these patients

with advanced/metastatic disease.^[7] The recent introduction of sunitinib and regorafenib in this patient population after the failure of first-line imatinib therapy has further broadened the treatment options.^[8,9]

In India, TKI therapy for different indications in GIST, have been used for a long time. Unfortunately, there are very few published data of the experience of TKI therapy in metastatic GIST from our country. Most of the reported data are retrospective single center experiences and case reports. The aim of this retrospective study was to review the clinical data of the patients with metastatic GIST treated at our institute and to evaluate the influence of potential prognostic factors (e.g., the location of the primary tumor and sites of metastases) on the overall and progression-free survival (PFS).

Materials and Methods

Patient selection, evaluation, and treatment

We performed a retrospective study by reviewing the medical records of 44 patients with metastatic GIST, treated in our department between January 2005 and October 2016. The research was exempted from the requirement for ethics committee approval, as per our Institutional policy because it was a retrospective study of patients' records. All the patients underwent a detailed history and physical examination including endoscopy. The localization and number of the metastatic lesions were investigated by contrast-enhanced computed tomography scans, and the diagnosis of GIST was confirmed by microscopic examination and immunohistochemistry of the biopsy specimens. The immunohistochemical profile was performed using a panel of CD117, CD34, DOG 1, vimentin, desmin, SMA and S100. All patients were treated

This is an open access article distributed under the terms of the Creative Commons Attribution-NonCommercial-ShareAlike 3.0 License, which allows others to remix, tweak, and build upon the work non-commercially, as long as the author is credited and the new creations are licensed under the identical terms.

For reprints contact: reprints@medknow.com

How to cite this article: Suresh Babu MC, Chaudhuri T, Babu KG, Lakshmaiah KC, Lokanatha D, Jacob LA, et al. Metastatic gastrointestinal stromal tumor: A regional cancer center experience of 44 cases. South Asian J Cancer 2017;6:118-21.

Access this article online

Quick Response Code:



Website: www.sajc.org

DOI: 10.4103/sajc.sajc_290_16

Department of Medical Oncology, Kidwai Memorial Institute of Oncology, Bengaluru, Karnataka, India

Correspondence to: Dr. Tamojit Chaudhuri, E-mail: tamojit.cnm@gmail.com

with first-line imatinib 400 mg once a day. On progression to standard-dose imatinib, some patients received either escalated doses of imatinib (600 mg or 800 mg once daily) or sunitinib or regorafenib. Responses to TKI treatment were reported according to the Response Evaluation Criteria in Solid Tumors (1.1). The adverse events were classified based on the Common Terminology Criteria for Adverse Events version 4.0.

Statistical analysis

The duration of PFS was defined by the time from the treatment initiation until the documented disease progression, and overall survival (OS) was calculated from the date of diagnosis until death. The strength of the association between PFS and OS with different prognostic variables (e.g., site of metastases and primary disease site) was investigated by Kaplan–Meier curve and log-rank test. PFS was taken as the primary endpoint for this retrospective analysis, and the secondary endpoints were OS, response to TKI treatment and toxicity profile. All statistical analyses were performed using SPSS version 17.0 for Windows (SPSS Inc., Chicago, IL, USA).

Results

Totally, 44 cases of metastatic GIST treated with TKIs were retrospectively reviewed. The baseline patient characteristics were depicted in Table 1. The main finding on physical examination was a palpable abdominal mass in 36% (n = 16) of cases. In immunohistochemistry, 95% (n = 42) patients expressed positivity for antigen CD117 and 59% (n = 26) cases were positive for CD34.

According to the assessment of response to first-line imatinib therapy, stable disease (SD) was documented in 21 cases (48%), followed by a partial response (PR) in 13 patients (29%). None of our patients achieved a complete response (CR). Median time to response in patients who achieved at least a PR was 4.5 months.

The median PFS was 26 months (95% confidence interval [CI]: 22.8–35.2) for the whole cohort. According to the site of

metastases, the median PFS were: 34 months for liver, 26 months for peritoneum, 13 months for lungs, and 23 months for the presence of both liver and peritoneal metastases (P = 0.032) [Figure 1]. Patients with gastric primary had a significantly better PFS in comparison to patients with nongastric primaries, 34 months versus 23 months, respectively (P = 0.012). During the follow-up, there were 20 deaths, showing an estimated median survival of 48 months (95% CI: 28.2–72.4), for the whole cohort. A significant difference in the median survival according to the metastatic sites was also observed. The median survival of patients with liver, peritoneum, lungs, and both liver with peritoneum metastases were 58, 44, 22, and 48 months respectively (P = 0.000) [Figure 2]. Similarly, like PFS, the median survival was also better in patients with gastric primary than that of the patients with nongastric primaries, 53 months versus 44 months, respectively, but that difference was not statistically significant (P = 0.052).

Out of the 25 patients with isolated liver metastases, 8 patients underwent curative intent resection, after a median duration of 7.5 months (range: 4–16 months) imatinib therapy. All of these 8 patients also received adjuvant imatinib. The estimated median survival for this subgroup (n = 8) was 71 months.

First-line imatinib therapy was well-tolerated in our series, and none of our patients developed any serious adverse events requiring treatment interruption. Most common side effects (Grade 1 or 2) were facial hyperpigmentation (n = 17), periorbital edema (n = 16), followed by muscle cramps (n = 7), and diarrhea (n = 4). One patient developed congestive cardiac failure on second-line sunitinib, which improved with conservative measures and therapy was changed to third-line regorafenib for this patient.

Discussions

The treatment of GISTs has represented a dramatic evolution in the concept of the management of advanced/metastatic disease, with a transition from the cytotoxic chemotherapy which offered modest response rates,^[10] to the initiation of the molecular targeted therapy, targeting specifically the molecular changes responsible for the pathogenesis of cancer (c-KIT, PDGFR-α). The discovery of STI571 (imatinib mesylate) has revolutionized the treatment of GIST. The encouraging results with the first case studies led to the implementation of Phase I and II trials, showing that imatinib mesylate had significant activity in patients with advanced GIST, achieving PR rate of 53.7%, SD in 27.9%, and toxicity Grade 3 and 4 (bleeding, abdominal pain, and electrolyte disturbances) in 21.1% of cases.^[7,11] Currently, without any doubt, patients with advanced/metastatic disease should be treated with imatinib according to

Table 1: Patient characteristics at baseline (n=44)

Variables	n (%)
Median age in years (range)	48 (26-67)
Male gender	23 (52.3)
ECOG performance status	
0-1	41 (93)
2	3 (7)
Presenting symptoms	
Abdominal pain	23 (52)
Weight loss	10 (23)
Lower GI bleeding	6 (14)
Bowel obstruction	5 (11)
Site of primary tumor	
Stomach	27 (61.5)
Small intestine	12 (27)
Rectum	2 (4.5)
Retroperitoneum	2 (4.5)
Mesentery	1 (2.5)
Site of metastases	
Liver	25 (57)
Peritoneum	7 (16)
Lungs	2 (4.5)
Both liver and peritoneum	10 (22.5)

ECOG=Eastern Cooperative Oncology Group, GI=Gastrointestinal

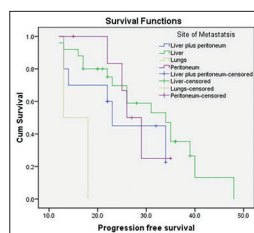


Figure 1: Kaplan-Meier curve of progression-free survival (in months) of metastatic GIST patients, according to different sites of metastases

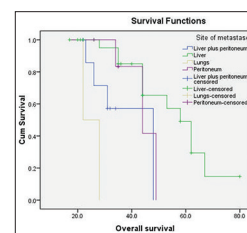


Figure 2: Kaplan-Meier curve of overall survival (in months) of metastatic GIST patients, according to different sites of metastases

the algorithms of ESMO and National Comprehensive Cancer Network.^[12,13] The surgical approach to metastatic disease is currently limited to investigational studies in patients with the stable resectable disease or responsive to imatinib therapy.^[14,15] Those who display disease progression after first-line imatinib therapy will only have a surgical indication in very restricted situations.^[12,13]

In the second-line setting, one option is to increase the dose of imatinib. Unfortunately, this approach is associated with almost doubling of the Grade 3 and 4 toxicity (63% vs. 43%), significantly higher dose reductions (60% vs. 16%) and greater treatment interruptions (64% vs. 40%).^[16,17] The option of sunitinib therapy for GIST became a reality after its approval in 2006 for the treatment of advanced imatinib-resistant GIST or for imatinib-intolerant patients.^[8] For patients with the progressive disease, the decision is based on whether there is limited or extensive systemic disease. Efficacy and safety of sunitinib (37.5 mg/day) versus imatinib (800 mg/day) in this patient population was being evaluated in a Phase IIIb study.^[18] Unfortunately, this was terminated early due to poor recruitment and operational futility. Regorafenib is another TKI with activity against several kinases including KIT, PDGFR, fibroblast growth factor receptor, vascular endothelial cell growth factor receptor-2 (VEGFR2) and 3, TIE-2, and BRAF. In February 2013, the FDA has expanded the approved use of this drug to treat advanced GIST that cannot be surgically removed and no longer respond to imatinib and sunitinib, based on the favorable results of a Phase III trial.^[9]

The demographic data obtained from our study showed a slight male predominance, which is consistent with the published data, where there is a men: women ratio of 1–1.5:1.^[19–21] In relation with the age at presentation, the reported median age in European series is 66–69 years,^[19,20] and in the SEER database is 63 years.^[21] Our results showed a median age, almost one decade lower for the age at the diagnosis, a very relevant figure for the Indian patients. Our findings confirmed the worldwide evidence of liver and peritoneum as the main sites of metastases.

Joensuu *et al.* documented a prolonged clinical response with times surpassing 24 months in patients of metastatic GIST treated with imatinib.^[22] The tumor response rates in metastatic GIST patients, treated with imatinib reported in different studies, showed SD as the main treatment response with ranges of 45%–56%; with CR rates of 2%–5%; and a PR of 20%, which translated into a clinical benefit of 70%–90%, independently of the dose of 400, 600, or 800 mg/day.^[17,11,17,22] The results obtained in our series showed a CR rate of 0%, PR of 29%, and SD in 48% of the patients, providing a 77% clinical benefit.

With respect to the median survival, the study with the longest follow-up (71 months), published by Blanke *et al.*, reported a median survival of 57 months, independently of the imatinib dose.^[23] The current series showed an inferior survival, with an estimated median of 48 months. This difference might be influenced by the dose modifications of imatinib and regimens used at the time of progression on standard first-line therapy. It is worth mentioning that, most of our patients received an

escalated dose of imatinib at the time of progression, and only 5 and 2 patients received sunitinib and regorafenib respectively, as second- and third-line therapy.

There are few published retrospective single center experiences of TKI therapy in advanced/metastatic GIST from India.^[24] Shrikhande *et al.* reported a case series of 29 patients with locally advanced GIST, who were treated with neoadjuvant imatinib before surgery.^[25] With a median duration of 8.5 months imatinib therapy, the reported overall response rate was 79.3%. Five patients, initially considered to have locally unresectable lesions, ultimately underwent resection and another 3 patients with metastatic disease, underwent R2 resection (due to the presence of metastasis) with a complete resection of the primary lesion. Nineteen patients, who would have originally required extensive surgery, underwent conservative surgery (R0). The 3-year OS was 100%. Another study on the preoperative use of imatinib in 10 patients with advanced/metastatic GIST reported 45% median reduction of tumor volume.^[26] Six of 10 patients underwent complete resection of the tumor following neoadjuvant imatinib for a median period of 3 months and were disease-free for a median follow-up of 11 months, with no serious toxicity.

Rajappa *et al.* reported a retrospective series of 50 cases of GIST.^[27] Thirty-five patients with advanced disease were treated with imatinib, and CR was noted in 4 (11.8%); 13 (38.2%) each had PR and SD, and 5 (14.8%) had PD. Responses were not different in groups based on sex, site of primary tumor, and number of metastatic sites. In another retrospective analysis of 49 patients with GIST, imatinib was administered after surgery in patients with high-risk, residual or metastatic disease and at the onset of recurrence or metastatic disease in patients with intermediate risk.^[28] At a median follow-up of 21 months, 2- and 3-year PFS rates were 61% and 39%, respectively, for all patients. The median PFS in the residual and metastatic group was 10 and 29 months, respectively, although the number of patients was small.

In the present study, we performed subgroup analysis according to the primary disease sites and sites of metastases. The median PFS and OS were significantly better in patients with gastric primary than those of the patients with other primary sites ($P < 0.05$); and this finding was consistent with the published literature.^[6,29] We also observed a significant decrease in the median PFS and OS in patients with lung metastases versus the hepatic, peritoneal, and other metastatic sites ($P < 0.05$), establishing pulmonary metastasis as a poor prognostic factor in metastatic GIST.

Conclusions

In the current study, we retrospectively investigated the demographic and clinical features of metastatic GIST cases together with an analysis of potential prognostic factors and their impact on PFS and OS. Imatinib therapy was well-tolerated and induced a sustained clinical benefit in more than half of our patients. Lung metastases seemed to be a poor prognostic factor in patients with metastatic GIST. Further prospective molecular studies are needed to elucidate biological differences and to develop rational strategies for preventing the emergence of resistance to TKI therapy in this patient population.

Financial support and sponsorship

Nil.

Conflicts of interest

There are no conflicts of interest.

References

- Joensuu H, Fletcher C, Dimitrijevic S, Silberman S, Roberts P, Demetri G. Management of malignant gastrointestinal stromal tumours. *Lancet Oncol* 2002;3:655-64.
- Sanders KM, Koh SD, Ward SM. Interstitial cells of Cajal as pacemakers in the gastrointestinal tract. *Annu Rev Physiol* 2006;68:307-43.
- Zhao X, Yue C. Gastrointestinal stromal tumor. *J Gastrointest Oncol* 2012;3:189-208.
- Miettinen M, Wang ZF, Lasota J. DOG1 antibody in the differential diagnosis of gastrointestinal stromal tumors: A study of 1840 cases. *Am J Surg Pathol* 2009;33:1401-8.
- Corless CL, Fletcher JA, Heinrich MC. Biology of gastrointestinal stromal tumors. *J Clin Oncol* 2004;22:3813-25.
- Søreide K, Sandvik OM, Søreide JA, Gudlaugsson E, Mangseth K, Haugland HK. Tyrosine-kinase mutations in c-KIT and PDGFR- α genes of imatinib naïve adult patients with gastrointestinal stromal tumours (GISTs) of the stomach and small intestine: Relation to tumour-biological risk-profile and long-term outcome. *Clin Transl Oncol* 2012;14:619-29.
- Demetri GD, von Mehren M, Blanke CD, Van den Abbeele AD, Eisenberg B, Roberts PJ, *et al.* Efficacy and safety of imatinib mesylate in advanced gastrointestinal stromal tumors. *N Engl J Med* 2002;347:472-80.
- Demetri GD, van Oosterom AT, Garrett CR, Blackstein ME, Shah MH, Verweij J, *et al.* Efficacy and safety of sunitinib in patients with advanced gastrointestinal stromal tumour after failure of imatinib: A randomised controlled trial. *Lancet* 2006;368:1329-38.
- Demetri GD, Reichardt P, Kang YK, Blay JY, Rutkowski P, Gelderblom H, *et al.* Efficacy and safety of regorafenib for advanced gastrointestinal stromal tumours after failure of imatinib and sunitinib (GRID): An international, multicentre, randomised, placebo-controlled, phase 3 trial. *Lancet* 2013;381:295-302.
- Pidhorecky I, Cheney RT, Kraybill WG, Gibbs JF. Gastrointestinal stromal tumors: Current diagnosis, biologic behavior, and management. *Ann Surg Oncol* 2000;7:705-12.
- van Oosterom AT, Judson I, Verweij J, Stroobants S, Donato di Paola E, Dimitrijevic S, *et al.* Safety and efficacy of imatinib (STI571) in metastatic gastrointestinal stromal tumours: A phase I study. *Lancet* 2001;358:1421-3.
- Casali PG, Jost L, Reichardt P, Schlemmer M, Blay JY; ESMO Guidelines Working Group. Gastrointestinal stromal tumors: ESMO clinical recommendations for diagnosis, treatment and follow-up. *Ann Oncol* 2008;19 Suppl 2:ii35-8.
- National Comprehensive Cancer Network. NCCN Clinical Practice Guidelines in Oncology (NCCN Guidelines®). Available from: http://www.nccn.org/professionals/physician_gls/f_guidelines.asp. [Last accessed on 2016 Aug 06].
- Andtbacka RH, Ng CS, Scaife CL, Cormier JN, Hunt KK, Pisters PW, *et al.* Surgical resection of gastrointestinal stromal tumors after treatment with imatinib. *Ann Surg Oncol* 2007;14:14-24.
- DeMatteo RP, Maki RG, Singer S, Gonen M, Brennan MF, Antonescu CR. Results of tyrosine kinase inhibitor therapy followed by surgical resection for metastatic gastrointestinal stromal tumor. *Ann Surg* 2007;245:347-52.
- Verweij J, Casali PG, Zalcberg J, LeCesne A, Reichardt P, Blay JY, *et al.* Progression-free survival in gastrointestinal stromal tumours with high-dose imatinib: Randomised trial. *Lancet* 2004;364:1127-34.
- Blanke CD, Rankin C, Demetri GD, Ryan CW, von Mehren M, Benjamin RS, *et al.* Phase III randomized, intergroup trial assessing imatinib mesylate at two dose levels in patients with unresectable or metastatic gastrointestinal stromal tumors expressing the kit receptor tyrosine kinase: S0033. *J Clin Oncol* 2008;26:626-32.
- Available from: <http://www.clinicaltrials.gov/ct2/show/study/NCT00372567?term=gist+imatinib+sunitinibandrank=4>. [Last accessed on 2011 Jul 07].
- Nilsson B, Bümbling P, Meis-Kindblom JM, Odén A, Dortok A, Gustavsson B, *et al.* Gastrointestinal stromal tumors: The incidence, prevalence, clinical course, and prognostication in the preimatinib mesylate era – A population-based study in western Sweden. *Cancer* 2005;103:821-9.
- Tryggvason G, Gíslason HG, Magnússon MK, Jónasson JG. Gastrointestinal stromal tumors in Iceland, 1990-2003: The Icelandic GIST study, a population-based incidence and pathologic risk stratification study. *Int J Cancer* 2005;117:289-93.
- Tran T, Davila JA, El-Serag HB. The epidemiology of malignant gastrointestinal stromal tumors: An analysis of 1,458 cases from 1992 to 2000. *Am J Gastroenterol* 2005;100:162-8.
- Joensuu H, Roberts PJ, Sarlomo-Rikala M, Andersson LC, Tervahartiala P, Tuveson D, *et al.* Effect of the tyrosine kinase inhibitor STI571 in a patient with a metastatic gastrointestinal stromal tumor. *N Engl J Med* 2001;344:1052-6.
- Blanke CD, Demetri GD, von Mehren M, Heinrich MC, Eisenberg B, Fletcher JA, *et al.* Long-term results from a randomized phase II trial of standard- versus higher-dose imatinib mesylate for patients with unresectable or metastatic gastrointestinal stromal tumors expressing KIT. *J Clin Oncol* 2008;26:620-5.
- Ghadyalpatil NS, Supriya C, Prachi P, Ashwin D, Avanish S. Gastrointestinal cancers in India: Treatment perspective. *South Asian J Cancer* 2016;5:126-36.
- Shrikhande SV, Marda SS, Suradkar K, Arya S, Shetty GS, Bal M, *et al.* Gastrointestinal stromal tumors: Case series of 29 patients defining the role of imatinib prior to surgery. *World J Surg* 2012;36:864-71.
- Das D, Ganguly S, Deb AR, Aich RK. Neoadjuvant imatinib mesylate for advanced primary and metastatic/recurrent gastro-intestinal stromal tumour (GIST). *J Indian Med Assoc* 2013;111:21-3.
- Rajappa S, Muppavarapu KM, Uppin S, Digumarti R. Gastrointestinal stromal tumors: A single institution experience of 50 cases. *Indian J Gastroenterol* 2007;26:225-9.
- Kapoor R, Khosla D, Kumar P, Kumar N, Bera A. Five-year follow up of patients with gastrointestinal stromal tumor: Recurrence-free survival by risk group. *Asia Pac J Clin Oncol* 2013;9:40-6.
- Heinrich MC, Corless CL, Demetri GD, Blanke CD, von Mehren M, Joensuu H, *et al.* Kinase mutations and imatinib response in patients with metastatic gastrointestinal stromal tumor. *J Clin Oncol* 2003;21:4342-9.