

Letter to the Editor

Lorlatinib in anaplastic lymphoma kinase-positive non-small cell lung cancer: Indian experience

DOI: 10.4103/sajc.sajc_364_19

Dear Editor,

Lung cancer treatment is rapidly evolving and an excellent example of precision medicine. Outcome of anaplastic lymphoma kinase (ALK)-positive non-small cell lung cancer (NSCLC) has improved significantly with recent report showing survival of 56% at 4 years.^[1] This has been possible due to availability of effective sequential treatment. One of the important drugs has been lorlatinib. This has found to be effective in second line and beyond setting after crizotinib.^[2] There has been no data from India regarding its safety and efficacy. We retrospectively analyzed the data of patients receiving lorlatinib in our hospital. Patients diagnosed with ALK-positive advanced NSCLC who have received lorlatinib between January 2018 and September 2019 who have progressed on crizotinib were included. Lorlatinib was administered orally in a tablet form at a starting dose of 100 mg once daily continuously in 21-day cycles.

The details of these patients were obtained from the lung cancer audit database that is maintained in the department of medical oncology. Demography (age, gender, comorbidity, and smoking status), disease status, and therapy details were recorded. ALK amplified status was ascertained either by immunohistochemistry (monoclonal antibody D5F3 [Ventana Medical Systems, Tucson, AZ, USA]) or FISH analysis (Abbot Molecular platform). Response assessment was performed every 2–4 months as per institutional practice and evaluated by RECIST 1.1 criteria. Toxicity during this period was evaluated in accordance with the Common Terminology Criteria for Adverse Events version 4.02. Date of disease progression, date of change in treatment, and date of death were recorded. SPSS version 21

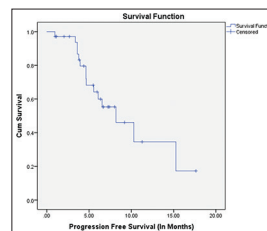


Figure 1: Mean progression-free survival in patients on lorlatinib of 9.6 months (range: 7.1–12.1 months) (number of events – 15)

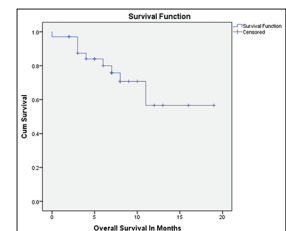


Figure 2: Kaplan–Meier curve depicting overall survival from the day of starting lorlatinib (in months) (number of events – 9). The estimated mean overall survival was 13.6 months (range, 10.6–16.6 months)

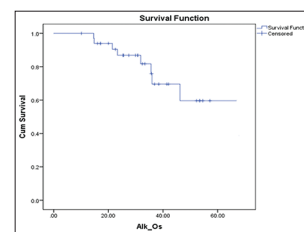


Figure 3: Kaplan–Meier curve depicting overall survival of patients from the day of diagnosis (in months), (number of events – 9) 53.5 months (44.8–62.2 months)

All analyses were performed using SPSS Statistics for Windows software, version 20.0 (SPSS, Chicago, IL). was used for analysis. Response rate, progression-free survival (PFS), and overall survival were calculated. Response rate was calculated for the best response to treatment. PFS was calculated from starting lorlatinib to events of disease progression, death without disease progression, and change in treatment other than disease progression. Overall survival was calculated from the date of starting lorlatinib to the date of death and separately overall survival was also calculated from the date of diagnosis to the date of death.

Tables 1 and 2 summarize baseline characteristics and side effects of lorlatinib. Out of 34 evaluable patients,

Table 1: Baseline characteristics of patients treated with lorlatinib

Demographic (<i>n</i> =34)	Number
Median age (years) (range)	49 (23-67)
Gender, <i>n</i> (%)	
Female	19 (56)
Male	15 (44)
History of smoking/tobacco use, <i>n</i> (%)	
Yes	12 (35.3)
No	22 (64.7)
Histopathology, <i>n</i> (%)	
Adenocarcinoma	27 (79.4)
Adenosquamous carcinoma	4 (11.8)
Adenocarcinoma with neuroendocrine	3 (8.8)
Comorbidities, <i>n</i> (%)	
Diabetes mellitus	6 (17.6)
Hypertension	4 (11.8)
Chronic lung disease	1 (2.9)
Multiple	2 (5.9)
Rheumatic heart disease	1 (2.9)
None	20 (58.8)
Line of lorlatinib use, <i>n</i> (%)	
3	18 (52.9)
4	11 (32.4)
5	4 (11.8)
6	1 (2.9)
Best responses (total evaluable - 34), <i>n</i> (%)	
Complete response	2 (5.9)
Partial response	17 (50)
Stable disease	11 (32.4)
Progressive disease	4 (11.8)

Table 2: Adverse effects of lorlatinib

Adverse event (all grade)	<i>n</i> (%)
Transaminitis	10 (29.4)
Hypercholesterolemia	32 (94.1)
Hypertriglyceridemia	32 (94.1)
Anemia	8 (23.5)
Nausea	18 (53)
Hypophosphatemia	2 (5.8)
Edema	14 (41.1)
Increased lipase/amylase	4 (11.7)
Weight gain	8 (23.5)

2 (5.9%) and 17 (50%) had complete and partial responses [Table 1], respectively. The estimated mean PFS in our study was 9.6 months (range, 7.1–12.1 months) [Figure 1]. The estimated mean overall survival was 13.6 months [Figure 2] (range, 10.6–16.6 months) with median not reached because of low number of events (*n* = 9). Our results are comparable to that reported in the literature.^[2] The estimated mean overall survival of ALK patients was 53.5 months (44.8–62.2 months) [Figure 3].

We report clinical outcomes of ALK-positive NSCLC on crizotinib who had progressive disease and were treated with lorlatinib. We find it an important new treatment option form.

Financial support and sponsorship

Nil.

Conflicts of interest

There are no conflicts of interest.

Vikas T. Talreja, Vanita Noronha, Vijay M. Patil, Amit Joshi, Kumar Prabhash

Department of Medical Oncology, Tata Memorial Hospital, Mumbai, Maharashtra, India

Correspondence to: Dr. Kumar Prabhash,
E-mail: kumarprabhashtmh@gmail.com

References

- Solomon BJ, Kim DW, Wu YL, Nakagawa K, Mekhail T, Felip E, *et al*. Final overall survival analysis from a study comparing first-line crizotinib versus chemotherapy in ALK-mutation-positive non-small-cell lung cancer. *J Clin Oncol* 2018;36:2251-8.
- Solomon BJ, Besse B, Bauer TM, Felip E, Soo RA, Camidge DR. Lorlatinib in patients with ALK-positive non-small cell lung cancer: Results from a global phase 2 study. *Lancet Oncol* 2018;19:1654-67.

This is an open access journal, and articles are distributed under the terms of the Creative Commons Attribution-NonCommercial-ShareAlike 4.0 License, which allows others to remix, tweak, and build upon the work non-commercially, as long as appropriate credit is given and the new creations are licensed under the identical terms.

How to cite this article: Talreja VT, Noronha V, Patil VM, Joshi A, Prabhash K. Lorlatinib in anaplastic lymphoma kinase-positive non-small cell lung cancer: Indian experience. *South Asian J Cancer* 2020;9:67-8.

© 2019 The South Asian Journal of Cancer | Published by Wolters Kluwer - Medknow