

Adequacy of surgical margins in oral cancer patients with respect to various types of reconstruction

Apurva Garg, Manish Mair, Hitesh Singhavi, Muddasir Bhati, Akshat Malik, Aseem Mishra, Deepa Nair, Sudhir Nair, Pankaj Chaturvedi

Abstract

Background: Surgical margin is an important prognostic factor for oral cancers (oral squamous cell carcinoma [OSCC]). The correlation of margin with the type of reconstruction has never been studied. **Aim:** This study aimed to correlate surgical margins with the type of reconstruction. **Methods:** This was a retrospective study of 410 treatment-naïve OSCC patients. As per the methods of reconstruction, three groups were made when reconstruction was performed using pedicled flap (PF) or local flap, free flap, and primary closure (PC). **Statistical Analysis:** Chi-square test was used for comparison of margin status as per the method of reconstruction. Mann–Whitney test was used to find the difference between the mean margin width with respect to the type of reconstruction. **Results:** The overall incidence of close/positive margins was 7.8%. The incidence of close/positive margins was not significantly different in free flap group compared to PF ($P = 0.06$) or PC ($P = 0.835$) group. However, there was a significant difference in the incidence of close/positive margins between PC and PF groups ($P = 0.021$). Whether the reconstruction is performed by the primary surgeon or by another surgeon, it did not have an impact on adequacy of margins ($P = 0.334$). Margins were wider when the reconstruction is performed by a different team ($P = 0.015$) or when reconstruction is performed as compared to PC. **Conclusion:** Margins are not affected by the type of reconstruction (pedicled vs. free flap) and the team doing reconstruction (same vs. another team). Margins are significantly compromised when a surgeon performs PC himself/herself compared to PF.

Key words: Free flap, margins, oral cancers, primary closure, reconstruction

Introduction

Oral cancer is a major problem worldwide, with 300,373 new cases detected in 2012.^[1] Among the various prognostic factors affecting survival in oral cancers, surgical margin status is one of the most important factors.^[2–5] Local failures are more common when the resection margins are inadequate.^[6] Moreover, surgical margin status is mainly under the control of the operating surgeon.^[3,7] One of the basic principles of head and neck oncosurgery is that the surgical margin should not be influenced by surgeon's intent of reconstruction. Few institutes have even divided the ablative and reconstructive teams to avoid inadequate resection margins and reduce the fatigue of surgeons. After oral cancer surgery, the surgical defect can be closed by primary closure (PC), local flaps/pedicled flap (PF), or free flaps. The volume of tissue available for reconstruction with local or PF is limited, and this might force the surgeon to compromise on the resection margins. Free flaps are more versatile for reconstruction in oral surgeries. However, free flap requires more surgical time and resources adding to the overall time and cost of treatment.^[8] It is believed that surgeons may tend to take wider margins when a decision has been made to proceed with a microvascular reconstruction done by another surgeon.^[9] Needless to say, the surgeon should aim at tumor-free margin of at least 5 mm in final histopathology report, irrespective of the plan of reconstruction. The purpose of this study is to determine the difference in adequacy of surgical margins by the primary surgeon with respect to various types of reconstruction.

Methods

This was a retrospective study of 410 treatment-naïve oral squamous cell carcinoma patients treated at a tertiary cancer center between December 2013 and March 2015. All patients

were evaluated before surgery with history, clinical examination, complete hemogram, blood biochemistry, head and neck magnetic resonance imaging, or computed tomography scan. The primary treatment for all patients was surgery followed by adjuvant treatment whenever required. As per the method of reconstruction, they were divided into three groups: Group 1 in which reconstruction was performed by the primary surgeon using PF or local flap ($n = 149$), Group 2 in which reconstruction was done by the plastic surgeon using free flap ($n = 150$), and Group 3 in which no reconstruction was required and the defect was closed primarily ($n = 111$). The clinical and demographic details of these patients were obtained from the electronic medical records. The distance of all margins mentioned in the final histopathology report was noted, but the closest margin was considered for comparison between the different groups. A mucosal/bony margin of <5 mm was considered close and ≤ 1 mm was considered positive. Mucosal/bony margins ≥ 5 mm were considered adequate.

Statistical analysis

The statistical analysis was done using SPSS 21 Software (IBM Corp., Armonk, NY) by IBM for windows. Chi-square test was used for comparison of margin status as per the method of reconstruction. Mann–Whitney test was used to find the difference between the mean margin width with respect to the type of reconstruction. The mean margin width was the mean distance of the tumor from the mucosal cut margin.

Results

The median age of presentation of our patients was 50 years (range 14–82 years). The majority of cases were male (358/410, 87.3%) with a male-to-female ratio of 6.8:1. Buccal mucosa was the most common primary site seen in 68.04% (279/410) of patients. At the time of presentation, locally advanced tumors were

This is an open access journal, and articles are distributed under the terms of the Creative Commons Attribution-NonCommercial-ShareAlike 4.0 License, which allows others to remix, tweak, and build upon the work non-commercially, as long as appropriate credit is given and the new creations are licensed under the identical terms.

For reprints contact: reprints@medknow.com

How to cite this article: Garg A, Mair M, Singhavi H, Bhati M, Malik A, Mishra A, et al. Adequacy of surgical margins in oral cancer patients with respect to various types of reconstruction. South Asian J Cancer 2020;9:34-7.

Access this article online

Quick Response Code:



Website: www.sajc.org

DOI: 10.4103/sajc.sajc_366_18

Department of Head and Neck Oncology, Tata Memorial Hospital, Mumbai, Maharashtra, India
Correspondence to: Dr. Manish Mair,
 E-mail: manishmair@gmail.com

seen in 294/410 (71.1%) patients. As expected, most of the patients in pedicled (85.9%) and free flap (88.6%) groups were locally advanced whereas patients in the PC group were early cancers (70.2%). Similarly, wide local excision was the most common procedure performed in the PC group while segmental or bialveolar resection was the most common procedure performed in the pedicled and free flap groups. Nodal metastasis was seen in 41.7% (171/410) of patients. The tumor and patients characteristics are described in Table 1. The most common PF done was pectoralis major myocutaneous (PMMC) (30.7%). The most common free flap used for reconstruction was free fibula osteocutaneous flap (19.3%) followed by free anterolateral thigh flap (12.2%) [Table 2]. The overall incidence of close/positive margins was 7.8%. The incidence of close/positive margins in all three group is shown in Figure 1.

Comparison of margins in free flaps versus pedicled flaps

Even though the incidence of close or positive margins was higher in the free flap (9.3%) as compared to the PF (3.4%) groups, it was not statistically significant ($P = 0.06$). The mean distance of the tumor from the mucosal cut margins, i.e., mean margin width in the free flap group, was 7.8 mm and in the PF group was 7.49 mm ($P = 0.314$) [Table 3].

Comparison of margins in pedicled flaps versus primary closure

The incidence of close or positive margins was significantly higher in the PC (10.8%) group as compared to the PF group (3.4%) ($P = 0.021$) [Table 4]. Interestingly, the mean margin width was significantly higher in the PF (7.49 mm) as compared to the PC group (6.4 mm; $P = 0.007$).

Comparison of margins in primary closure and free flap

There was no significant difference in the incidence of close or positive margins in both these groups ($P = 0.835$) [Table 5]. However, the mean margin width was significantly higher

in the free flap (7.8 mm) group as compared to the PC group (6.4 mm) ($P = 0.007$).

Comparison of margins when reconstruction is done by the primary surgeon or by a different team

For comparison between these subgroups, we included patients with PC, local, and PFs in one group as these flaps were done by the primary surgeon. The other group consisted of patients in which free flap was done, by an another reconstructive team. There was no significant difference in the incidence of close/positive margins between these two groups ($P = 0.334$). However, the mean margin width was significantly higher when reconstruction was done by a different team (7.8 mm) as compared to those cases where reconstruction was done by the primary surgeon (7 mm; $P = 0.015$).

Discussion

Oral cancers are managed mainly by surgical approaches, guided by the fundamental principle that complete tumor resection with adequate margins is required for successful treatment. Involved and close margins are associated with higher recurrence rates.^[6] Sutton *et al.* have previously defined histological factors, which were associated with poorer surgical margins in oral cavity cancer.^[3] Perineural invasion, vascular invasion, greater tumor size, and more aggressive tumors were all found to be independently associated with close or involved surgical margins. However, literature on the method

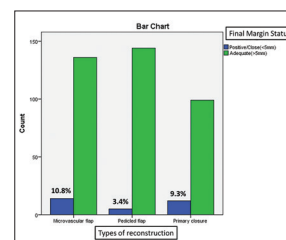


Figure 1: Status of surgical margins in all three groups

Table 1: Clinical features of patients in all three groups

Parameters assessed	Free flap (n=150), n (%)	PFs (n=149), n (%)	Primary closure (n=111), n (%)
Age			
Mean	49	50	50
Median	50	49	50
Gender			
Male	122 (81.3)	141 (94.6)	95 (85.6)
Female	28 (18.7)	8 (5.4)	16 (14.4)
T stage			
T1	0 (0)	8 (5.3)	37 (33.3)
T2	17 (11.3)	13 (8.7)	41 (36.9)
T3	12 (8)	18 (12.08)	11 (9.9)
T4	121 (80.6)	110 (73.82)	22 (19.8)
Nodal metastasis			
Node negative	87 (58)	68 (45.6)	84 (75.6)
Node positive	63 (42)	81 (54.3)	27 (24.3)
Site of malignancy			
BM	135 (90)	111 (74.4)	33 (29.7)
Tongue + floor of mouth	15 (10)	38 (25.5)	78 (70.2)
Procedure for primary			
WLE tongue/BM	10 (6.6)	18 (12.2)	82 (73.8)
Marginal	8 (5.3)	10 (6.7)	9 (8.1)
Hemimandibulectomy/segmental mandibulectomy	88 (58.6)	62 (41.6)	19 (17.1)
Bialveolar resection	44 (29.3)	59 (39.5)	1 (0.9)

WLE=Wide local excision, BM=Buccal mucosa, PFs=Pedicled flaps

Table 2: Distribution of patients as per the plan of reconstruction

Type of flaps	Number PF patients (%)
Free flaps	150/410 (36.58)
Free fibula osteocutaneous flap	79 (19.3)
Free anterolateral thigh flap	50 (12.2)
Free radial forearm flap	21 (5.1)
PF/local flap	149/410 (36.34)
Pectoralis myocutaneous flap	126 (30.7)
Nasolabial flap	1 (0.2)
Masseter flap	22 (5.4)
Primary closure	111/410 (27.07)

PF=Pedicled flap

Table 3: Comparison of margin between free flap and pedicled flap

Margin	Free flap (n=150)	PF (n=149)	P
Close	13 (9.3)	5 (3.4)	0.06
Adequate	137 (90.7)	144 (96.6)	-
Mean closest (mm)	7.8	7.49	0.314

PF=Pedicled flap

Table 4: Comparison of margin between pedicled and primary closure

Margin	Primary closure (n=111)	PF (n=149)	P
Close	12 (10.8)	5 (3.4)	0.021
Adequate	99 (89.2)	144 (96.6)	-
Mean closest (mm)	6.4	7.49	0.007

Table 5: Comparison of margins between primary closure and free flap

Margin	Free flap (n=150)	Primary closure (n=111)	P
Close	13 (9.3)	12 (10.8)	0.835
Adequate	137 (90.7)	99 (89.2)	-
Mean closest (mm)	7.8	6.4	0.001

of reconstruction and its impact on surgical margins is sparse. In addition, there is no publication comparing the adequacy of margins when reconstruction is performed by the primary surgeon or a different reconstructive team.

Worldwide, there is a debate regarding the optimal reconstruction options for large defects in oral cancer, especially in a low-resource setting. Free tissue transfer has been widely adopted in most head and neck units for primary reconstruction because of its excellent reliability and the advantage it offers in terms of esthetics, function, and quality of life.^[9] However, there is a significant difference with regard to expertise required, hospital charges, ICU stay, and total operative time for free flaps.^[8] Thus, PFs are preferred in developing countries that have limited resources. One of the most common PFs used is PMMC flap. It was first described by Aryan in 1979, and since then, it has been the workhorse of oral cancer defects. This flap is versatile and suited for resource-challenged developing countries because it has robust blood supply and requires lesser operating time.^[10] However, the use of free flap with its introduction in the 1980s has increased considerably. It has an advantage of better malleability and cosmesis as compared to PF. Performing a free flap procedure can influence the outcome of the surgical margins. It could theoretically improve the surgical margins by allowing the surgeon to remove more tissue; conversely, it could also compromise

margins by influencing the surgeon to retain important landmarks. The influence of this factor is not yet completely understood.

We found that the incidence of close/positive margin was not significantly different in the free flap (9.8%) compared to the PF (3.4%; $P = 0.06$) or PC (10.8%; $P = 0.835$) groups. Similarly, Hsieh *et al.*^[11] did not find any significant difference in the incidence of positive margins between the free flap (12.1%) and PF (17.2%) groups ($P = 0.213$). A retrospective review of 98 patients treated in a single unit over a 20-year period by de Vicente *et al.*^[12] also showed no difference in the incidence of positive margins between the free flap and pedicled or local flap groups. The incidence of close margin was studied among free flap versus PFs by Hsieh *et al.* (9.7% vs. 14.1%) and the difference was not statistically significant ($P = 0.194$).

However, a 25-year retrospective review of 135 patients at the MD Anderson Cancer Center for surgically treated patients with T3 and T4 disease showed that there was a significant difference in the incidence of positive margins between free flap (18%) and nonmicrosurgical cohort (7%).^[13] Similarly, the incidence of close or positive margins in breast cancer patients was significantly more in the conventional surgery group versus the oncoplastic group (25% vs. 9%; $P = 0.02$).^[14]

We found that the incidence of close or positive margin in PC (10.8%) was significantly higher as compared to PF (3.4%) group. This could possibly be due to the paucity of local tissue that can be used for adequate PC. It is likely that primary surgeons, in their attempt to preserve as much local tissue, may compromise on the adequate resection. This highlights the “excision bias” when a surgeon has planned the reconstruction even before the primary tumor is resected. The possible way to avoid this bias is to plan the reconstruction only after resection of the primary tumor.

We found that the mean margin width was significantly higher when reconstruction is done by a different team; it was also seen that the mean margin width was higher when free flap (7.8 mm) or PF (7.49 mm) was done as compared to PC (6.4 mm). Thus, we can conclude that primary surgeon is more liberal in taking mucosal margins when reconstruction is planned as compared to the plan of PC. He/she is also more liberal when reconstruction is performed by a different surgeon. There is no literature on the mean margin width for oral cancers correlated with the type of reconstruction. However, similar results were reported in breast cancer patients by Chauhan and Sharma^[14] who evaluated the surgical outcomes of conventional breast surgery versus oncoplastic breast surgery. They showed that the mean margin widths were significantly more in oncoplastic group versus conventional surgery group (14 mm vs. 6 mm; $P = 0.01$).

The study has its own limitations – being retrospective in nature. However, this question can never be answered by a prospective study as it may compromise reconstruction in deserving patients. Survival outcomes are also not analyzed in this study as they are dependent on many other factors and thus comparison of survival between these groups may be biased.

Conclusion

This study concluded that there was no difference in the margin status when reconstruction was performed by either the pedicled or free flap. The primary surgeon is more liberal in excision of the margins when reconstruction is to be performed by pedicled or free flap compared to PC. For similar reasons, the South Asian Journal of Cancer ♦ Volume 9 ♦ Issue 1 ♦ January-March 2020

surgical margins are wider when reconstruction is performed by a different team. However, the margins are more likely to be compromised when the surgeon himself or herself performs the PC compared to PF. Therefore, to prevent such a bias, the plan of reconstruction should be decided only after performing resection of the primary tumor.

Financial support and sponsorship

Nil.

Conflicts of interest

There are no conflicts of interest.

References

1. GLOBOCAN; 2012. Available from: http://www.globocan.iarc.fr/old/summary_table_pop-html.asp?selection=224900&title=World&sex=0&type=0&window=1&sort=0&submit=%C2%A0Execute%C2%A0. [Last accessed on 2017 Oct 15].
2. Woolgar JA, Scott J, Vaughan ED, Brown JS, West CR, Rogers S, *et al.* Survival, metastasis and recurrence of oral cancer in relation to pathological features. *Ann R Coll Surg Engl* 1995;77:325-31.
3. Sutton DN, Brown JS, Rogers SN, Vaughan ED, Woolgar JA. The prognostic implications of the surgical margin in oral squamous cell carcinoma. *Int J Oral Maxillofac Surg* 2003;32:30-4.
4. Loree TR, Strong EW. Significance of positive margins in oral cavity squamous carcinoma. *Am J Surg* 1990;160:410-4.
5. Chandu A, Adams G, Smith AC. Factors affecting survival in patients with oral cancer: An Australian perspective. *Int J Oral Maxillofac Surg* 2005;34:514-20.
6. Spiro RH, Guillaumondegui O Jr., Paulino AF, Huvos AG. Pattern of invasion and margin assessment in patients with oral tongue cancer. *Head Neck* 1999;21:408-13.
7. Mair M, Nair D, Nair S, Dutta S, Garg A, Malik A, *et al.* Intraoperative gross examination vs. frozen section for achievement of adequate margin in oral cancer surgery. *Oral Surg Oral Med Oral Pathol Oral Radiol* 2017;123:544-9.
8. Forner D, Phillips T, Rigby M, Hart R, Taylor M, Trites J, *et al.* Submental island flap reconstruction reduces cost in oral cancer reconstruction compared to radial forearm free flap reconstruction: A case series and cost analysis. *J Otolaryngol Head Neck Surg* 2016;45:11.
9. Edwards SP. Margin analysis-has free tissue transfer improved oncologic outcomes for oral squamous cell carcinoma? *Oral Maxillofac Surg Clin North Am* 2017;29:377-81.
10. McCrory AL, Magnuson JS. Free tissue transfer versus pedicled flap in head and neck reconstruction. *Laryngoscope* 2002;112:2161-5.
11. Hsieh TY, Chang KP, Lee SS, Chang CH, Lai CH, Wu YC, *et al.* Free flap reconstruction in patients with advanced oral squamous cell carcinoma: Analysis of patient survival and cancer recurrence. *Microsurgery* 2012;32:598-604.
12. de Vicente JC, Rodríguez-Santamarta T, Rosado P, Peña I, de Villalaín L. Survival after free flap reconstruction in patients with advanced oral squamous cell carcinoma. *J Oral Maxillofac Surg* 2012;70:453-9.
13. Hanasono MM, Friel MT, Klem C, Hsu PW, Robb GL, Weber RS, *et al.* Impact of reconstructive microsurgery in patients with advanced oral cavity cancers. *Head Neck* 2009;31:1289-96.
14. Chauhan A, Sharma MM. Evaluation of surgical outcomes following oncoplastic breast surgery in early breast cancer and comparison with conventional breast conservation surgery. *Med J Armed Forces India* 2016;72:12-8.