

Letter to the Editor

Isolated central nervous system blast crisis in a case of chronic myeloid leukemia on dasatinib

DOI: 10.4103/sajc.sajc_63_18

Dear Editor,

Chronic myeloid leukemia (CML) is a myeloproliferative disorder that has three distinguished phases: chronic, accelerated, and blastic. It is characterized by reciprocal exchange of genetic material between chromosome 9 and 22, with the formation of new gene BCR-ABL, a proto-oncogene which increases cellular proliferation and decreases apoptosis or both.^[1] Blast phase (BP) or blast crisis is defined as the presence of 20% or more blasts in peripheral blood or bone marrow (BM), or a large focus of blasts in BM, or an extramedullary blast proliferation.^[2] The central nervous system (CNS) as a site of extramedullary blast crisis is

extremely rare,^[3] and when affected, it usually occurs concurrently with systemic relapse.^[4]

Isolated CNS blast crises however is uncommon and is limited to occasional case reports.^[3] We report a case of CML that experienced blast crisis of the CNS although having achieved complete cytogenetic remission in the BM with dasatinib treatment.

A 30-year-old male patient presented with fever with bilateral lobar pneumonia and complaints of gradually progressive distension of abdomen and subconjunctival hemorrhage to our hospital in December 2016. The patient was evaluated and found to have subarachnoid hemorrhage, and arterial blood gas showed severe hypoxia and respiratory acidosis; the patient was shifted to ICU in view of respiratory distress and intracranial bleed (SAH). The patient also had huge splenomegaly causing distension of abdomen. His routine blood investigations, BM aspiration, and biopsy revealed to be

(Continue on page 182...)

(Letter to the editor continue from page 170...)

CML in blast crisis. Karyotyping showed t(9;22) (q34;q11), and Rq-PCR for BCR-ABL was done which showed 64% transcripts.

Patient was started on azacytidine-based chemotherapy and tablet dasatinib. He received 4 cycles of azacytidine and later was continued with tablet dasatinib 70 mg BID. The patient came for follow-up in June 2017. On evaluation, routine blood investigations were normal. BM aspiration and biopsy showed normocellular marrow and trilineage hematopoiesis. BCR-ABL quantitative by RT-PCR assay showed 0%, suggestive of complete molecular response. The patient was planned for allogeneic hematopoietic stem cell transplant (HSCT). While undergoing pretransplant evaluation, the patient complained of headache, vomiting, and giddiness in July 2017 for which he was admitted. MRI brain was done which showed chronic lacunar infarcts and hemosiderin deposition secondary to chronic SAH with subtle enhancement of concern for meningitis. Lumbar puncture (LP) cerebrospinal fluid (CSF) analysis showed cell count of 1050 cell/mcl, glucose 31 mg/dl, protein 90 mg/dl, chloride 120 meq/L, and smears showing mixed inflammatory cell infiltrate composed of neutrophils, metamyelocytes, and few lymphocytes. The patient was started on empirical antibiotics. CSF culture was sterile. He was symptomatically better. LP-CSF was repeated after 5 days which showed cell count of 2600 cells/mcl, smears showing neutrophils, band forms, and metamyelocytes with a few myelocytes and occasional blast-like cells [Figure 1], Biochemistry showed, glucose 36 mg/dl, protein 54 mg/dl, and chloride 122 meq/L. Repeat BCR-ABL quantitative by RT-PCR was 0% suggestive of molecular response. The patient was diagnosed as isolated CNS blast crisis and was planned for intrathecal chemotherapy with methotrexate 12 mg, cytarabine 30 mg, and hydrocortisone 50 mg. The patient received 2 doses of intrathecal chemotherapy after which he developed cognitive impairment. The patient was planned and received craniospinal irradiation after which symptoms improved. Repeat CSF showed no abnormal cells. He was advised to continue tablet dasatinib, and allogeneic HSCT was postponed in view of financial constraints.

CML, a clonal stem cell disorder, is characterized by fusion of BCR and ABL genes with constitutive overactivity of tyrosine kinase. CML runs a triphasic course, most patients being diagnosed in chronic phase, which evolves into BP within 4–5 years if untreated. BP of CML is defined either by the presence of more than 20% blasts in the peripheral blood/BM or alternatively in 5%–10% of cases, by the focal accumulation of blasts in the extramedullary sites.^[5] CNS

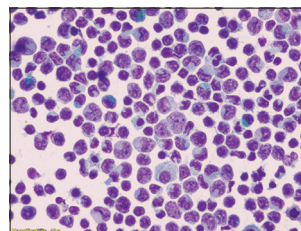


Figure 1: Cerebrospinal fluid picture showing blast cells

involvement by extramedullary blast crises is rare and usually accompanies systemic involvement. Isolated CNS blast crises however is uncommon and is limited to occasional case reports.^[3] Headache and vomiting are the most common clinical manifestations of CNS relapse and require CSF evaluation by cyto-spin and immunophenotyping of atypical cells for diagnosis. Papilloedema and leptomeningeal enhancement represents the most common fundus and imaging findings, respectively. In our case, the patient had persistent headache and vomiting and CSF showed myeloid precursors and blasts in the absence of systemic involvement. The patient was on tablet dasatinib maintenance. Single cases of isolated CNS blast crises have also been depicted, in patients under dasatinib.^[6] This may generally be caused by decreased levels of the drugs being found in the CNS.^[3] The history of CNS involvement before hematopoietic stem cell transplantation has been identified as significant predictors for CNS relapse after hematopoietic stem cell transplantation.^[6] Most of the reported cases were treated with combined intrathecal chemotherapy (variable combination of methotrexate, cytarabine, and dexamethasone/hydrocortisone) and craniospinal irradiation. Combined therapy was found superior to the intrathecal treatment alone in terms of treatment outcome.^[7] In our case, the patient was treated with both intrathecal chemotherapy and craniospinal irradiation. Papageorgiou *et al.* reported one case of Ph + acute megakaryoblastic leukemia who received 140 mg dasatinib daily and maintained stable disease for 16 months. However, the patient experienced CNS relapse following treatment with a de-escalated daily dose of 70 mg daily due to pleural effusion.^[7] Frigeri *et al.* also presented a case of Ph + CNS leukemia in which dasatinib failed to prevent CNS progression. However, this patient was administered <100 mg dasatinib daily during the treatment course.^[8] Our patient developed CNS relapse inspite of taking tablet dasatinib at a dose of 140 mg/day. Hence, apart from biology of the disease, dose of dasatinib and other factors may play a role in disease progression, but data are limited in this regard to come to a conclusion.

In patients with treated CML, the rare case of an isolated CNS blast crisis has to be taken into account if neurological

(Continue on page 187...)

(Letter to the editor continue from page 182...)

symptoms evolve even after achieving complete cytogenetic and molecular BM response. LP is essential, and isolated CNS relapse of leukemia can be controlled by intrathecal chemotherapy and craniospinal irradiation. Furthermore, it appears that dose intensity of dasatinib is essential for optimal efficacy.

Declaration of patient consent

The authors certify that they have obtained all appropriate patient consent forms. In the form the patient(s) has/have given his/her/their consent for his/her/their images and other clinical information to be reported in the journal. The patients understand that their names and initials will not be published and due efforts will be made to conceal their identity, but anonymity cannot be guaranteed.

Acknowledgment

We would like to thank Dr. Sharitha, Department of Pathology, HCG Hospital, Bengaluru.

Financial support and sponsorship

Nil.

Conflicts of interest

There are no conflicts of interest.

P. K. Kiran, Girish V. Badarke¹, C. N. Suresh¹, B. J. Srinivas, Radheshyam Naik

Departments of Medical Oncology and ¹Hematology, Healthcare Global Enterprises Hospital, Bengaluru, Karnataka, India

Correspondence to: Dr. P. K. Kiran,
E-mail: drkiranpk265@gmail.com

References

1. Greer JP, Arber DA, Glader B, List AF, Means RT Jr., Paraskevas F, *et al.* Wintrobe's Clinical Hematology. 13th ed. UK:LWW;2013.

2. Swerdlow SH, Campo E, Harris NL, Jaffe ES, Pileri SA, Stein H, *et al.* WHO Classification of Tumours of Haematopoietic and Lymphoid Tissues. 4th ed. Lyon, France: IARC Press; 2008.
3. Rajappa S, Uppin SG, Raghunadharao D, Rao IS, Surath A. Isolated central nervous system blast crisis in chronic myeloid leukemia. *Hematol Oncol* 2004;22:179-81.
4. Pfeifer H, Wassmann B, Hofmann WK, Komor M, Scheuring U, Brück P, *et al.* Risk and prognosis of central nervous system leukemia in patients with Philadelphia chromosome-positive acute leukemias treated with imatinib mesylate. *Clin Cancer Res* 2003;9:4674-81.
5. Altintas A, Cil T, Kilinc I, Kaplan MA, Ayyildiz O. Central nervous system blastic crisis in chronic myeloid leukemia on imatinib mesylate therapy: A case report. *J Neurooncol* 2007;84: 103-5.
6. Oshima K, Kanda Y, Yamashita T, Takahashi S, Mori T, Nakaseko C, *et al.* Central nervous system relapse of leukemia after allogeneic hematopoietic stem cell transplantation. *Biol Blood Marrow Transplant* 2008;14:1100-7.
7. Papageorgiou SG, Pappa V, Economopoulou C, Tsirigotis P, Konsiotti F, Ionnidou ED, *et al.* Dasatinib induces long-term remission in imatinib-resistant Philadelphia chromosome-positive acute megakaryoblastic leukemia but fails to prevent development of central nervous system progression. *Leuk Res* 2010;34:e254-6.
8. Frigeri F, Arcamone M, Luciano L, Di Francia R, Pane F, Pinto A, *et al.* Systemic dasatinib fails to prevent development of central nervous system progression in a patient with BCR-ABL unmutated Philadelphia chromosome-positive leukemia. *Blood* 2009;113:5028-9.

This is an open access journal, and articles are distributed under the terms of the Creative Commons Attribution-NonCommercial-ShareAlike 4.0 License, which allows others to remix, tweak, and build upon the work non-commercially, as long as appropriate credit is given and the new creations are licensed under the identical terms.

How to cite this article: Kiran PK, Badarke GV, Suresh CN, Srinivas BJ, Naik R. Isolated central nervous system blast crisis in a case of chronic myeloid leukemia on dasatinib. *South Asian J Cancer* 2018;7:170-87.

© 2018 The South Asian Journal of Cancer | Published by Wolters Kluwer - Medknow

ICON
39th ICON Conference
8-9 Sept 2018, Indore
Dr PM Parikh - purvish1@gmail.com
www.OncologyIndia.org
Conference Organizer : Kashish Parikh
+91-98190-25850 and kashishparikh@gmail.com

4th MOSCon
16-17 Feb 2019, New Delhi
Dr Randeep Singh - drrandeep@yahoo.co.in
www.moscon.info
Conference Organizer : Kashish Parikh
+91-98190-25850 and kashishparikh@gmail.com