

Lymph node metastasis in extremity chondrosarcomas: A series of four cases

Vineet Kurisunkal, Ashish Gulia, Ajay Puri, Bharat Rekhi

Abstract

Background: Primary bone sarcomas mainly metastasize through haematogenous route and rarely through lymph nodes due to paucity of lymphatic channels in the bone (1). Nodal spread in chondrosarcoma is extremely rare and there are two reported cases in literature including one previously published by our institute (3, 5). **Aims and Objectives:** We present a series of chondrosarcoma cases (primary tumour located in the scapula, proximal femur, proximal humerus and pelvis), presenting with lymph node metastasis, treated at our institute. We assessed the oncological outcome of these cases and the impact of nodal metastasis on survival. **Materials and Methods:** Between January 2006 and December 2015, 243 patients of extremity and pelvic chondrosarcoma were operated at our institute. These cases were retrieved from a prospectively maintained database. Four (1.6%) of these patients developed lymph node metastasis. Clinical and radiological details of these cases were retrieved from electronic medical records and case files. Histopathology of the primary chondrosarcoma lesion and nodal metastasis was reconfirmed by a pathologist specializing in sarcomas. **Conclusion:** Lymph node metastasis though extremely rare in primary osseous chondrosarcoma, definitely affects their survival adversely. The rarity of the occurrence of lymph node metastasis in primary osseous tumors, especially chondrosarcoma highlights the need for multi institutional studies to pool knowledge and evaluate the prognostic significance and etiopathogenesis of lymph node metastasis in primary bone chondrosarcoma.

Key words: Chondrosarcoma, lymph node, metastasis

Introduction

Bone sarcomas are heterogeneous tumors of mesenchymal origin, which are known to metastasize through the hematogenous route. Metastasis to lymph nodes is extremely rare in bone sarcomas.^[1,2] Although lymph node metastasis has been reported in cases of Ewings and osteosarcoma, mostly in extraskelatal variants, there is paucity of data on nodal metastasis in cases of chondrosarcoma of bone.^[3] Earlier, we reported a single case of lymph node metastasis from a chondrosarcoma, originating in the humerus.^[4] Herein, we present a series of four cases of chondrosarcoma of the bone with regional lymph node metastasis [Table 1]. We also looked at oncological outcomes and the impact of nodal metastasis on survival in these cases.

Materials and Methods

Between January 2006 and December 2015, 243 patients of extremity and pelvic chondrosarcoma were operated at our institute. These cases were retrieved from a prospectively maintained database. Four (1.6%) of these patients developed lymph node metastasis. Clinical and radiological details of these cases were retrieved from electronic medical records and case files. Histopathology of the primary chondrosarcoma lesion and nodal metastasis was reconfirmed by a pathologist specializing in sarcomas.

Case History

Case 1

A 49-year-old male presented with swelling over his right shoulder of 8 month's duration. Examination revealed a large, bony hard swelling arising from his right scapula. The range of movement at the shoulder was normal with no distal neurovascular deficit. There was no palpable axillary lymphadenopathy.

The radiograph showed a lytic lesion arising from the scapula with stippled calcification suggestive of a chondroid neoplasm. Magnetic resonance imaging (MRI) revealed a primary bone

tumor of the right scapula involving the glenoid, scapular neck, and coracoid process. The tumor was hyperintense on T2-weighted (T2W) images with lobulated appearance suggestive of chondroid pathology, with a separate nodal mass located posterior to the primary lesion [Figure 1a and b]. After confirming a diagnosis of chondrosarcoma, the patient underwent wide excision with total scapulectomy and axillary lymph node dissection. The final histopathology revealed Grade II chondrosarcoma with two of the dissected nodes showing metastatic tumor deposits without perinodal extension. Fifteen months after the index surgery, the patient presented with a local recurrence [Figure 1c] and was treated with wide excision. The histopathological examination showed recurrence of Grade II chondrosarcoma. The patient is currently on follow-up and free of disease for the past 20 months.

Case 2

A 63-year-old male presented with pain and swelling over his left inguinal region since 2-year duration. Examination revealed a 10 cm × 6 cm sized bony hard mass, arising from the superior pubic ramus with associated painful terminal restriction of his left hip range of movements. There was no palpable lymphadenopathy.

Radiographs revealed a mixed sclerotic-lytic lesion with stippled "rings" and "arcs" calcification, involving his left iliac bone, suggestive of chondrosarcoma [Figure 2a]. MRI of the pelvis revealed a large lobulated lesion involving the left acetabulum, left anterior column, left pubic bone, with a soft tissue mass causing displacement of the neurovascular bundle. The lesion was hypointense to intermediate signal intensity on T1-weighted (T1W) images and was heterogeneously hyperintense on T2W and short-tau inversion recovery images (STIR). Core-needle biopsy from the lesion showed features of a Grade II chondrosarcoma and had no distant metastasis.

This is an open access journal, and articles are distributed under the terms of the Creative Commons Attribution-NonCommercial-ShareAlike 4.0 License, which allows others to remix, tweak, and build upon the work non-commercially, as long as appropriate credit is given and the new creations are licensed under the identical terms.

For reprints contact: reprints@medknow.com

How to cite this article: Kurisunkal V, Gulia A, Puri A, Rekhi B. Lymph node metastasis in extremity chondrosarcomas: A series of four cases. South Asian J Cancer 2020;9:1-3.

Access this article online

Quick Response Code:



Website: www.sajc.org

DOI: 10.4103/sajc.sajc_84_19

Bone and Soft Tissue Services, Department of Surgical Oncology, Tata Memorial Hospital, HBNI, Mumbai, Maharashtra, India

Correspondence to: Dr. Ashish Gulia,
E-mail: aashishgulia@gmail.com

The patient underwent left Type I + II + III internal hemipelvectomy with hip transposition [Figure 2b]. Intraoperatively, few enlarged lymph nodes were observed along the external iliac vessels. These were dissected and sent for histopathological evaluation. The patient developed subsequent wound healing problems because of which postoperative radiotherapy was deferred. Final histopathology revealed features of Grade III chondrosarcoma with a positive surgical margin. All lymph nodes showed metastasis from chondrosarcoma with perinodal extension [Figure 2c]. The patient developed both local and distant pulmonary recurrence at 6 months from index surgery and subsequently died due to disease 14 months after diagnosis of recurrence.

Case 3

A 31-year-old female presented with a biopsy-proven locally recurrent Grade II chondrosarcoma of the right proximal femur [Figure 3a]. She had undergone curettage at another hospital. After staging evaluation (no distant metastasis), she was treated with wide excision and proximal femoral replacement at our institute [Figure 3b]. The final histopathological examination of the resected specimen showed features of Grade II chondrosarcoma with negative resection margins. Two years later, she developed multiple local recurrences, in the form of 4 cm × 3 cm sized hard and fixed lesions over outer aspect of her lower thigh and also in ipsilateral inguinal region [Figure 3e]. MRI revealed a lobulated mass, which was T2W hyperintense and T1W hypointense measuring 15 cm × 6.4 cm × 5.4 cm, in the soft tissues adjacent to the femoral metallic implant, encasing the vessels and sciatic nerve. Computed tomography (CT) pelvis and abdomen revealed 3.7 cm × 3.6 cm sized cystic lesion in her right iliac fossa, adjacent to the external iliac vessels suggestive of enlarged lymph nodes [Figure 3d]. Fine-needle aspiration cytology from the inguinal node was suggestive of metastasis from chondrosarcoma. The final histopathological examination after hip disarticulation with a groin node dissection revealed recurrence of Grade II chondrosarcoma with lymph node metastasis to external iliac lymph nodes [Figure 3c]. Two years later, she presented with a metastatic lesion in the lateral mass of atlas vertebrae, causing compression of the left vertebral artery and displacing the carotid vessels anteriorly [Figure 3f]. A CT-guided biopsy was performed which showed a recurrence of chondrosarcoma. In view of the location of recurrence, the patient was treated with definitive radiotherapy (35 Gy/5# for 1 week). Currently, she is asymptomatic and is on regular follow-up of 18 month's, post radiation.

Case 4 (prior published)

A 38-year-old male presented with ill-defined, permeative lytic lesion in the proximal humeral metadiaphysis, extending into the humeral head with a wide zone of transition, cortical erosion, interrupted periosteal reaction, and a pathological fracture [Figure 4b]. MRI T2W images showed hyperintense lobulated mass suggestive of chondroid matrix, with encasement of neurovascular bundle, and suspicious lesion suggestive of nodal metastasis [Figure 4a and 4c]. He was diagnosed as nonmetastatic Grade II chondrosarcoma and underwent forequarter amputation and axillary lymph node clearance. The final histopathology revealed Grade II chondrosarcoma of the proximal humerus with regional lymph node metastasis (2 out of 27 resected lymph nodes) [Figure 4d and e]. He developed local and distant pulmonary recurrence 6 months from index

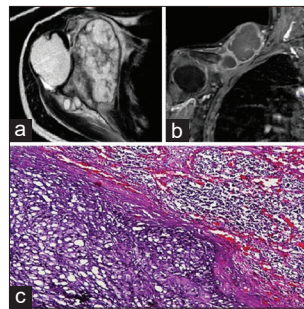


Figure 1: (a) Scapular lesion with lymph nodes, posterior to primary lesion. (b) Image showing recurrence in the supraclavicular region. (c) Intranodal deposits of chondrosarcoma, arrow heads within lymphoid tissue pointing toward tumor deposits (H and E, ×200)

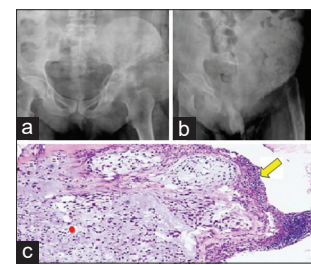


Figure 2: (a) Aggressive lesion of the left iliac bone with large soft-tissue component. (b) Postoperative radiograph after internal hemipelvectomy. (c) Intranodal deposits of chondrosarcoma. Arrow head within lymph node capsule pointing toward lymphoid tissue with tumor deposits (red dot) (H and E, ×200)

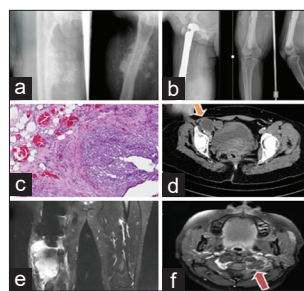


Figure 3: (a) Preoperative and postoperative, (b) radiograph of chondrosarcoma of proximal femur treated with wide excision and reconstruction with megaprosthesis, (c) histopathological slide showing intranodal deposits of chondrosarcoma. (d) Contrast-enhanced computed tomography demonstrating a 3.7 × 3.6 cm sized cystic lesion in the right iliac fossae suggestive of a necrotic node. (e) Magnetic resonance imaging (Coronal short-tau inversion recovery) images showing a soft tissue recurrence in the distal thigh. (f) Magnetic resonance imaging shows an ill-defined soft-tissue lesion replacing the left lateral mass of the atlas vertebrae

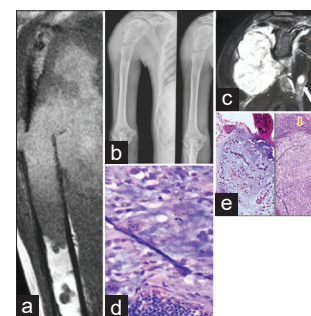


Figure 4: (a) T1-weighted coronal section with large soft-tissue mass and pathological fracture (b) Anterior-posterior view showing aggressive lesion in the right proximal humerus and pathological fracture (c) Postgadolinium fat suppressed T1-weighted images showing primary lesion and nodal metastasis (White arrow). (d) Magnification showing moderate nuclear atypia within tumor cells. H and E, ×400 (e) primary tumor showing permeation into host bone deposits H and E, ×200 intranodal deposits of chondrosarcoma, arrow heads in the lymphoid tissue point toward tumor

surgery and was treated with pulmonary metastectomy and excision of the soft-tissue recurrence. He succumbed to disease 13 months after diagnosis of tumor recurrence.

Discussion

Chondrosarcoma usually metastasize through hematogenous route with the lung being the most common site for secondary deposits. Weingrad and Rosenberg^[3] found no metastasis in regional lymph nodes in amputation specimens of 34 patients with chondrosarcoma. Of 243 patients operated at our institute, four patients developed nodal metastasis. The paucity of lymphatic channels in bone tissue is possibly the reason for nodal metastasis to be a rare occurrence in bone tumors. Edwards *et al.*^[1,2] reported that lymphatic vessels were lacking in normal bones. However, lymphatics are present in the connective tissues overlying the periosteum. Therefore, he postulated that lymphatic spread of the tumors could only occur when tumors extend through the periosteum into the adjacent connective tissues, as

Table 1: Cases tabular depiction

	Case 1	Case 2	Case 3	Case 4
Sex	Male	Male	Female	Male
Age	49	53	32	36
Site	Scapula	Pelvis	Proximal femur	Proximal humerus
Site of nodal metastasis	Axillary	External iliac	External iliac	Axillary
Mode of detection of nodal metastasis	MRI	Intra operative	Clinical examination	MRI
Histologic grade	II	III	II	II
Presentation	Primary	Primary	Recurrent	Primary
Prior surgery	No	No	Yes	No
Staging	No other sites of metastasis	No other site of metastasis	No other site of metastasis	No other site of metastasis
Surgical margins	Free	Involved	Free	Free
Adjuvant treatment	Nil	Nil	Nil	Nil
Subsequent other metastasis	LR	LR + DR	DR	LR+DR
Follow up (months)	20	17	43	9
Current status	Free of disease	Dead of disease	Alive with disease	Dead of disease
Skin involvement	No	No	No	No
Pathological fracture	No	No	No	Yes

MRI=Magnetic resonance imaging, LR=Local recurrence, DR=Distant recurrence

observed in all four cases of the present study. In addition, one patient had a displaced pathological fracture at presentation, and another patient developed a recurrent chondrosarcoma after an inappropriate curettage. Matsumoto *et al.*^[5] reported a case of parosteal chondrosarcoma of humerus, who developed regional lymph node metastasis following several inadequate resections over a period of 32 years. In the present study, the development of regional lymph node metastasis could be attributed to multiple interventions over a prolonged period. Intraoperative contamination of the surrounding soft tissues with subsequent recurrence could also be a factor in the development of lymph node metastasis in these patients.

Two patients developed local and distant recurrences. Both these patients died of disease. One patient with only local recurrence, who underwent a revision surgery, is currently free of disease and on regular follow-up. One of our patients developed a rather uncommon distant metastasis in the lateral process of the atlas vertebrae, treated with external beam radiotherapy, is currently alive with a controlled disease and is on regular follow-up. Patient with nodal metastasis represents biologically aggressive disease, rendering such patients with higher chances of local and distant recurrence. A number of studies have shown that the prognosis of patients with isolated regional nodal metastasis is better than patients with distant pulmonary, bony or visceral metastasis, therefore have been classified as Stage III,^[6-8] however according to the American Joint Committee on Cancer 8th edition^[9] the presence of regional lymph node metastasis in bone sarcomas is generally considered a poor prognostic factor hence reclassified as stage IV B. Whether the outcomes in bone sarcomas with isolated regional nodal metastasis are different compared to metastasis at other sites remains debatable. In our own unpublished data, 5-year overall survival for nonmetastatic chondrosarcoma ($n = 212$) was 77%, chondrosarcoma with pulmonary metastasis at presentation ($n = 15$) was 44% and that for isolated nodal metastasis ($n = 4$) was 33%. In view of the limited number of cases, it would be inappropriate to conclude that patient with nodal metastasis fare worse than those with pulmonary metastasis. However, lymph node metastasis though extremely rare in primary osseous

South Asian Journal of Cancer ♦ Volume 9 ♦ Issue 1 ♦ January-March 2020

chondrosarcoma definitely affects their survival adversely. The rarity of the occurrence of lymph node metastasis in primary osseous tumors, especially chondrosarcoma highlights the need for multi-institutional studies to pool knowledge and evaluate the prognostic significance and etiopathogenesis of lymph node metastasis in primary bone chondrosarcoma.

Declaration of patient consent

The authors certify that they have obtained all appropriate patient consent forms. In the form the patient(s) has/have given his/her/their consent for his/her/their images and other clinical information to be reported in the journal. The patients understand that their names and initials will not be published and due efforts will be made to conceal their identity, but anonymity cannot be guaranteed.

Financial support and sponsorship

Nil.

Conflicts of interest

There are no conflicts of interest.

References

1. Wong SY, Hynes RO. Lymphatic or hematogenous dissemination: How does a metastatic tumor cell decide? *Cell Cycle* 2006;5:812-7.
2. Edwards JR, Williams K, Kindblom LG, Meis-Kindblom JM, Hogendoorn PC, Hughes D, *et al.* Lymphatics and bone. *Hum Pathol* 2008;39:49-55.
3. Weingrad DN, Rosenberg SA. Early lymphatic spread of osteogenic and soft-tissue sarcomas. *Surgery* 1978;84:231-40.
4. Gulia A, Puri A, Jain S, Dhanda S, Gujral S. Chondrosarcoma of the bone with nodal metastasis: The first case report with review of literature. *Indian J Med Sci* 2011;65:360-4.
5. Matsumoto K, Hukuda S, Ishizawa M, Saruhashi Y, Okabe H, Asano Y. Parosteal (juxtacortical) chondrosarcoma of the humerus associated with regional lymph node metastasis. A case report. *Clin Orthop Relat Res* 1993; 290:168-73.
6. Edge SB, editor. *Soft tissue sarcoma*. In: *AJCC Cancer Staging Handbook*. 7th ed. New York: Springer; 2010. p. 345-55.
7. Riad S, Griffin AM, Liberman B, Blackstein ME, Catton CN, Kandel RA, *et al.* Lymph node metastasis in soft tissue sarcoma in an extremity. *Clin Orthop Relat Res* 2004;426:129-34.
8. Al-Refaie WB, Andtbacka RH, Ensor J, Pisters PW, Ellis TL, Shrout A, *et al.* Lymphadenectomy for isolated lymph node metastasis from extremity soft-tissue sarcomas. *Cancer* 2008;112:1821-6.
9. Amin MB, Edge S, Greene F, Byrd DR, Brookland RK, Washington MK, *et al.* editors. *AJCC Cancer Staging Manual*. 8th ed., Vol. 38. Springer International Publishing: American Joint Commission on Cancer; 2017. Available from: <http://www.springer.com/us/book/9783319406176#aboutBook>. [Last cited 2016 Dec 28].