

Case Report

^{177}Lu -DOTATATE and ^{177}Lu -prostate-specific membrane antigen therapy in a patient with advanced metastatic radioiodine-refractory differentiated thyroid cancer after failure of tyrosine kinase inhibitors treatment

ABSTRACT

Patients with radioiodine-refractory differentiated thyroid cancer (RrDTC) have only a limited or no benefit from radioiodine therapy. For these patients, tyrosine kinase inhibitors have demonstrated encouraging results in advanced RrDTC. Nevertheless, these therapies are related with substantial side effects and a high cost. Somatostatin receptor-based therapies have shown promising findings in advanced RrDTC. Recently, prostate-specific membrane antigen (PSMA) expression was seen in advanced RrDTC in imaging studies. This study presents a case of RrDTC who was treated with ^{177}Lu -DOTATATE and ^{177}Lu -PSMA, presumably as a first report in this regard.

Keywords: ^{177}Lu , DOTATATE, prostate-specific membrane antigen, radioiodine-refractory differentiated thyroid cancer

INTRODUCTION

Patients with radioiodine-refractory differentiated thyroid cancer (RrDTC) have only a limited or no benefit from radioiodine therapy so that they need other treatment strategies such as surgery and/or external irradiation to provide a systemic approach to prevent metastatic tumor spread. Tyrosine kinase inhibitors have demonstrated encouraging results in advanced RrDTC but is associated with substantial side effects and a high cost. Somatostatin receptor (SSTR)-based therapies have shown promising findings in advanced RrDTC.^[1,2] Recently, prostate-specific membrane antigen (PSMA) expression was seen in advanced RrDTC in imaging studies.^[3]

This study presents a case of RrDTC who was treated with ^{177}Lu -DOTATATE and ^{177}Lu -PSMA, and is presumably the first report in this regard.

CASE REPORT

The patient was a 42-year-old man who had a progressive disease with neck and lung metastases and was treated with 25.9 GBq (700 mCi) ^{131}I and also sorafenib for 6 months. The patient had progressive dyspnea due to massive pleural effusions and also repeated surgical intervention in thorax [Figure 1a]. The last radioiodine therapy with 7.4 GBq was given after a long period sorafenib treatment, which was associated with the patient experiencing severe side effects. The

MAJID ASSADI, HOJJAT AHMADZADEHFAR¹

The Persian Gulf Nuclear Medicine Research Center, Bushehr Medical University Hospital, Bushehr University of Medical Sciences, Bushehr, Iran, ¹Department of Nuclear Medicine, University Hospital Bonn, Bonn, Germany


Address for correspondence: Prof. Majid Assadi, The Persian Gulf Nuclear Medicine Research Center, Bushehr University of Medical Sciences, Bushehr 3631, Iran. E-mail: asadi@bpums.ac.ir, assadipoya@yahoo.com

Submission: 11-12-2018 **Accepted:** 21-12-2018 **Published:** 18-12-2019

This is an open access journal, and articles are distributed under the terms of the Creative Commons Attribution-NonCommercial-ShareAlike 4.0 License, which allows others to remix, tweak, and build upon the work non-commercially, as long as appropriate credit is given and the new creations are licensed under the identical terms.

For reprints contact: reprints@medknow.com

How to cite this article: Assadi M, Ahmadzadehfar H. ^{177}Lu -DOTATATE and ^{177}Lu -prostate-specific membrane antigen therapy in a patient with advanced metastatic radioiodine-refractory differentiated thyroid cancer after failure of tyrosine kinase inhibitors treatment. World J Nucl Med 2019;18:406-8.

Access this article online	
Website: www.wjnm.org	Quick Response Code 
DOI: 10.4103/wjnm.WJNM_112_18	

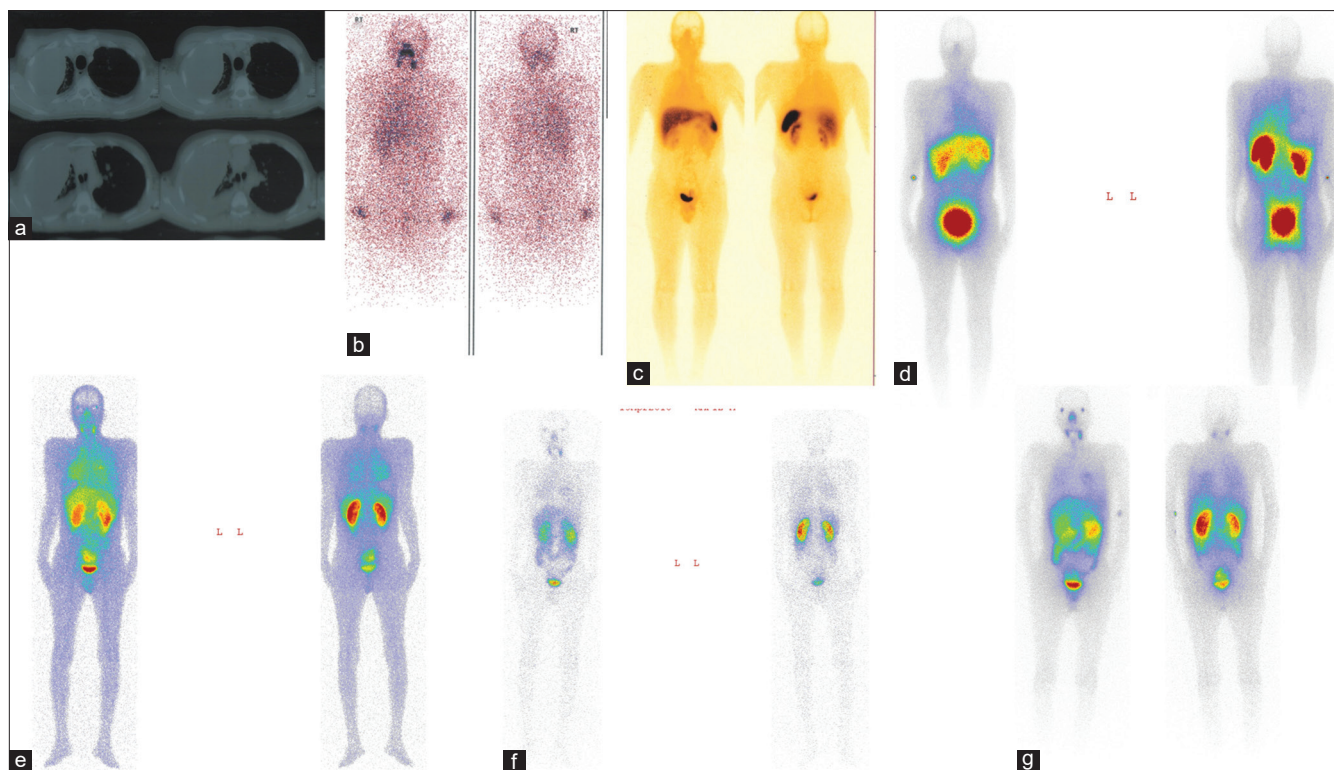


Figure 1: The different imaging modalities in a 42-year-old man with a radioiodine-refractory differentiated thyroid cancer. Computed tomography scan of thorax (a); post ^{131}I ablation whole-body scan (b); $^{99\text{m}}\text{Tc}$ octreotide scintigraphy (c); post ^{177}Lu -DOTATATE whole-body imaging (d); 2 and 24 h prostate-specific membrane antigen scintigraphy (e and f) and post ^{177}Lu -prostate-specific membrane antigen whole-body imaging (g)

posttreatment whole-body imaging showed a faint uptake in the involved neck and lung regions [Figure 1b]. Few months later he underwent octreotide scintigraphy which depicted faint uptake in the neck and lung [Figure 1c], and he immediately received 7.4 GBq ^{177}Lu -DOTATATE, and also posttherapy whole-body imaging which demonstrated some uptake in the neck and lung [Figure 1d]. The patient showed continued disease progression and severe dyspnea which required repeated hospitalization. Based on the promising findings of ^{68}Ga -PSMA,^[3,4] Our multidisciplinary team proposed PSMA scanning which showed more uptake than octreotide scan in the involved regions [Figure 1e and f]. He then received 7.4GBq ^{177}Lu -PSMA, and once more the posttherapy whole-body imaging revealed more uptake than posttherapy whole-body imaging following ^{177}Lu -DOTATATE [Figure 1g]. The patient died 2 weeks posttherapy unexpectedly due to cardiac arrest. It should be mentioned that the number of hospitalization after PRRT were fewer than before. Also, an interesting clinical point was that the respiratory function improved in the early days after therapy, so that although he could not walk alone before PRRT, he was able to walk alone for hours in the early days after PRRT.

DISCUSSION

In this study, we present both ^{177}Lu -DOTATATE and ^{177}Lu -PSMA therapies in a patient with RrDTC.

Recently, Roll *et al.* presented findings of five RrDTC patients with limited further therapeutic options and documented expression of SSRT using ^{68}Ga -DOTATATE-PET/CT received 2–4 cycles of PRRT with ^{177}Lu -DOTATATE. They demonstrated that only one out of five patients depicted a partial response, whereas three patients had a progressive disease. One patient had discordant findings between stable imaging results albeit rising Tg levels.^[2]

Overall, recent studies demonstrate heterogeneous results ranging from progressive disease under PRRT to favorable results with disease control in up to 60% of patients.^[1,5,6] To the best of our knowledge, the literature is scarce regarding ^{177}Lu -PSMA therapy in the patients with RrDTC, so further studies are needed to evaluate this subgroup of DTC.

Such cases illustrate the potential complexity, and interdisciplinary strategies that may end in managing dilemmas. It appears that there is a need for a multidisciplinary pragmatic approach for a change in the management of patients with RrDTC.

Declaration of patient consent

The authors certify that they have obtained all appropriate patient consent forms. In the form the patient(s) has/have given his/her/their consent for his/her/their images and other clinical information to be reported in the journal. The patients

understand that their names and initials will not be published and due efforts will be made to conceal their identity, but anonymity cannot be guaranteed.

Financial support and sponsorship

Nil.

Conflicts of interest

There are no conflicts of interest.

REFERENCES

1. Salavati A, Puranik A, Kulkarni HR, Budiawan H, Baum RP. Peptide receptor radionuclide therapy (PRRT) of medullary and nonmedullary thyroid cancer using radiolabeled somatostatin analogues. *Semin Nucl Med* 2016;46:215-24.
2. Roll W, Riemann B, Schäfers M, Stegger L, Vrachimis A. ¹⁷⁷Lu-DOTATATE therapy in radioiodine-refractory differentiated thyroid cancer: A Single center experience. *Clin Nucl Med* 2018;43:e346-51.
3. Taywade SK, Damle NA, Bal C. PSMA expression in papillary thyroid carcinoma: Opening a new horizon in management of thyroid cancer? *Clin Nucl Med* 2016;41:e263-5.
4. Sager S, Vatankulu B, Uslu L, Sönmezoglu K. Incidental detection of follicular thyroid carcinoma in ⁶⁸Ga-PSMA PET/CT imaging. *J Nucl Med Technol* 2016;44:199-200.
5. Budiawan H, Salavati A, Kulkarni HR, Baum RP. Peptide receptor radionuclide therapy of treatment-refractory metastatic thyroid cancer using ⁹⁰Yttrium and ¹⁷⁷Lutetium labeled somatostatin analogs: Toxicity, response and survival analysis. *Am J Nucl Med Mol Imaging* 2013;4:39-52.
6. Versari A, Sollini M, Frasoldati A, Fraternali A, Filice A, Froio A, *et al.* Differentiated thyroid cancer: A new perspective with radiolabeled somatostatin analogues for imaging and treatment of patients. *Thyroid* 2014;24:715-26.