

Case Report

Unusual presentation of a curve-shaped Meckel's diverticulum detected on technetium-99m Meckel's scintigraphy

ABSTRACT

Complicated Meckel's diverticulum (MD) in pediatric age group may not present with classic symptoms or signs. The routine modalities of investigations for the detection of MD are ultrasonography (US), computerized tomography, and air enema. However, these may miss the diagnosis in cases of atypical patterns of presentation. In such situations, the radionuclide Meckel scan helps to narrow down the diagnosis. The objective of this case report was to present an unusual presentation of MD where the diagnosis was established by a radionuclide scan against other methods which were equivocal. An 8-year-old boy was admitted with features of intestinal obstruction. ^{99m}Tc-pertechnetate Meckel's scintigraphy showed localization of tracer in ectopic gastric mucosa. The surgical exploration after the Meckel's scan revealed a curve-shaped MD localized 50 cm proximal to the ileocecal valve. The surgery was completed after a diverticulectomy, and the patient was relieved of symptoms. MD scintigraphy can help detect ectopic gastric mucosa in cases of unusual presentation by considering the atypical presentation, variation in shape, and location on Meckel's scan and improve the disease management.

Keywords: Gastric mucosa, meckel's diverticulum, radionuclide Meckel's scan

INTRODUCTION

Meckel's diverticulum (MD), a true diverticulum of the distal ileum containing all the three layers of the gut, is a frequently observed gastrointestinal malformation caused from inadequate obliteration of the omphalomesenteric (vitelline) duct around 5 weeks of intrauterine period. The vitelline duct supplied by vitelline artery contains pluripotent cells; hence, the MD often presents with heterotopic tissue like gastric mucosa followed by pancreatic mucosa and rarely colonic and gastric mucosa.^[1] The type and amount of the heterotopic tissue explains the pathological reason causing complications such as hemorrhage, perforation, intestinal obstruction, and others.^[2] Symptomatic MD usually follows the "rule of 2s" presenting within 2 years of age occurring in 2% of the population, located within 2 feet proximal to the ileocecal valve measuring 2 inches in diameter. Asymptomatic MD presents with the complications associated with it. The

risk of such manifestations is reported to be 25%–33%.^[3,4] The wide range of symptoms and the associated morbidity necessitates high degree of suspicion in detecting MD. The choice of treatment is surgery which usually is segmental resection of MD along with the adjoining normal ileum as it may also contain ectopic mucosa.^[5] MD scintigraphy is a common and more accurate modality employed in the diagnosis of MD. The other usual investigations that

DHARMALINGAM ANITHA, PAWAR SHWETAL U, SHETYE SURUCHI S, GHORPADE MANGALA K

Department of Nuclear Medicine Surgery, Seth G.S Medical College and KEM Hospital, Parel, Mumbai, India


Address for correspondence: Dr. Pawar Shwetal U, Department of Nuclear Medicine, Seth G.S Medical College and KEM Hospital, Parel, Mumbai, India.
E-mail: shwetal13@yahoo.com

Submitted: 26-Mar-2019, **Accepted:** 29-Jun-2019, **Published:** 14-Jan-2020

This is an open access journal, and articles are distributed under the terms of the Creative Commons Attribution-NonCommercial-ShareAlike 4.0 License, which allows others to remix, tweak, and build upon the work non-commercially, as long as appropriate credit is given and the new creations are licensed under the identical terms.

For reprints contact: reprints@medknow.com

How to cite this article: Anitha D, Shwetal PU, Suruchi SS, Mangala GK. Unusual presentation of a curve-shaped Meckel's diverticulum detected on technetium-99m Meckel's scintigraphy. World J Nucl Med 2020;19:52-5.

Access this article online	
Website: www.wjnm.org	Quick Response Code 
DOI: 10.4103/wjnm.WJNM_27_19	

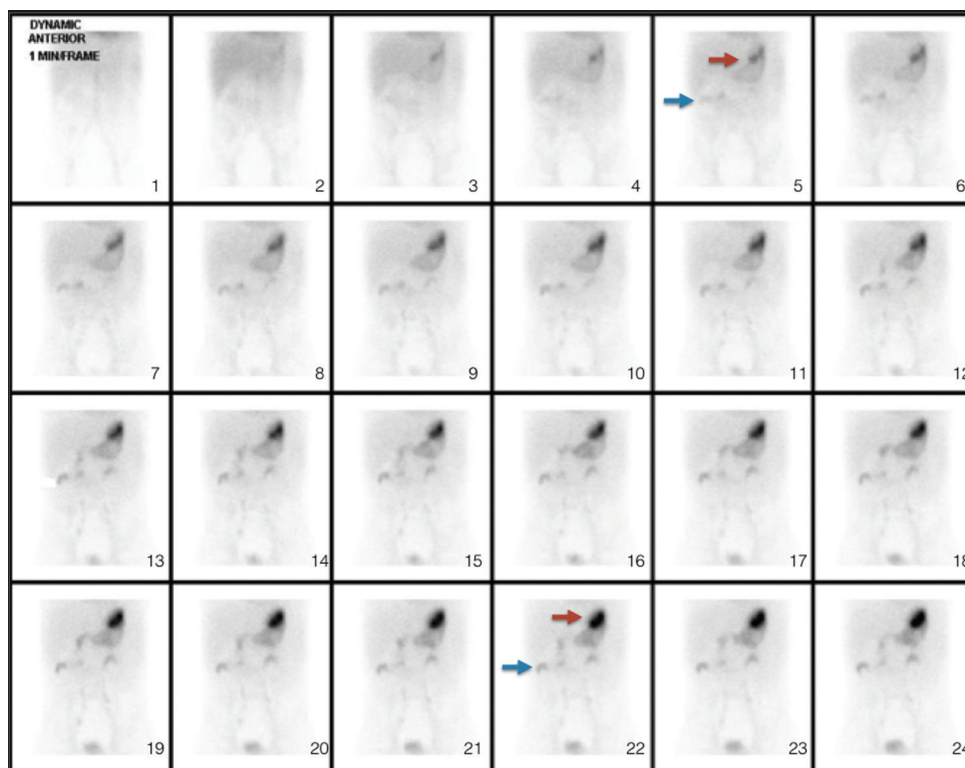


Figure 1: Tc-99m Radionuclide Meckel's scan demonstrating abnormal tracer accumulation in the right upper quadrant of the abdomen and its simultaneous visualisation with the gastric radiotracer activity

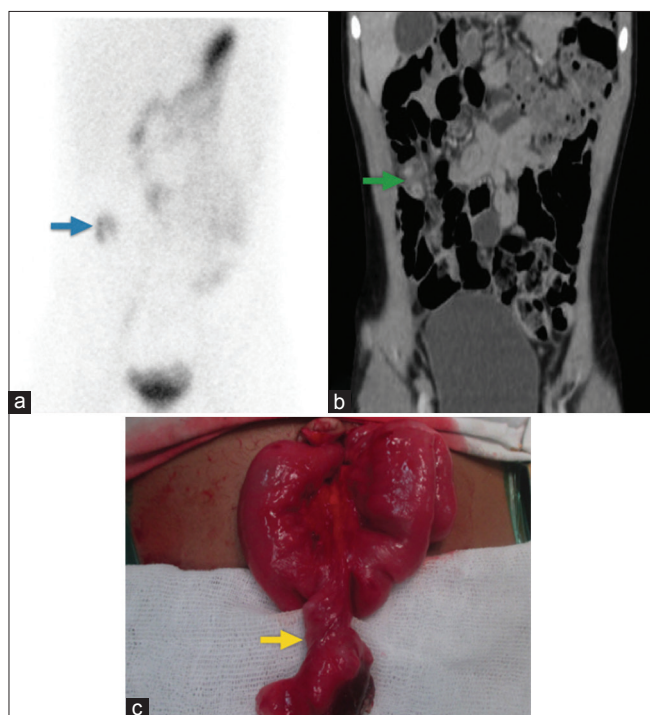


Figure 2: Intra-operative visualisation of the diverticulum and gangrenous perforation of the diverticulum with impending obstructive symptoms. Blue arrow indicates the visualization of gastric mucosa in MD on a Meckel's scan ; green arrow indicates the CT observation of MD; yellow arrow indicates the post-operative specimen of MD with the distal gangrenous perforation

can help identifying MD include abdominal ultrasound, computerized tomography (CT), and in some cases angiography. This report presents an atypical clinical and imaging presentation of MD, where Meckel's scan guided in clinching the diagnosis.

CASE REPORT

An 8-year-old boy presented with pain and distension of abdomen for 1 week. There were intermittent episodes of vomiting with no fever. He was able to pass flatus intermittently but was unable to pass stools. The abdominal radiographs showed air and fluid levels. The clinical diagnosis of intestinal obstruction was made. The ultrasound of abdomen and pelvis raised suspicion of intussusception with free fluid. The CT scan also raised suspicion of small bowel obstruction due to features of dilated proximal bowel loops. The suspicion of intussusception versus MD was suspected.

The Meckel's scan was advised in this case of unusual presentation of intestinal obstruction with equivocal findings on ultrasound and CT scan to rule out possibility of MD.

15 mCi (555MBq) of Tc-99m pertechnetate was injected intravenously, and dynamic images of abdomen and pelvis

were acquired for 30 min in anterior and posterior projections on dual-head GE Infinia gamma camera.^[6] The later static images at 30 min and 1 h and single photon emission CT/CT images were acquired. There was a localized focal tracer concentration to right hypochondriac region that was seen to be curved like a bowel loop, synchronized with the appearance of gastric mucosal activity of Tc-99m pertechnetate. The activity did not show antegrade movement till delayed images. The diagnosis of MD containing ectopic gastric mucosa was made considering the constant activity of technetium-99m pertechnetate in the right upper quadrant of the abdomen and its simultaneous visualization with the gastric radiotracer activity [Figure 1].

The patient was operated, and the diagnosis was confirmed by the intraoperative visualization of the diverticulum and histopathological examination of the specimen. There was gangrenous perforation of the diverticulum with impending obstructive symptoms. The postoperative course was uneventful [Figure 2].

DISCUSSION

The majority of symptomatic Meckel's diverticula are lined by an ectopic mucosa, including an acid-secreting mucosa. Unlike the upper duodenal mucosa, the acid is not neutralized by pancreatic bicarbonate. When the adjacent normal ileal mucosa undergoes ulceration that causes intermittent painless rectal bleeding, Menezes *et al.* and Chen *et al.* had reported the incidence of hemorrhage as 55.5% and 39%, respectively.^[7,8] An Indian series by Mittal *et al.* had observed intestinal hemorrhage in 71.42% cases.^[9]

Less often, a MD is associated with partial or complete bowel obstruction. The most common mechanism of obstruction occurs when the diverticulum acts as the lead point of an intussusception. The mean age of onset of obstruction is less than that for patients presenting with bleeding.^[10] Obstruction and intussusception together account for about 32 percent of MD disease. According to Oldham and Wesley,^[11] 5%–10% of patients with symptomatic diverticular disease present with the clinical picture of intussusception. Obstruction can also result from intraperitoneal bands connecting residual omphalomesenteric duct remnants to the ileum and umbilicus. These bands cause obstruction by internal herniation or volvulus of the small bowel around the band.^[12]

Among the various methods of detection including abdominal ultrasound, superior mesenteric angiography, abdominal CT scan, and exploratory laparoscopy, MD scintigraphy performed with Tc-99m pertechnetate is less invasive and

more sensitive. When MD scintigraphy is enhanced with various agents, including cimetidine, glucagon, and gastrin,^[13] it has a sensitivity of 85%, specificity of 95%, and accuracy of 90% in detecting ectopic gastric mucosa.^[14]

Atypical presentation of MD in imaging poses a challenge in diagnosis. The routine diagnostic criteria suggested by SNMMI Society of Nuclear Medicine and Molecular Imaging and EANM European Association of Nuclear Medicine to interpret a positive scan of MD include an abnormal focal (usually rounded shape) dense radioactive lesion in or gradually increasing tracer concentration in the right lower quadrant synchronized with the appearance and gradual increase in the gastric activity.^[1,6] Although the aforementioned criteria identify the typical cases, the chance of missing an atypical presentation stands high.

In this patient, we identified an unusual curve-shaped MD in an atypical location in the right upper quadrant region on Tc-99m Meckel's scintigraphy. There was no movement of the MD in subsequent images of Meckel's scan due to perforation and adhesions. In a study conducted by Wu *et al.* in 93 patients, 10.8% were found to have atypical MD in the right upper quadrant.^[13] The morphological characteristics of a MD determine the location and shape of a lesion in the scintigraphic image. In case of a long diverticula, the ectopic gastric mucosa grew at its distal end, whereas in a short diverticula, it can be present anywhere.^[15] The varied location of MD is attributed to the interference and displacement of the small intestine.^[14,16] The shape of the lesion on a pertechnetate scan is related to the distribution of the functioning ectopic gastric mucosa in the diverticulum.^[15] Thus, careful interpretation of Meckel's scan requires the consideration of simultaneous appearance of activity with gastric mucosa and persistence of activity till delayed images. The clinical presentation, shape, and location may vary.

CONCLUSION

The interpretation of MD necessitates careful consideration of the diverse atypical characteristics which vary according to the anatomical and histopathological presentations. Thereby, false-negative studies can be avoided by considering the atypical presentation, variation in shape, and location on Meckel's scan.

Declaration of patient consent

The authors certify that they have obtained all appropriate patient consent forms. In the form the patient(s) has/have

given his/her/their consent for his/her/their images and other clinical information to be reported in the journal. The patients understand that their names and initials will not be published and due efforts will be made to conceal their identity, but anonymity cannot be guaranteed.

Financial support and sponsorship

Nil.

Conflicts of interest

There are no conflicts of interest.

REFERENCES

1. Whang EE, Ashely SW, Zinner MJ. Schwartz's Principles of Surgery. 8th ed. New York: McGraw-Hill; 2005. p. 1043-4.
2. McKenzie S, Krantz SB. Sabiston Textbook of Surgery. 20th ed. Philadelphia: Elsevier; 2012. p. 1268-70.
3. Prall RT, Bannon MP, Bharucha AE. Meckel's diverticulum causing intestinal obstruction. *Am J Gastroenterol* 2001;96:3426-7.
4. Heldans F, Neff G. Das maxkelsche divertikel ergebn. *Chir Orthop* 1937;30:227.
5. Jewett TC Jr., Duszynski DO, Allen JE. The visualization of Meckel's diverticulum with 99mTc-pertechnetate. *Surgery* 1970;68:567-70.
6. Spottswood SE, Pfluger T, Bartold SP, Brandon D, Burchell N, Delbeke D, *et al.* SNMMI and EANM practice guideline for Meckel diverticulum scintigraphy 2.0. *J Nucl Med Technol* 2014;42:163-9.
7. Menezes M, Tareen F, Saeed A, Khan N, Puri P. Symptomatic meckel's diverticulum in children: A 16-year review. *Pediatr Surg Int* 2008;24:575-7.
8. Chen JJ, Lee HC, Yeung CY, Chan WT, Jiang CB, Sheu JC, *et al.* Meckel's diverticulum: Factors associated with clinical manifestations. *ISRN Gastroenterol* 2014;2014:390869.
9. Mittal BR, Kashyap R, Bhattacharya A, Singh B, Radotra BD, Narasimha Rao KL, *et al.* Meckel's diverticulum in infants and children; technetium-99m pertechnetate scintigraphy and clinical findings. *Hell J Nucl Med* 2008;11:26-9.
10. Blevrakis E, Partalis N, Seremeti C, Sakellaris G. Meckel's diverticulum in paediatric practice on Crete (Greece): A 10-year review. *Afr J Paediatr Surg* 2011;8:279-82.
11. Jay GD 3rd, Margulis RR, McGraw AB, Northrip RR. Meckel's diverticulum; a survey of one hundred and three cases. *Arch Surg* 1950;61:158-69.
12. Oldham KT, Wesley JR. The pediatric abdomen. In: Greenfield LJ, editor. *Surgery: Scientific Principles and Practice*. Philadelphia: JB Lippincott; 1993. p. 1832-82.
13. Wu H, Zhao X, Li Y, Zhao R. Reconsideration of the primary and secondary diagnostic criteria of Meckel's diverticulum scintigraphy. A study of 93 confirmed cases. *Hell J Nucl Med* 2017;20:11-6.
14. Al Janabi M, Samuel M, Kahlenberg A, Kumar S, Al-Janabi M. Symptomatic paediatric Meckel's diverticulum: Stratified diagnostic indicators and accuracy of Meckel's scan. *Nucl Med Commun* 2014;35:1162-6.
15. Vourlioti P. Scintiscan with sodium hypertechnetate in the diagnosis of Meckel's diverticulum. *Hell J Nucl Med* 2001;2:66-70.
16. Mukai M, Takamatsu H, Noguchi H, Fukushige T, Tahara H, Kaji T, *et al.* Does the external appearance of a Meckel's diverticulum assist in choice of the laparoscopic procedure? *Pediatr Surg Int* 2002;18:231-3.