

Case Report

Acute urinary obstruction during ^{99m}Tc -ethylenedicycysteine diuretic renal scintigraphy acquisition: Is furosemide the culprit?

ABSTRACT

^{99m}Tc -ethylenedicycysteine (^{99m}Tc -EC) diuretic renal scintigraphy is an established, safe, and noninvasive study to evaluate relative renal function and drainage. We present a known case of bilateral renal stone disease who presented with acute urinary obstruction detected intraprocedurally on ^{99m}Tc -EC diuretic renography. He was managed subsequently with emergency double J stenting. The development of acute obstruction intraprocedurally in this patient may be resultant of forced diuresis caused by furosemide, dislodging the renal stones in the distal ureters. In the setting of renal calculi, cautious use of furosemide with watchful monitoring may be needed to see for the development of obstruction and manage accordingly.

Keywords: ^{99m}Tc -Ethylenedicycysteine, acute urinary obstruction, diuretic, furosemide, renal scintigraphy, renal stone disease

INTRODUCTION

Diuretic renal scintigraphy is an established, safe, and effective diagnostic study in evaluating both renal function and drainage with minimal intraprocedural complications. We report a patient of renal stone disease, who developed acute urinary obstruction during the renal scintigraphy, likely owing to the forced diuresis imparted by the furosemide. Diuretic renal scintigraphy is reported to be useful in the emergency setting, and the timely intervention helped in relieving urinary retention in this patient.

CASE REPORT

A 60-year-old male presented with a history of right flank pain. On investigation, both ultrasonogram and intravenous pyelography showed left renal calculi and right midureteric calculus. The patient was referred for a diuretic renography to evaluate renal function and drainage. His renal function tests were within normal limits, and he had a normal urinary output before the study. ^{99m}Tc -ethylenedicycysteine (^{99m}Tc -EC)

diuretic renography was done after injecting 148 MBq (4 mCi) of ^{99m}Tc -EC with furosemide injection (40 mg bolus dose) 10 min after the radiotracer injection. The study showed cortical retention of tracer in both kidneys without visualization of tracer activity in ureters and urinary bladder. Uprising renograms of both kidneys indicate urinary obstruction [Figure 1]. Corroborative history of increasing flank pain and absence of urinary output was also observed in the patient pointing toward the development of an acute urinary obstruction in the patient. With suspicion of acute urinary obstruction, the patient was referred to the emergency

SHELVIN KUMAR VADI, ANISH BHATTACHARYA, ASHWANI SOOD, BHAGWANT RAI MITTAL

Departments of Nuclear Medicine, Postgraduate Institute of Medical Education and Research, Chandigarh, India


Address for correspondence: Dr. Ashwani Sood, Department of Nuclear Medicine, Postgraduate Institute of Medical Education and Research, Chandigarh - 160 012, India. E-mail: sood99@yahoo.com

Submitted: 14-Apr-2019, **Accepted:** 21-May-2019, **Published:** 14-Jan-2020

This is an open access journal, and articles are distributed under the terms of the Creative Commons Attribution-NonCommercial-ShareAlike 4.0 License, which allows others to remix, tweak, and build upon the work non-commercially, as long as appropriate credit is given and the new creations are licensed under the identical terms.

For reprints contact: reprints@medknow.com

How to cite this article: Vadi SK, Bhattacharya A, Sood A, Mittal BR. Acute urinary obstruction during ^{99m}Tc -ethylenedicycysteine diuretic renal scintigraphy acquisition: Is furosemide the culprit? World J Nucl Med 2020;19:82-4.

Access this article online	
Website: www.wjnm.org	Quick Response Code 
DOI: 10.4103/wjnm.WJNM_30_19	

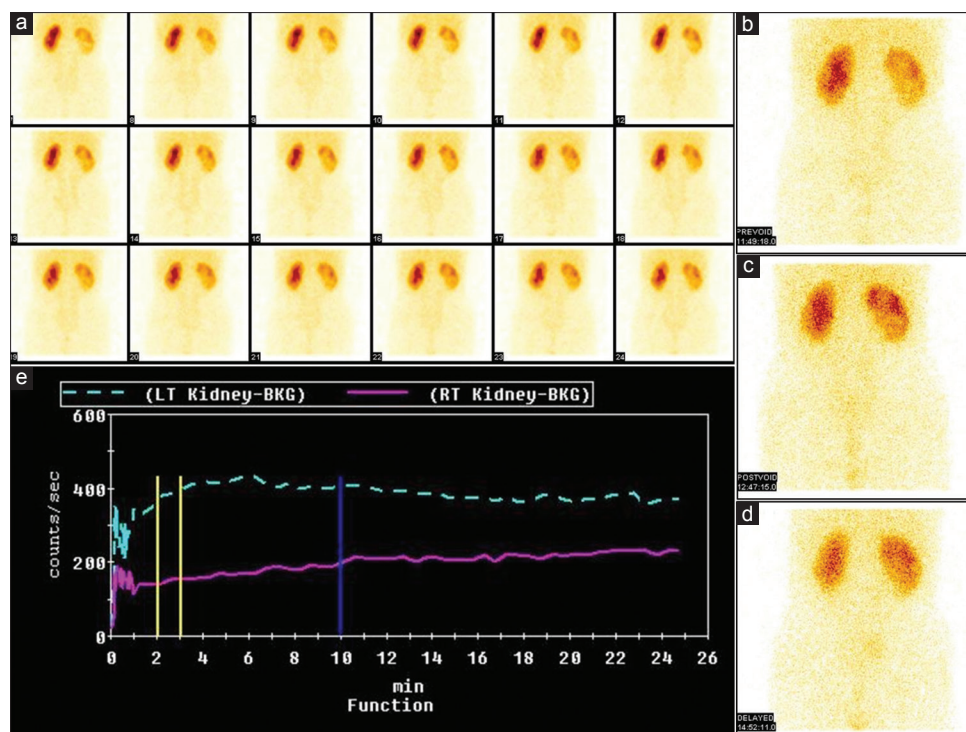


Figure 1: The initial dynamic images (a) as well as the prevoid (b) postvoid (c) and delayed (d) 3 h images of ^{99m}Tc -ethylene dicysteine diuretic renography in the patient showing no tracer clearance from both the kidneys with absence of visualization of tracer in either ureters or urinary bladder. The renogram (e) also showed an uprising curve for both kidneys

urology where after evaluating the patient's symptoms, an on-spot noncontrast computed tomography (CT) (kidneys, ureters, and bladder) was done which showed bilateral hydronephrosis and renal calculi in both distal ureters suggesting acute ureteric obstruction. An emergency double J stenting was done in both ureters, which relieved patients symptoms followed by normalization of urinary output [Figure 2]. A repeat ^{99m}Tc -EC diuretic renography done (with urinary catheter *in situ*) 4 days after the procedure showed normal cortical function and drainage from the left kidney and slow drainage from the right kidney [Figure 3] as suggested from the dynamic (a), prevoid (b), postvoid (c), delayed (d) images, and the renogram curves (e).

DISCUSSION

Diuretic renal scintigraphy is a safe, noninvasive, and effective technique in the evaluation of renal function and drainage in a single procedure.^[1] This test is based on a high endogenous rate of urine flow stimulated by the administration of furosemide. A high-grade obstruction usually manifests as acute and often presents with persistent parenchymal uptake and an empty pelvis as in this case and can rapidly leads to loss of function.^[2,3] Few pilot studies show that diuretic renal scintigraphy in the emergency room can have a substantial impact on the management of patients presenting with renal colic and a ureteral calculus documented by unenhanced

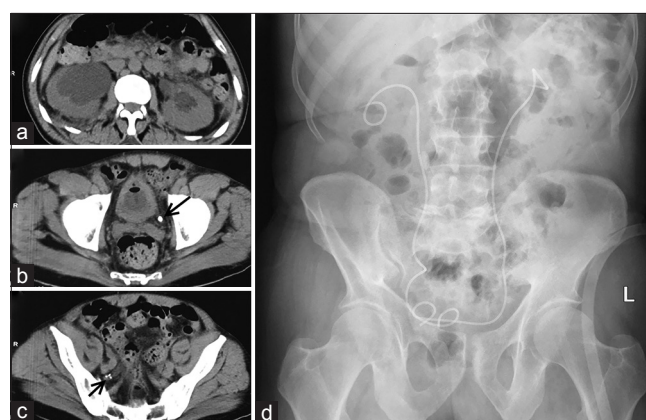


Figure 2: Emergency noncontrast computed tomography (kidneys, ureters, and bladder) showing bilateral hydronephrosis (a) and renal calculi in the both distal ureters (b and c; arrows) suggesting acute ureteric obstruction. Double J stenting was done in both ureters which can be seen in the postintervention X-ray image (d)

CT.^[4-6] Nonvisualization of the tracer activity in urinary bladder along with development of clinical symptoms and anuria points toward an acute obstruction, requiring emergency intervention" can be changed to "Non-visualization of the tracer activity in urinary bladder along with development of clinical symptoms and anuria suggest an acute obstruction, requiring emergency intervention. The sudden development of acute urinary obstruction intraprocedurally during the renal scintigraphy, as in the index case, is very unusual, and the forced diuresis imparted by furosemide injection

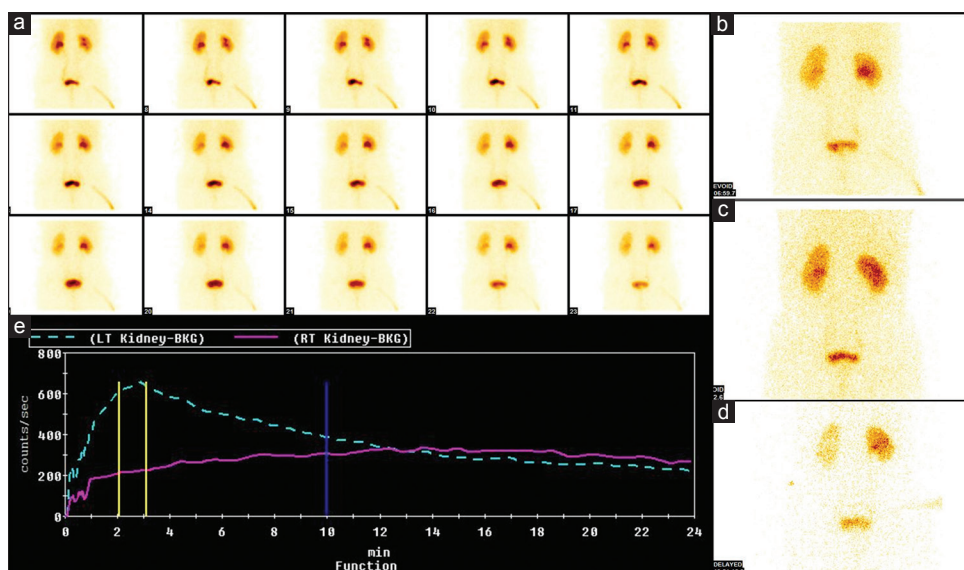


Figure 3: Repeat ^{99m}Tc -ethylene dicysteine diuretic renography done 4 days after the procedure showing normal cortical function and drainage as suggested from the dynamic (a), prevoid (b), postvoid (c), delayed (d) images and the renogram curves (e)

may be the plausible culprit, in the context of known bilateral renal stone disease. Apart from concerns regarding sulfonamide-related allergic response,^[7] furosemide at a standard dose of 0.5 mg/kg in adults is well-tolerated and safe intervention.^[8] However, in the setting of renal stone disease, the chance of development of an acute obstruction cannot be excluded, and watchful monitoring is needed intraprocedurally in these patients to look for the same.

Declaration of patient consent

The authors certify that they have obtained all appropriate patient consent forms. In the form the patient(s) has/have given his/her/their consent for his/her/their images and other clinical information to be reported in the journal. The patients understand that their names and initials will not be published and due efforts will be made to conceal their identity, but anonymity cannot be guaranteed.

Financial support and sponsorship

Nil.

Conflicts of interest

There are no conflicts of interest.

REFERENCES

1. Taylor AT, Brandon DC, de Palma D, Blaufox MD, Durand E, Erbas B, *et al.* SNMMI procedure standard/EANM practice guideline for diuretic renal scintigraphy in adults with suspected upper urinary tract obstruction 1.0. *Semin Nucl Med* 2018;48:377-90.
2. Tseng TY, Stoller ML. Obstructive uropathy. *Clin Geriatr Med* 2009;25:437-43.
3. Taylor A Jr., Lallone R. Differential renal function in unilateral renal injury: Possible effects of radiopharmaceutical choice. *J Nucl Med* 1985;26:77-80.
4. Sfakianakis GN, Cohen DJ, Braunstein RH, Leveillee RJ, Lerner I, Bird VG, *et al.* MAG3-F0 scintigraphy in decision making for emergency intervention in renal colic after helical CT positive for a urolith. *J Nucl Med* 2000;41:1813-22.
5. Sfakianaki E, Sfakianakis GN, Georgiou M, Hsiao B. Renal scintigraphy in the acute care setting. *Semin Nucl Med* 2013;43:114-28.
6. Lorberboym M, Kapustin Z, Elias S, Nikolov G, Katz R. The role of renal scintigraphy and unenhanced helical computerized tomography in patients with ureterolithiasis. *Eur J Nucl Med* 2000;27:441-6.
7. Phipatanakul W, Adkinson NF Jr. Cross-reactivity between sulfonamides and loop or thiazide diuretics: Is it a theoretical or actual risk? *Allergy Clin Immunol Int* 2000;12:26-8.
8. Wang Y, Chow DZ, Connolly LP, Scott JA, Palmer EL. Safety of administering furosemide during nuclear diuretic renography in patients with sulfonamide allergies. *AJR Am J Roentgenol* 2018;210:866-8.