

## Review article

# Systematic Review on the Accuracy of Positron Emission Tomography/Computed Tomography and Positron Emission Tomography/Magnetic Resonance Imaging in the Management of Ovarian Cancer: Is Functional Information Really Needed?

Subapriya Suppiah, Wing Liong Chang, Hasyma Abu Hassan<sup>1</sup>, Chalermrat Kaewput<sup>2</sup>, Andi Anggeriana Andi Asri<sup>3</sup>, Fathinul Fikri Ahmad Saad, Abdul Jalil Nordin<sup>1</sup>, Sobhan Vinjamuri<sup>4</sup>

Centre for Diagnostic Nuclear Imaging, Universiti Putra Malaysia, Departments of <sup>1</sup>Imaging and <sup>3</sup>Obstetrics and Gynaecology, Faculty of Medicine and Health Sciences, Universiti Putra Malaysia, Selangor, Malaysia, <sup>2</sup>Department of Radiology, Division of Nuclear Medicine, Faculty of Medicine, Siriraj Hospital, Mahidol University, Bangkok, Thailand, <sup>4</sup>Department of Nuclear Medicine, Royal Liverpool and Broadgreen University Hospitals, NHS Trusts, Liverpool, UK

## Abstract

Ovarian cancer (OC) often presents at an advanced stage with frequent relapses despite optimal treatment; thus, accurate staging and restaging are required for improving treatment outcomes and prognostication. Conventionally, staging of OC is performed using contrast-enhanced computed tomography (CT). Nevertheless, recent advances in the field of hybrid imaging have made positron emission tomography/CT (PET/CT) and PET/magnetic resonance imaging (PET/MRI) as emerging potential noninvasive imaging tools for improved management of OC. Several studies have championed the role of PET/CT for the detection of recurrence and prognostication of OC. We provide a systematic review and meta-analysis of the latest publications regarding the role of molecular imaging in the management of OC. We retrieved 57 original research articles with one article having overlap in both diagnosis and staging; 10 articles (734 patients) regarding the role of PET/CT in diagnosis of OC; 12 articles (604 patients) regarding staging of OC; 22 studies (1429 patients) for detection of recurrence; and 13 articles for prognostication and assessment of treatment response. We calculated pooled sensitivity and specificity of PET/CT performance in various aspects of imaging of OC. We also discussed the emerging role of PET/MRI in the management of OC. We aim to give the readers and objective overview on the role of molecular imaging in the management of OC.

**Keywords:** Cancer, fluorodeoxyglucose, molecular imaging, ovary

## Introduction

Ovarian cancer (OC) is a gynecological malignancy with an insidious onset and often presents at

a late stage. Once detected, accurate staging is required for optimal treatment such as primary cytoreduction or neoadjuvant chemotherapy followed by debulking surgery. Conventionally, staging of

### Address for correspondence:

Dr. Subapriya Suppiah, Centre for Diagnostic Nuclear Imaging, Universiti Putra Malaysia, Selangor, Malaysia.  
E-mail: subapriya@upm.edu.my

### Access this article online

#### Quick Response Code:



Website:  
www.wjnm.org

DOI:  
10.4103/wjnm.WJNM\_31\_17

This is an open access article distributed under the terms of the Creative Commons Attribution-NonCommercial-ShareAlike 3.0 License, which allows others to remix, tweak, and build upon the work non-commercially, as long as the author is credited and the new creations are licensed under the identical terms.

**For reprints contact:** reprints@medknow.com

**How to cite this article:** Suppiah S, Chang WL, Hassan HA, Kaewput C, Asri AA, Saad FF, *et al.* Systematic review on the accuracy of positron emission tomography/computed tomography and positron emission tomography/magnetic resonance imaging in the management of ovarian cancer: Is functional information really needed? World J Nucl Med 2017;16:176-85.

OC is performed using contrast-enhanced computed tomography (CECT).

Nevertheless, recent advances in the field of hybrid imaging as well as related publications have advocated positron emission tomography/computed tomography (PET/CT) as a potential tool for improved staging of this condition.<sup>[1,2]</sup> Furthermore, several studies have championed the role of PET/CT for the detection of recurrence and prognostication of OC.<sup>[3-6]</sup> In addition, studies have been conducted to evaluate the potential of PET/magnetic resonance imaging (PET/MRI) in the management of OCs.<sup>[7-9]</sup>

Although there is information available regarding the added benefits of hybrid functional imaging in the management of OC, there remain many questions about whether the risks outweigh the benefits and whether molecular imaging may enter as a mainstream imaging option. Therefore, we conducted a systematic review to assess the accuracy of PET/CT and PET/MRI in the management of OC for the purpose of diagnosis, staging, and detection of recurrence, as well as for the assessment of treatment response and disease prognostication.

## **Evidence Acquisition**

The most recent search for this review was performed on December 8, 2016. We searched electronic databases of SCOPUS, MEDLINE (OvidSP), and EMBASE (OvidSP), using the keywords or search terms “ovarian cancer,” “ovarian carcinoma,” “PET/CT” “PET/MRI,” and “PET/MR” and filtered it for full-text journal articles in English between the periods of January 2011 and December 2016.

### **Selection criteria**

We selected studies that had defined cohorts with any accepted definition of OC with baseline or follow-up PET/CT or PET/MRI utilizing 18F-fluorodeoxyglucose (18F-FDG) that assessed the sensitivity, specificity, and accuracy of this imaging for the diagnosis, staging, and detection of recurrence as well as assessment of treatment response. We also selected articles that highlighted the progression-free survival and overall survival for prognostication of OC patients based on PET/CT or PET/MR parameters.

All studies had to correlate the hybrid imaging findings with surgical, biopsy, cytology, or clinical findings based on the NICE Guidelines for Management of OC<sup>[10]</sup> or the American College of Obstetrics and Gynecology clinical guidelines.<sup>[11]</sup> Next, we excluded articles that were from case reports and proceedings, articles that were predominantly based on secondary metastasis to the ovaries, articles that did not involve human subjects, articles that used radiotracers other than 18F-FDG,

and articles that concentrated on other gynecological malignancies and were not focused to OC.

### **Data collection and analysis**

We screened all titles generated by electronic database searches. Two review authors independently assessed the abstracts of all potentially relevant studies. The identified full papers were assessed for eligibility and data were extracted to create two-by-two tables. Two independent assessors performed quality assessment using the QUADAS 2 tool. We grouped together studies that shared similar methodologies, for example, the use of contrast media and patient-based analysis to calculate pooled sensitivity and specificity. Studies in which the numbers of true negative, true positive, falsely positive, and falsely negative cases were not reported were excluded from pooled sensitivity and specificity calculation.

We extracted data regarding study design, whether it was prospective or retrospective or unknown. We also scrutinized patient selection, whether consecutive or not. We performed verification of bias, namely, no bias, limited, or considerable bias. No bias present was stated for articles that studied lesions on PET/CT and confirmed the diagnosis by histopathologic examination (HPE). Considerable bias was considered present for articles that did not use HPE to confirm the diagnosis or used only a small sample size. We also extracted data regarding the method used for interpretation of the test results, i.e. whether blinded or not.

## **Evidence Synthesis**

### **Data extraction**

Our initial search recovered 545 articles. After applying the exclusion criteria, we had 80 articles and added 12 more based on cross-reference from the bibliography of the recovered articles. A total of 92 articles were included in the final analysis [Figure 1]. From this figure, 57 were original scientific research articles and the remaining 35 were review articles and technical articles. There were a total of 10 research papers that investigated the role of PET/CT in diagnosis of OC, of which one article included comparison with PET/MRI. For the role of PET/CT in staging of OC, there were 12 articles plus one article which addressed both detection and staging of OC,<sup>[12]</sup> of which 3 articles included comparison with PET/MRI. Twenty-two papers addressed the topic of accuracy of PET/CT in detection of recurrence in OC patients; 13 articles referred to the role of PET/CT in assessment of treatment response and prognostication of OC.

### **Diagnosis of ovarian cancer**

A total of 10 PET/CT studies which aimed to diagnose OC were reviewed [Table 1]. These studies included

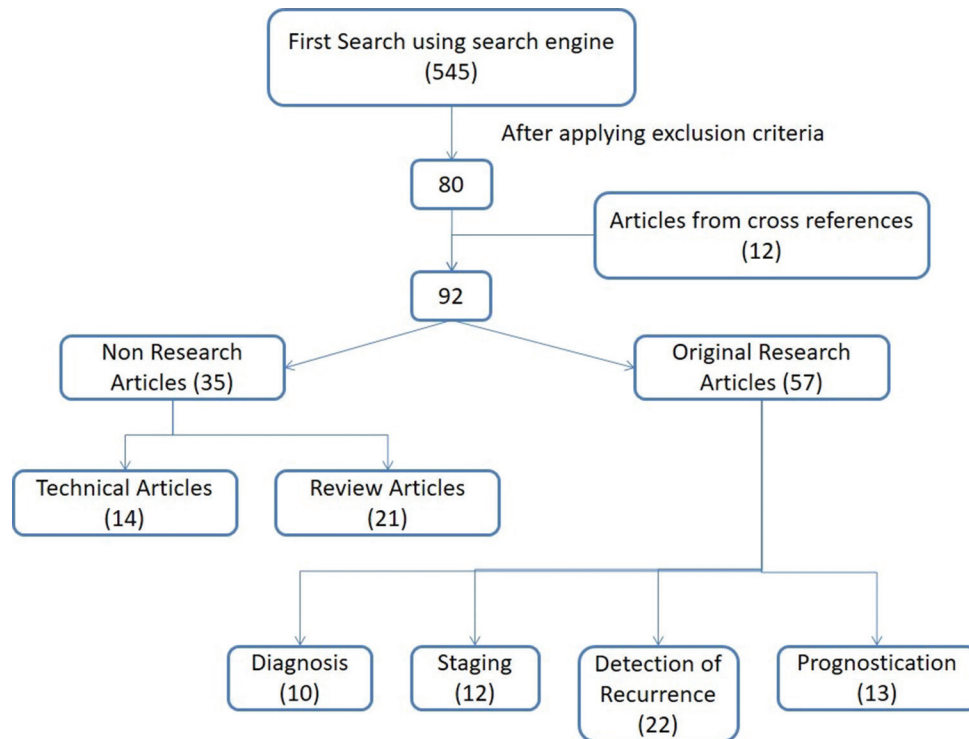


Figure 1: Flowchart of process for identifying relevant works

Table 1: Diagnosis of ovarian cancer using positron emission tomography/computed tomography

Author	Sample, n (B/M)	CT			PET/CT			Contrast media	Based analysis
		Sensitivity	Specificity	Accuracy	Sensitivity	Specificity	Accuracy		
Dauwen <i>et al.</i> (2013)	69 (13/56)	96.00	36.00	85.51	93.00	77.00	89.86	CECT, ce PET/CT	Patient
Kitajima <i>et al.</i> (2011)	108 (26/85)	-	-	-	82.40	76.90	81.80	ce PET/CT	Patient
Lee <i>et al.</i> (2014)	20 (7/13)	-	-	-	100.0	57.10	85.00	ce PET/CT	Patient
Lee <i>et al.</i> (2015)	72 (19/53)	-	-	-	98.10	78.90	91.70	ce PET/CT	Patient
Michielsen <i>et al.</i> (2014)	32 (4/28)	96.00	25.00	88.00	100.0	33.00	94.00	CECT, ce PET/CT	Patient
Tanizaki <i>et al.</i> (2014)	160 (79/81)	-	-	-	90.60	94.60	92.86	ld PET/CT	Patient
Alessi <i>et al.</i> (2016)	29 (6/23)	-	-	-	91.00	67.00	86.21	ld PET/CT	Patient

B: Benign; M: Malignant; CECT: Contrast-enhanced CT; ce PET/CT: Contrast-enhanced PET/CT; ld PET/CT: Low-dose PET/CT; PET: Positron emission tomography; CT: Computed tomography

734 cases. One of these studies had overlapping objective for both diagnosis and staging.<sup>[12]</sup> Five of these studies involved contrast-enhanced (ce) PET/CT imaging<sup>[1,12-15]</sup> whereas the rest utilized low-dose (ld) PET/CT for attenuation correction and anatomical localization. Three of these studies also incorporated MRI imaging in their study protocol. Analysis of studies that were lesion based was not included in the pooled analysis as the methodologies used were not standardized for direct comparison. Meta-analysis of these studies was not done as there was variable maximum standardized uptake value ( $SUV_{max}$ ) cut-off points cited as well as variations in the methods incorporated to diagnose OC.

Of five studies utilizing ld PET/CT, two studies did not report sensitivity and specificity results but focused on comparison of  $SUV_{max}$  cut-off values and performance differences between modalities.<sup>[9,16]</sup> The range of

sensitivity of ld PET/CT as reported in the remainder four studies was 80.6%–96.0% based on Tanizaki *et al.*<sup>[17]</sup> and Minamimoto *et al.*<sup>[18]</sup> respectively. However, the range of specificity of ld PET/CT was reported to be 67.0%–94.6% based on Alessi *et al.*<sup>[19]</sup> and Tanizaki *et al.*<sup>[17]</sup> respectively.

For PET/CT studies that utilized intravenous contrast media, the range of sensitivity based on 5 studies was 82.4%–100% based on Kitajima *et al.*<sup>[13]</sup> and Michielsen *et al.*<sup>[12]</sup> respectively. Furthermore, for the assessment of specificity, the range for ce PET/CT was 33.0%–78.9% based on Michielsen *et al.*<sup>[12]</sup> and Lee *et al.*<sup>[15]</sup> respectively.

In general, most studies considered raised maximum standardized uptake value levels that were above background uptake and were not attributed to physiological uptake, as pathological. Whereas, other

studies had variable  $SUV_{max}$  values cited as threshold for the detection of malignancy, for example, Kitajima *et al.* had cited a cut-off value of 2.55,<sup>[13]</sup> Lee *et al.* cited two cut-off values 3.2 and 3.9 for improved sensitivity,<sup>[14]</sup> and Tanizaki *et al.* had cited 2.9 as a cut-off value.<sup>[17]</sup> We did not consider these studies in the meta-analysis due to variations in the methodology for the detection of OC.

Three studies incorporated MRI analysis for the same cohort of patients to diagnose OC.<sup>[9,12,16]</sup> Tsuboyama *et al.* analyzed separately as well as with consensus MRI findings compared to PET/CT findings; however, it did not involve PET/MRI image fusion. They noted that by combining PET/CT with ce MRI, they had improved accuracy to correctly diagnose indeterminate lesions compared to MRI alone.<sup>[16]</sup>

### Staging of ovarian cancer

A total of 13 PET/CT studies which aimed to stage OC were reviewed [Table 2]. These studies included 604 cases. Four of these studies were excluded as we were unable to create two-by-two tables<sup>[2,20-22]</sup> and one was excluded as it involved staging of mixed gynecological malignancies.<sup>[8]</sup> Thus, we included 8 studies and total of 380 patients that were focused on staging OC. Of these, two studies used ce PET/CT for analysis<sup>[12,23]</sup> and the rest of the studies used Id PET/CT for analysis.<sup>[24-29]</sup>

Ultimately, we only used three studies for our meta-analysis because some studies only analyzed lymph node involvement and we could not create two-by-two tables for the rest. Therefore, there were three studies<sup>[24,25,27]</sup> and 184 patients that analyzed peritoneal carcinomatosis for staging of OCs and achieved pooled sensitivity of 86.78%. We were not able to calculate pooled specificity as we did not have information on the number of benign cases in one of the studies.<sup>[25]</sup>

The majority of studies used lesion-based PET/CT staging to correlate with HPE findings. We note that extra-abdominal spread could be missed or underdiagnosed on conventional imaging (ci) because the gold standard to diagnose metastatic disease is based on laparotomy findings alone, which does not explore extra-abdominal regions.

### Detection of recurrence of ovarian cancer

A total of 22 PET/CT studies which studied the accuracy of the detection of recurrence of OC were reviewed [Table 3]. These studies included 1429 cases. Two of these studies were excluded as we were unable to create two-by-two tables<sup>[4,30]</sup> and one was excluded as it involved detection for recurrence of mixed gynecological malignancies.<sup>[31]</sup> Thus, we included 19 studies and total of 1067 patients that were focused on accuracy of detection of recurrence of OC. Of these, ten studies used ce PET/CT for analysis<sup>[5,31-39]</sup> and nine studies had used Id PET/CT for analysis.<sup>[3,6,40-46]</sup>

Ultimately, we only used thirteen studies, involving 661 patients for our meta-analysis because we could not create two-by-two tables for the rest of the studies. Therefore, for the detection of recurrence of OC using Id PET/CT, there were five studies<sup>[3,6,41-44]</sup> involving 235 patients that were analyzed. We noted that the pooled sensitivity and specificity were 89.84% and 89.58%, respectively. Furthermore, there were eight publications<sup>[5,7,33-36,38,39]</sup> that studied the accuracy for the detection of recurrence of OC using ce PET/CT involving 426 patients and achieved pooled sensitivity and specificity of 93.94% and 93.80%, respectively.

Overall, most studies advocated the use of PET/CT for detection of recurrence as it gave higher accuracy than serial CA-125 tumor marker levels monitoring

**Table 2: Staging of ovarian cancer using positron emission tomography/computed tomography**

Author	Sample, n (NM/M)	CT			PET/CT			Contrast media	Based analysis
		Sensitivity	Specificity	Accuracy	Sensitivity	Specificity	Accuracy		
Kim <i>et al.</i> (2013)	46 (20/26)	88.50	65.00	78.30	96.20	90.00	93.50	CECT, Id PET/CT	Patient
Lopez <i>et al.</i> (2016)	59 (4/55)	80.00	98.00	-	83.63	93.00	-	CECT, Id PET/CT	Patient
Signorelli <i>et al.</i> (2013)	68 (12/56)	-	-	-	83.30	98.20	95.60	Id PET/CT	Patient
Rubini <i>et al.</i> (2014)	79 (39/40)	-	-	-	85.00	92.31	88.61	Id PET/CT	Patient
Hynninen <i>et al.</i> (2013)	463	41.00	92.00	57.00	51.00	89.00	64.00	ce PET/CT	Lesion
Michielsen <i>et al.</i> (2014)	475 (267/208)	-	-	-	91.00	91.00	91.00	ce PET/CT	Scan
Schmidt <i>et al.</i> (2015)	135	96.00	92.00	-	95.00	96.00	-	CECT, Id PET/CT	Site
De Iaco <i>et al.</i> (2011)	346 (38/308)	-	-	-	78.90	68.40	-	Id PET/CT	Lesion

NM: No metastasis; M: Metastasis; CECT: Contrast-enhanced CT; ce PET/CT: Contrast-enhanced PET/CT; Id PET/CT: Low-dose PET/CT; PET: Positron emission tomography; CT: Computed tomography



**Table 3: Detection of recurrence of ovarian cancer using positron emission tomography/computed tomography**

Author	Sample, n (NR/R)	CT			PET/CT			Contrast media	Based analysis
		Sensitivity	Specificity	Accuracy	Sensitivity	Specificity	Accuracy		
1 Abdelhafez <i>et al.</i> (2016)	54 (28/26)	73.00	57.00	65.00	92.00	93.00	93.00	CECT, ce PET/CT	Scan
2 Antunovic <i>et al.</i> (2012)	121 (24/97)	NA	NA	NA	82.00	87.00	83.00	ld PET/CT	Patient
3 Chen <i>et al.</i> (2014)	155 (34/121)	NA	NA	NA	98.30	91.20	96.80	ld PET/CT	Scan
4 Dragosavac <i>et al.</i> (2013)	45 (3/42)	NA	NA	NA	100.0	100.0	100.0	ce PET/CT	Patient
5 Ghosh <i>et al.</i> (2013)	16 (1/15)	NA	NA	NA	100.0	100.0	NA	ld PET/CT	Patient
6 Gouhar <i>et al.</i> (2013)	73	NA	NA	NA	90.00	98.00	97.00	ce PET/CT	Lesion
7 Grueneisen <i>et al.</i> (2015)	39 (4/35)	NA	NA	NA	97.00	75.00	95.00	ce PET/CT	Patient
	24 (3/21)	NA	NA	NA	95.50	100.0	NA	ce PET/CT	Patient
8 Kitajima <i>et al.</i> (2012)	NA	NA	NA	NA	82.00	91.00	84.00	ce PET/CT	Lesion
	120 (74/46)	NA	NA	NA	86.90	95.90	92.50	ce PET/CT	Patient
9 Kitajima <i>et al.</i> (2014)	NA	NA	NA	NA	78.30	95.00	88.30	ld PET/CT	Patient
	30 (7/23)	NA	NA	NA	82.60	100.0	86.70	ce PET/CT	Patient
10 Nasu <i>et al.</i> (2011)	NA	NA	NA	NA	78.30	85.70	80.00	ld PET/CT	Patient
	30 (8/22)	95.50	100.0	NA	81.80	100.0	NA	CECT, ce PET/CT	Lesion
11 Panagiotidis <i>et al.</i> (2012)	73 (20/53)	NA	NA	NA	92.40	85.00	91.00	ce PET/CT	patient
12 Sanli <i>et al.</i> (2012)	47 (8/39)	NA	NA	NA	97.50	100.0	97.80	ce PET/CT	Patient
13 Sari <i>et al.</i> (2012)	34 (9/25)	NA	NA	NA	96.10	100.0	97.00	ld PET/CT	Patient
14 Takeuchi <i>et al.</i> (2014)	144 (9/39)	89.00	95.00	93.00	94.00	100.0	97.00	CECT, ld PET/CT	Scan
15 Pan <i>et al.</i> (2011)	37 (13/24)	NA	NA	NA	100.0	85.00	94.00	ld PET/CT	Patient
16 Peng <i>et al.</i> (2011)	27 (1/26)	NA	NA	NA	96.15	100.0	96.30	ld PET/CT	Patient
17 Fularz <i>et al.</i> (2015)	68	NA	NA	NA	90.90	80.00	85.30	ld PET/CT	Patient
18 Evangelista <i>et al.</i> (2015)	78	NA	NA	NA	98.60	77.80	96.10	ld PET/CT	Patient
19 Hebel <i>et al.</i> (2014)	48 (10/38)	NA	NA	NA	97.00	90.00	95.83	ce PET/CT	Patient

NR: No recurrence; R: Recurrence; CECT: Contrast-enhanced CT; ce PET/CT: Contrast-enhanced PET/CT; ld PET/CT: Low-dose PET/CT; PET: Positron emission tomography; CT: Computed tomography; NA: Not applicable

and ci as well as had good negative predictive value.<sup>[42]</sup> PET/CT is able to give an accuracy of 80% compared to CA-125 (64%) and ci (62%) in the detection of recurrence of high-grade OCs.<sup>[3]</sup> It is also able to give improved accuracy (87%) compared to CA-125 (60%) and ci (70%) for detection of recurrence in low-grade OCs.<sup>[3]</sup> Furthermore, recurrence of OC has been detected in 63% of patients scanned with PET/CT who interestingly had CA-125 levels within normal range.<sup>[44]</sup> In addition, symptomatic patients followed up due to suspected OC recurrence despite normal CA-125 and normal ci and thought to have false positive PET/CT scans have been confirmed to have recurrence 2 years later.<sup>[41]</sup> This suggests that PET/CT can detect recurrence of OC at an early stage. PET/CT also changed the intended management in 53.8% of patients by detecting recurrence in 90.9% of a subgroup of patients that had only low-level increases in CA-125 levels.<sup>[6]</sup>

Kitajima *et al.*<sup>[35]</sup> advocated the use of ce PET/CT compared to ld PET/CT as it gave higher confidence level for the detection of recurrence. They stated that the sensitivity, specificity, and accuracy of ce PET/CT versus ld PET/CT were 86.9%, 95.9%, and 92.5% versus 78.3%, 95.0%, and 88.3%, respectively. Subsequently, in 2014, Kitajima *et al.*<sup>[36]</sup> recommended the utility of fusion PET/MRI as it gave comparable

results and enabled reduction in radiation exposure. They stated that the accuracy of ce MRI and ce PET/CT had similar accuracy of 86.7%, whereas ld PET/CT and PET/MRI had accuracies of 80.7% and 93.3%, respectively.

Furthermore, another study also expounded upon the advantages of PET/MRI versus PET/CT as it gave comparable results for sensitivity and specificity, i.e. 85% and 87% versus 82% and 91%, respectively.<sup>[7]</sup> They advocated FAST MRI sequence and fusion with PET imaging for the detection of recurrence as it enabled markedly reduced radiation exposure for the patients. In addition, PET imaging has been noted to have greater accuracy in detecting small-to-medium-sized peritoneal implants measuring <2 cm as compared to conventional MRI alone.<sup>[38]</sup>

Moreover, molecular imaging has enabled improved localization of abdominopelvic as well as subdiaphragmatic lymph nodes,<sup>[33]</sup> peritoneal implants,<sup>[5]</sup> hence decreasing the rate for second look surgery.<sup>[34]</sup> Negative PET/CT scan findings also have negative predictive value of 90% for detection of recurrence; patients with negative scans were associated with progression-free survival in approximately 2-year follow-up.<sup>[39]</sup>

## Assessment of treatment response and prognostication

PET/CT metabolic parameters frequently used in the assessment of treatment response and prognostication include  $SUV_{max}$ , metabolic tumor volume (MTV), and total lesion glycolysis (TLG). MTV indicates the volume of metabolically active tumor and is stated using the unit  $cm^3$ ; thus, whole-body MTV indicates MTV of the primary tumor including metastatic deposits. It is usually calculated using semi-automated or automated computer programs. Whereas, TGV is a composite of metabolic activity and volume within the tumor mass and, therefore, has the unit of  $SUV_{mL}$ .<sup>[47]</sup> In addition, whole-body TLG (wbTLG) indicates the metabolic tumor burden of the primary lesion including metastatic deposits.

There were 13 original articles that addressed utility of PET/CT in prognostication of OC. Some articles discussed mediastinal uptake as an indicator for poor prognosis,<sup>[48]</sup> tumor histology such as serous carcinoma versus endometrioid type as having a higher risk of recurrence,<sup>[49]</sup> and the role of mid-cycle PET/CT imaging as a prognostic factor for the assessment of early metabolic response to neoadjuvant chemotherapy.<sup>[50]</sup> One study also utilized PET/CT to assess treatment response toward novel therapeutics such as temsirolimus, using metabolic parameters such as  $SUV_{max}$  and TLG to predict subsequent radiological response or disease progression.<sup>[51]</sup>

However, only nine articles actually assessed certain metabolic parameters such as  $SUV_{max}$ , MTV, and TLG and gave the hazard ratio and 95% confidence interval values for prediction of risk factors of OC recurrence.<sup>[49,52-59]</sup> Six studies stated that  $SUV_{max}$  was not a significant prognostic predictor for OC recurrence [Table 4], whereas only one study stated that it could play a role in predicting disease recurrence.<sup>[57]</sup> Several studies advocated MTV as a useful predictor of recurrence,<sup>[53,56]</sup> however, there is a consensus by all studies that identified TLG as a significant predictive factor for prognostication of OC.<sup>[49,53-56]</sup> Thus,

evidence of high wbTLG is accepted as a statistically significant indicator for poor prognosis and increased risk of recurrence of OC.

## Discussion

OC is a deadly malignancy affecting many women worldwide and is often detected at an advanced stage, as it often presents with non-specific symptoms like bloatedness and progressive abdominal distension. Once symptomatic, diagnosis is usually made by correlating ultrasound findings and CA-125 tumor marker levels. Subsequently, confirmation of diagnosis is made by peritoneal tapping, laparoscopic biopsy or exploratory laparotomy, and primary debulking surgery. In advanced cases, preoperative staging is often performed using conventional imaging such as CECT scan. Furthermore, the role of molecular imaging, such as PET/CT and PET/MRI, is slowly gaining popularity as it can give both anatomical and functional information for accurate staging and detection of recurrence. Nevertheless, due to concerns for increased ionizing radiation exposure, increased cost involved, and nonstandardized methods for reporting imaging findings, molecular imaging has yet to establish its role in the mainstream management of OC.

PET/CT involves injecting intravenous radioactive isotopes such as  $^{18}F$ -FDG followed by approximately 60 min uptake time and, subsequently, performing either 1d CT scan or CECT scan. CECT scan allows for diagnostic staging to be performed simultaneously during a single examination. However, the former, i.e., 1d CT scan is performed for attenuation correction and anatomical localization alone. Following the CT component scanning, the patient then undergoes PET examination in the same gantry with several bed positions to cover the required body parts in a particular examination. Attenuation correction of the PET images from PET/MRI can be performed with a segmentation-based attenuation correction maps which can be generated using vendor-provided image registration and fusion software.

**Table 4: Assessment of treatment response and prognostication**

Author (year)	Survival (months), median (range)	Sample size	$SUV_{max}$			MTV			TLG		
			HR	95% CI	$\rho$	HR	95% CI	$\rho$	HR	95% CI	$\rho$
Chung et al. (2012)	11 (3-43)	55	NA	NA	NA	5.571	1.279-24.272	NA	2.967	1.065-8.265	NA
Kim et al. (2015)	NA	56	NA	NA	0.083	NA	NA	0.004	NA	NA	0.004
Lee et al. (2014)	NA	175	NA	NA	NA	NA	NA	NA	NA	NA	0.008
Liao et al. (2013)	NA	47	1.077	0.923-1.256	0.345	1.124	0.954-1.326	0.163	1.043	1.01-1.078	0.011
Mayoral et al. (2015)	12.5 (10.7-20.6)	26	NA	NA	0.083	NA	NA	0.008	NA	NA	0.013
Nakamura et al. (2012)	14.9 (1-38)	51	NA	NA	0.049	NA	NA	NA	NA	NA	NA
Risum et al. (2011)	30.2 (1.1-58.3)	201	NA	NA	0.86	NA	NA	NA	NA	NA	NA
Shim et al. (2015)	NA	343	1.015	0.964-1.068	0.58	NA	NA	NA	NA	NA	NA
Vallius et al. (2016)	NA	26	1.02	0.98-1.06	0.32	NA	NA	NA	NA	NA	NA

MTV: Metabolic tumor volume; TLG: Total lesion glycolysis; HR: Hazard ratio; 95% CI: 95% confidence interval; NA: Not applicable;  $SUV_{max}$ : Maximum standardized uptake value

PET/MRI is gaining popularity as an emerging functional imaging tool which promises added advantage in oncologic imaging. Apart from the excellent soft-tissue resolution provided by MRI, the advantages of PET/MRI include the option for multiparametric studies to be performed simultaneously as a complementary examination as well as reduced exposure to potentially cancer-inducing ionizing radiation.<sup>[60]</sup> One meta-analysis of 57 studies compared the performance of PET/CT and PET/MRI in various types of malignancies, including head and neck cancers, lung cancers, and gynecological cancers among others.<sup>[60]</sup> It was noted that although PET/CT was superior for the detection of small lung nodules, the diagnostic performance of simultaneous PET/MRI was similar or even better to that of PET/CT in most cancers.<sup>[60]</sup>

Nevertheless, there are several technological challenges, such as development of PET detectors that can withstand the high magnetic field generated by MRI scanners, correct for the PET/MRI interactions, and use MRI images to produce attenuation maps.<sup>[60]</sup> As a matter of fact, there are currently two types of PET/MRI equipment which are available according to their mode of acquisition, i.e., sequential type and simultaneous type. The former involves consecutive PET and MRI acquisition followed by fusion and the latter involves simultaneous acquisition, thus providing better image co-registration at a reduced scan time.<sup>[60]</sup>

Bagade *et al.*<sup>[61]</sup> in their narrative review advocated the use of combined PET/CT and MRI systems, allowing for simultaneous imaging because tandems systems which perform sequential imaging lead to potential co-registration errors and prolonged imaging time. They also pointed out that the challenges of simultaneous imaging are to create robust photomultiplier tubes in PET systems that can withstand the high magnetic fields of MRI scanner. Despite these challenges, PET/MRI has its advantages as it can help resolve pathological lymph nodes in the para-iliac regions, which could be mistaken for a functional ovary on PET/CT as well as limit the radiation dose received by patients.<sup>[61]</sup>

Due to its improved soft-tissue contrast, PET/MRI may be more useful compared to PET/CT in detecting military disseminated metastases for evaluation of suspected OC recurrence.<sup>[61]</sup> Fuccio *et al.*<sup>[62]</sup> in their review in 2011, concluded that PET/CT gives high false negative results which predisposes it to miss low-grade tumors and early adenocarcinomas. Therefore, they recommended it to be used in conjunction with transvaginal ultrasound or MRI for characterization of adnexal masses and detection of OC. However, they concluded that PET/CT is a powerful method to stage OC with a major advantage of detecting extra-abdominal metastases.

Nonetheless, Kitajima *et al.*<sup>[63]</sup> in their narrative review in 2011, advised to exercise caution regarding the pitfalls of interpreting PET/CT scans, especially caused by physiological FDG uptake in premenopausal women, due to increased FDG uptake in ovaries during ovulation and early luteal phase of the menstrual cycle. They also declared that the resolution of PET/CT is limited to lesions larger than 1 cm and that lesions smaller than 5 mm frequently lead to false positive results. Therefore, they postulated that PET/MRI would give added benefits in oncologic imaging due to its improved soft-tissue resolution. Furthermore, sophisticated sequences such as diffusion-weighted imaging, functional MRI, and MR spectroscopy can all be incorporated with molecular imaging, giving added important information but with less radiation exposure. This can be especially important in patients who require follow-up imaging.

Yuan *et al.*<sup>[64]</sup> in their meta-analysis of 18 studies which included 882 patient concluded that PET/CT is more accurate than CT and MRI alone in the detection of lymph node metastasis for staging of OC. However, they admitted to the limitations of the study such as bias caused by the fact that the reference standard of imaging findings was sometimes based on follow-up imaging and not histopathological examination, as it is impossible to investigate all detected lesions by invasive procedures. They added that the accuracy of the results is also dependent on surgical efforts and extent as well as the degree of cytoreduction.

Our meta-analysis noted that the pooled sensitivity and specificity of ld PET/CT compared to ce PET/CT to detect recurrence of OC to be 89.84% and 89.58% versus 93.94% and 93.80%, respectively. This is comparable to previous meta-analysis by Limei *et al.*<sup>[65]</sup> that noted that the pooled sensitivity, specificity, positive and negative likelihood ratios, and the area under the curve of PET/CT scan for detection of OC recurrence were 91.0%, 89.7%, 6.140, 0.123, and 0.9497, respectively.

Conversely, Hildebrandt *et al.*<sup>[66]</sup> addressed the issue of methodological challenges in the diagnostic imaging arena, especially so in detection of recurrence. As biopsies are not obtainable from all lesions, this leads to variable sensitivity and specificity of PET/CT, which is based on histopathological results from only operable lesions. They emphasized the need for prognostic randomized controlled trials in the diagnostic field to justify the added benefit of imaging to the currently available effective treatment, which can make an impact on disease-free survival or overall survival.



## Conclusion

PET/CT and PET/MRI have a lot to offer in terms of management of OC, in particular for accurate staging and detection of recurrence. Its role for the assessment of treatment response will evolve with development of novel targeted therapies. Nevertheless, the added accuracy of these modalities needs to be justified by improved survival of OC patients, so as to outweigh the added cost and exposure to ionizing radiation caused by utilizing these methods. Thus, many more prospective studies with standardized methodologies need to be conducted before hybrid molecular imaging can be established as an acceptable mainstream imaging for OC.

## Acknowledgment

We would like to thank Universiti Putra Malaysia for providing the research grant (GP-IPM/UPM/2014/9404000) to facilitate this study. Dr. Subapriya Suppiah's Fellowship in Nuclear Medicine at the Nuclear Medicine Department, Royal Liverpool and Broadgreen University Hospitals, NHS Trusts, Liverpool, UK, was sponsored by the International Atomic Energy Agency.

## Financial support and sponsorship

The study was supported by Universiti Putra Malaysia research grant: GP-IPM/UPM/2014/9404000.

## Conflicts of interest

There are no conflicts of interest.

## References

- Dauwen H, Van Calster B, Deroose CM, Op de Beeck K, Amant F, Neven P, *et al.* PET/CT in the staging of patients with a pelvic mass suspicious for ovarian cancer. *Gynecol Oncol* 2013;131:694-700.
- Fruscio R, Sina F, Dolci C, Signorelli M, Crivellaro C, Dell'Anna T, *et al.* Preoperative <sup>18</sup>F-FDG PET/CT in the management of advanced epithelial ovarian cancer. *Gynecol Oncol* 2013;131:689-93.
- Antunovic L, Cimitan M, Borsatti E, Baresic T, Sorio R, Giorda G, *et al.* Revisiting the clinical value of <sup>18</sup>F-FDG PET/CT in detection of recurrent epithelial ovarian carcinomas: Correlation with histology, serum CA-125 assay, and conventional radiological modalities. *Clin Nucl Med* 2012;37:e184-8.
- Caobelli F, Alongi P, Evangelista L, Picchio M, Saladini G, Rensi M, *et al.* Predictive value of <sup>18</sup>F-FDG PET/CT in restaging patients affected by ovarian carcinoma: A multicentre study. *Eur J Nucl Med Mol Imaging* 2016;43:404-13.
- Panagiotidis E, Datsis IE, Exarhos D, Skilakaki M, Skoura E, Bamias A. High incidence of peritoneal implants in recurrence of intra-abdominal cancer revealed by <sup>18</sup>F-FDG PET/CT in patients with increased tumor markers and negative findings on conventional imaging. *Nucl Med Commun* 2012;33:431-8.
- Peng NJ, Liou WS, Liu RS, Hu C, Tsay DG, Liu CB. Early detection of recurrent ovarian cancer in patients with low-level increases in serum CA-125 levels by 2-[F-18]fluoro-2-deoxy-D-glucose-positron emission tomography/computed tomography. *Cancer Biother Radiopharm* 2011;26:175-81.
- Grueneisen J, Schaarschmidt BM, Heubner M, Suntharalingam S, Milk I, Kinner S, *et al.* Implementation of FAST-PET/MRI for whole-body staging of female patients with recurrent pelvic malignancies: A comparison to PET/CT. *Eur J Radiol* 2015;84:2097-102.
- Queiroz MA, Kubik-Huch RA, Hauser N, Freiwald-Chilla B, von Schulthess G, Froehlich JM, *et al.* PET/MRI and PET/CT in advanced gynaecological tumours: Initial experience and comparison. *Eur Radiol* 2015;25:2222-30.
- Xin J, Ma Q, Guo Q, Sun H, Zhang S, Liu C, *et al.* PET/MRI with diagnostic MR sequences vs. PET/CT in the detection of abdominal and pelvic cancer. *Eur J Radiol* 2016;85:751-9.
- NICE.org.uk. Ovarian Cancer: Recognition and Initial Management; 2011. Available from: <https://www.nice.org.uk/guidance/cg122>. [Last accessed on 2016 Dec 08].
- American College of Obstetricians and Gynecologists Committee on Gynecologic Practice. Committee Opinion No 477: The role of the obstetrician-gynecologist in the early detection of epithelial ovarian cancer. *Obstet Gynecol* 2011;117:742-6.
- Michielsen K, Vergote I, Op de Beeck K, Amant F, Leunen K, Moerman P, *et al.* Whole-body MRI with diffusion-weighted sequence for staging of patients with suspected ovarian cancer: A clinical feasibility study in comparison to CT and FDG-PET/CT. *Eur Radiol* 2014;24:889-901.
- Kitajima K, Suzuki K, Senda M, Kita M, Nakamoto Y, Onishi Y, *et al.* FDG-PET/CT for diagnosis of primary ovarian cancer. *Nucl Med Commun* 2011;32:549-53.
- Lee JK, Min KJ, So KA, Kim S, Hong JH. The effectiveness of dual-phase <sup>18</sup>F-FDG PET/CT in the detection of epithelial ovarian carcinoma: A pilot study. *J Ovarian Res* 2014;7:15.
- Lee JW, Lee JH, Cho A, Yun M, Lee JD, Kim YT, *et al.* The performance of contrast-enhanced FDG PET/CT for the differential diagnosis of unexpected ovarian mass lesions in patients with nongynecologic cancer. *Clin Nucl Med* 2015;40:97-102.
- Tsuboyama T, Tatsumi M, Onishi H, Nakamoto A, Kim T, Hori M, *et al.* Assessment of combination of contrast-enhanced magnetic resonance imaging and positron emission tomography/computed tomography for evaluation of ovarian masses. *Invest Radiol* 2014;49:524-31.
- Tanizaki Y, Kobayashi A, Shiro M, Ota N, Takano R, Mabuchi Y, *et al.* Diagnostic value of preoperative SUVmax on FDG-PET/CT for the detection of ovarian cancer. *Int J Gynecol Cancer* 2014;24:454-60.
- Minamimoto R, Senda M, Terauchi T, Jinnouchi S, Inoue T, Iinuma T, *et al.* Analysis of various malignant neoplasms detected by FDG-PET cancer screening program: Based on a Japanese Nationwide Survey. *Ann Nucl Med* 2011;25:45-54.
- Alessi A, Martinelli F, Padovano B, Serafini G, Lorusso D, Lorenzoni A, *et al.* FDG-PET/CT to predict optimal primary cytoreductive surgery in patients with advanced ovarian cancer: Preliminary results. *Tumori* 2016;102:103-7.
- Hynninen J, Auranen A, Carpén O, Dean K, Seppänen M, Kempainen J, *et al.* FDG PET/CT in staging of advanced epithelial ovarian cancer: Frequency of supradiaphragmatic lymph node metastasis challenges the traditional pattern of disease spread. *Gynecol Oncol* 2012;126:64-8.
- Park T, Lee S, Park S, Lee E, Park K, Rhee S, *et al.* Value of <sup>18</sup>F-FDG PET/CT in the detection of ovarian malignancy. *Nucl Med Mol Imaging* 2015;49:42-51.
- Schwenzer NF, Schmidt H, Gatidis S, Brendle C, Müller M, Königsrainer I, *et al.* Measurement of apparent diffusion coefficient with simultaneous MR/positron emission tomography in patients



- with peritoneal carcinomatosis: Comparison with  $^{18}\text{F}$ -FDG-PET. *J Magn Reson Imaging* 2014;40:1121-8.
23. Hynninen J, Kempainen J, Lavonius M, Virtanen J, Matomäki J, Oksa S, *et al.* A prospective comparison of integrated FDG-PET/contrast-enhanced CT and contrast-enhanced CT for pretreatment imaging of advanced epithelial ovarian cancer. *Gynecol Oncol* 2013;131:389-94.
  24. Kim HW, Won KS, Zeon SK, Ahn BC, Gayed IW. Peritoneal carcinomatosis in patients with ovarian cancer: Enhanced CT versus  $^{18}\text{F}$ -FDG PET/CT. *Clin Nucl Med* 2013;38:93-7.
  25. Lopez-Lopez V, Cascales-Campos PA, Gil J, Frutos L, Andrade RJ, Fuster-Quinonero M, *et al.* Use of (18) F-FDG PET/CT in the preoperative evaluation of patients diagnosed with peritoneal carcinomatosis of ovarian origin, candidates to cytoreduction and hipec. A pending issue. *Eur J Radiol* 2016;85:1824-8.
  26. Signorelli M, Guerra L, Pirovano C, Crivellaro C, Fruscio R, Buda A, *et al.* Detection of nodal metastases by  $^{18}\text{F}$ -FDG PET/CT in apparent early stage ovarian cancer: A prospective study. *Gynecol Oncol* 2013;131:395-9.
  27. Rubini G, Altini C, Notaristefano A, Merenda N, Rubini D, Ianora AA, *et al.* Role of  $^{18}\text{F}$ -FDG PET/CT in diagnosing peritoneal carcinomatosis in the restaging of patient with ovarian cancer as compared to contrast enhanced CT and tumor marker Ca-125. *Rev Esp Med Nucl Imagen Mol* 2014;33:22-7.
  28. Schmidt S, Meuli RA, Achtari C, Prior JO. Peritoneal carcinomatosis in primary ovarian cancer staging: Comparison between MDCT, MRI, and  $^{18}\text{F}$ -FDG PET/CT. *Clin Nucl Med* 2015;40:371-7.
  29. De Iaco P, Musto A, Orazi L, Zamagni C, Rosati M, Allegri V, *et al.* FDG-PET/CT in advanced ovarian cancer staging: Value and pitfalls in detecting lesions in different abdominal and pelvic quadrants compared with laparoscopy. *Eur J Radiol* 2011;80:e98-103.
  30. Palomar A, Nanni C, Castellucci P, Ambrosini V, Montini GC, Allegri V, *et al.* Value of FDG PET/CT in Patients with Treated Ovarian Cancer and Raised CA125 Serum Levels. *Mol Imaging Biol* 2012;14:123-9.
  31. Beiderwellen K, Grueneisen J, Ruhlmann V, Buderath P, Aktas B, Heusch P, *et al.* [ $^{18}\text{F}$ ] FDG PET/MRI vs. PET/CT for whole-body staging in patients with recurrent malignancies of the female pelvis: Initial results. *Eur J Nucl Med Mol Imaging* 2015;42:56-65.
  32. Abdelhafez Y, Tawakol A, Osama A, Hamada E, El-Refaei S. Role of  $^{18}\text{F}$ -FDG PET/CT in the detection of ovarian cancer recurrence in the setting of normal tumor markers. *Egypt J Radiol Nucl Med* 2016;47:1787-94.
  33. Dragosavac S, Derchain S, Caserta NM, DE Souza G. Staging recurrent ovarian cancer with  $^{18}\text{F}$ FDG PET/CT. *Oncol Lett* 2013;5:593-597.
  34. Gouhar GK, Siam S, Sadek SM, Ahmed RA. Prospective assessment of  $^{18}\text{F}$ -FDG PET/CT in detection of recurrent ovarian cancer. *Egypt J Radiol Nucl Med* 2013;44:913-22.
  35. Kitajima K, Ueno Y, Suzuki K, Kita M, Ebina Y, Yamada H, *et al.* Low-dose non-enhanced CT versus full-dose contrast-enhanced CT in integrated PET/CT scans for diagnosing ovarian cancer recurrence. *Eur J Radiol* 2012;81:3557-62.
  36. Kitajima K, Suenaga Y, Ueno Y, Kanda T, Maeda T, Makihara N, *et al.* Value of fusion of PET and MRI in the detection of intra-pelvic recurrence of gynecological tumor: Comparison with  $^{18}\text{F}$ -FDG contrast-enhanced PET/CT and pelvic MRI. *Ann Nucl Med* 2014;28:25-32.
  37. Nasu K, Abe W, Takai N, Tomonari K, Narahara H. Impact of positron emission tomography/computed tomography in the management of patients with epithelial ovarian carcinoma after treatment. *Arch Gynecol Obstet* 2011;283:1121-6.
  38. Sanli Y, Turkmen C, Bakir B, Iyibozkurt C, Ozel S, Has D, *et al.* Diagnostic value of PET/CT is similar to that of conventional MRI and even better for detecting small peritoneal implants in patients with recurrent ovarian cancer. *Nucl Med Commun* 2012;33:509-15.
  39. Hebel CB, Behrendt FF, Heinzel A, Krohn T, Mottaghy FM, Bauerschlag DO, *et al.* Negative  $^{18}\text{F}$ -2-fluorodeoxyglucose PET/CT predicts good cancer specific survival in patients with a suspicion of recurrent ovarian cancer. *Eur J Radiol* 2014;83:463-7.
  40. Chen YM, Chen T, Zee CS, Shi YP, Wan LR, Tong LJ. Is there an impact of  $^{18}\text{F}$ -FDG PET/CT on the surveillance and clinical management of recurrent ovarian cancer? Research based on a large sample in a single PET/CT center. *Nucl Med Commun* 2014;35:347-52.
  41. Ghosh J, Thulker S, Kumar R, Malhotra A, Kumar A, Kumar L. Role of FDG PET-CT in asymptomatic epithelial ovarian cancer with rising serum CA-125: A pilot study. *Natl Med J India* 2013;26:327-31.
  42. Sari O, Kaya B, Kara PO, Gedik GK, Celik C, Ozbek O, *et al.* The role of FDG-PET/CT in ovarian cancer patients with high tumor markers or suspicious lesion on contrast-enhanced CT in evaluation of recurrence and/or in determination of intraabdominal metastases. *Rev Esp Med Nucl Imagen Mol* 2012;31:3-8.
  43. Takeuchi S, Lucchini M, Schmelzer KM, Coleman RL, Gershenson DM, Munsell ME, *et al.* Utility of  $^{18}\text{F}$ -FDG PET/CT in follow-up of patients with low-grade serous carcinoma of the ovary. *Gynecol Oncol* 2014;133:100-4.
  44. Pan HS, Lee SL, Huang LW, Chen YK. Combined positron emission tomography-computed tomography and tumor markers for detecting recurrent ovarian cancer. *Arch Gynecol Obstet* 2011;283:335-41.
  45. Fularz M, Adamiak P, Czepczynski R, Jarzabek-Bielecka G, Rewers A, Kedzia W, *et al.* Utility of PET/CT in the diagnosis of recurrent ovarian cancer depending on CA 125 serum level. *Nuklearmedizin* 2015;54:158-62.
  46. Evangelista L, Palma MD, Gregianin M, Nardin M, Roma A, Nicoletto MO, *et al.* Diagnostic and prognostic evaluation of fluorodeoxyglucose positron emission tomography/computed tomography and its correlation with serum cancer antigen-125 (CA125) in a large cohort of ovarian cancer patients. *J Turk Ger Gynecol Assoc* 2015;16:137-44.
  47. Francis RJ, Byrne MJ, van der Schaaf AA, Boucek JA, Nowak AK, Phillips M, *et al.* Early prediction of response to chemotherapy and survival in malignant pleural mesothelioma using a novel semiautomated 3-dimensional volume-based analysis of serial  $^{18}\text{F}$ -FDG PET scans. *J Nucl Med* 2007;48:1449-58.
  48. Bats AS, Hugonnet F, Huchon C, Bensaid C, Pierquet-Ghazzar N, Faraggi M, *et al.* Prognostic significance of mediastinal  $^{18}\text{F}$ -FDG uptake in PET/CT in advanced ovarian cancer. *Eur J Nucl Med Mol Imaging* 2012;39:474-80.
  49. Chung HH, Kwon HW, Kang KW, Kim JW, Park NH, Song YS, *et al.* Preoperative [ $^{18}\text{F}$ ] FDG PET/CT predicts recurrence in patients with epithelial ovarian cancer. *J Gynecol Oncol* 2012;23:28-34.
  50. Martoni AA, Rosati M, Zamagni C, De Iaco P, Castellucci P, Quercia S, *et al.* Explorative study on the predictive and prognostic value of early complete metabolic response by FDG-PET-CT during neoadjuvant chemotherapy in patients with advanced ovarian cancer. *Clin Ovarian Other Gynecol Cancer* 2012; 5:2-9.
  51. Boers-Sonderen MJ, de Geus-Oei LF, Desar IM, van der Graaf WT, Oyen WJ, Ottevanger PB, *et al.* Temsirolimus and pegylated liposomal doxorubicin (PLD) combination therapy in breast, endometrial, and ovarian cancer: Phase Ib results and prediction of clinical outcome with FDG-PET/CT. *Target Oncol* 2014;9:339-47.

52. Risum S, Høgdall C, Loft A, Berthelsen AK, Høgdall E, Nedergaard L, *et al.* Does the use of diagnostic PET/CT cause stage migration in patients with primary advanced ovarian cancer? *Gynecol Oncol* 2010;116:395-8.
53. Kim CY, Jeong SY, Chong GO, Son SH, Jung JH, Kim DH, *et al.* Quantitative metabolic parameters measured on F-18 FDG PET/CT predict survival after relapse in patients with relapsed epithelial ovarian cancer. *Gynecol Oncol* 2015;136:498-504.
54. Lee JW, Cho A, Lee JH, Yun M, Lee JD, Kim YT, *et al.* The role of metabolic tumor volume and total lesion glycolysis on <sup>18</sup>F-FDG PET/CT in the prognosis of epithelial ovarian cancer. *Eur J Nucl Med Mol Imaging* 2014;41:1898-906.
55. Liao S, Lan X, Cao G, Yuan H, Zhang Y. Prognostic predictive value of total lesion glycolysis from <sup>18</sup>F-FDG PET/CT in post-surgical patients with epithelial ovarian cancer. *Clin Nucl Med* 2013;38:715-20.
56. Mayoral M, Fernandez-Martinez A, Vidal L, Fuster D, Aya F, Pavia J, *et al.* Prognostic value of <sup>18</sup>F-FDG PET/CT volumetric parameters in recurrent epithelial ovarian cancer. *Rev Esp Med Nucl Imagen Mol* 2016;35:88-95.
57. Nakamura K, Hongo A, Kodama J, Hiramatsu Y. The pretreatment of maximum standardized uptake values (SUVmax) of the primary tumor is predictor for poor prognosis for patients with epithelial ovarian cancer. *Acta Med Okayama* 2012;66:53-60.
58. Shim SH, Lee SJ, Kim SO, Kim SN, Kim DY, Lee JJ, *et al.* Nomogram for predicting incomplete cytoreduction in advanced ovarian cancer patients. *Gynecol Oncol* 2015;136:30-6.
59. Vallius T, Peter A, Auranen A, Carpén O, Kempainen J, Matomäki J, *et al.* <sup>18</sup>F-FDG-PET/CT can identify histopathological non-responders to platinum-based neoadjuvant chemotherapy in advanced epithelial ovarian cancer. *Gynecol Oncol* 2016;140:29-35.
60. Riola-Parada C, García-Cañamaque L, Pérez-Dueñas V, Garcerant-Tafur M, Carreras-Delgado JL. Simultaneous PET/MRI vs. PET/CT in oncology. A systematic review. *Rev Esp Med Nucl Imagen Mol* 2016;35:306-12.
61. Bagade S, Fowler KJ, Schwarz JK, Grigsby PW, Dehdashti F. PET/MRI evaluation of gynecologic malignancies and prostate cancer. *Semin Nucl Med* 2015;45:293-303.
62. Fuccio C, Castellucci P, Marzola MC, Al-Nahhas A, Fanti S, Rubello D. Noninvasive and invasive staging of ovarian cancer: Review of the literature. *Clin Nucl Med* 2011;36:889-93.
63. Kitajima K, Murakami K, Sakamoto S, Kaji Y, Sugimura K. Present and future of FDG-PET/CT in ovarian cancer. *Ann Nucl Med* 2011;25:155-64.
64. Yuan Y, Gu ZX, Tao XF, Liu SY. Computer tomography, magnetic resonance imaging, and positron emission tomography or positron emission tomography/computer tomography for detection of metastatic lymph nodes in patients with ovarian cancer: A meta-analysis. *Eur J Radiol* 2012;81:1002-6.
65. Limei Z, Yong C, Yan X, Shuai T, Jiangyan X, Zhiqing L. Accuracy of positron emission tomography/computed tomography in the diagnosis and restaging for recurrent ovarian cancer: A meta-analysis. *Int J Gynecol Cancer* 2013;23:598-607.
66. Hildebrandt MG, Kodahl AR, Teilmann-Jørgensen D, Mogensen O, Jensen PT. [<sup>18</sup>F] fluorodeoxyglucose PET/computed tomography in breast cancer and gynecologic cancers: A literature review. *PET Clin* 2015;10:89-104.