

## Original Article

# Positron emission tomography–computed tomography-associated incidental neoplasms of the thyroid gland

## ABSTRACT

With the increasing use of  $^{18}\text{F}$ -fluorodeoxyglucose (FDG) positron emission tomography–computed tomography (PET-CT) scans in oncology, the finding of thyroid incidentalomas, also popularly described as PET-associated incidental neoplasms (PAINs) of the thyroid gland is not unusual. The  $^{18}\text{F}$ -FDG PET-CT scans of all patients who underwent imaging for indications other than thyroid malignancy at our tertiary care center between January 1 and December 31, 2017, were retrospectively reviewed for PAINs of the thyroid. A total of 1737  $^{18}\text{F}$ -FDG PET-CT scans were done at our center in the year 2017. 288 thyroid incidentalomas were detected in the said period; the rate of PET-CT-detected thyroid incidentalomas being 16.58%, focal incidentalomas among them being 11.7%. Only 29 out of 204 patients (14.21%) with focal thyroid incidentalomas in our cohort underwent an aspiration cytology and/or ultrasound. The rate of malignancy among the PET detected focal thyroid incidentalomas in the cohort of patients with a proven diagnosis was 10.34%. Our study highlights the challenges in the evaluation and management of PAIN in a tertiary care oncology setting. None of the factors studied including nodule size and standardized uptake value predicted the risk of malignancy. Clinicians specializing in the management of thyroid nodules need to understand the clinical significance of the PAIN, and we hope that our unique experience adds to the limited clinical information available in this regard.

**Keywords:** Positron emission tomography, positron emission tomography associated incidental neoplasms, prognosis, thyroid incidentalomas

## INTRODUCTION

Incidentalomas are generally described as incidental imaging findings in an organ in patients without any signs/symptoms of disease in that organ of interest.<sup>[1]</sup> Positron emission tomography–computerized tomography (PET-CT)-detected incidentalomas have been reported to occur in many organs of the body including the thyroid gland, adrenal gland, lung, gastrointestinal tract, breast, and the prostate gland as well. Thyroid incidentalomas are in fact common in imaging, but the risk of harboring an underlying malignancy varies greatly depending on the imaging modality used.<sup>[2,3]</sup> PET-CT-detected incidentalomas also described as PET-associated incidental neoplasms (PAINs) of the thyroid gland are rare but are being increasingly reported with the increasing use of the PET-CT scans in oncological practice. We review and critically analyze our data of PAIN of the thyroid identified in a cohort of cancer patients over a year.

## MATERIALS AND METHODS

The  $^{18}\text{F}$ -fluorodeoxyglucose (FDG) PET-CT scans of all patients who underwent imaging for indications other than thyroid malignancy at our tertiary care center between January 1 and December 31, 2017, were retrospectively reviewed for PAINs of the thyroid. PET-CT (GE DISCOVERY VCT)-BGO scanner

**K. KAMAKSHI, ARVIND KRISHNAMURTHY, V. KARTHIK, PREETHA VINODKUMAR<sup>1</sup>, R. KRISHNA KUMAR<sup>2</sup>, K. M. LAKSHMIPATHY<sup>3</sup>**

Departments of Surgical Oncology, <sup>1</sup>Clinical Research and <sup>2</sup>Nuclear Medicine, Cancer Institute (WIA), <sup>3</sup>HCG PET-CT Centre, Chennai, Tamil Nadu, India


**Address for correspondence:** Dr. Arvind Krishnamurthy, Cancer Institute (WIA), 38, Sardar Patel Road, Adyar, Chennai - 600 036, Tamil Nadu, India.  
E-mail: drarvindkrishnamurthy@yahoo.co.in

**Submitted:** 26-Apr-2019, **Accepted:** 29-May-2019, **Published:** 14-Jan-2020

This is an open access journal, and articles are distributed under the terms of the Creative Commons Attribution-NonCommercial-ShareAlike 4.0 License, which allows others to remix, tweak, and build upon the work non-commercially, as long as appropriate credit is given and the new creations are licensed under the identical terms.

**For reprints contact:** reprints@medknow.com

**How to cite this article:** Kamakshi K, Krishnamurthy A, Karthik V, Vinodkumar P, Kumar RK, Lakshmi pathy KM. Positron emission tomography–computed tomography-associated incidental neoplasms of the thyroid gland. World J Nucl Med 2020;19:36-40.

Access this article online	
<b>Website:</b> www.wjnm.org	<b>Quick Response Code</b> 
<b>DOI:</b> 10.4103/wjnm.WJNM_33_19	

was used in all patients and  $^{18}\text{F}$ -FDG was the pharmaceutical agent employed. As per our institutional practice, the entire  $^{18}\text{F}$ -FDG PET-CT scans were read independently by two trained specialists, a nuclear medicine physician and a radiologist, and a final diagnosis of FDG uptake was made in consensus. The classification of FDG uptake in the thyroid was additionally expressed by semi-quantitative analysis of the uptake by calculation of standardized uptake value (SUV).

Data pertaining to the fine-needle aspiration cytology (FNAC) by Bethesda reporting system and ultrasound reports of focal thyroid incidentalomas were collected from the medical records of the patients who had focal PAINs of the thyroid gland. The entire clinical data were analyzed for any correlation between  $^{18}\text{F}$ -FDG PET-CT scan findings and cytological diagnosis of thyroid malignancy. IBM SPSS software (version 20, Armonk, NY, IBM Corp., USA) was used for statistical analysis of the data sets.

## RESULTS

A total of 1737  $^{18}\text{F}$ -FDG PET-CT scans were done as a part of the staging/follow-up of patients with different index tumors at our center in the year 2017. 288 thyroid incidentalomas were detected in the said period; the rate of PET-CT-detected thyroid incidentalomas being 16.58%.

### Focality

The type of uptake on the  $^{18}\text{F}$ -FDG PET-CT scans was “focal” in 204 patients (70.83%) diffuse in 56 patients (19.44%) and no uptake in 28 patients (9.72%). The incidence of focal incidentalomas was 11.7%.

### Age/sex

The mean age in our thyroid incidentaloma cohort was 51 years. There was a clear female preponderance (199 [69%] females to 89 [31%] males). The mean age among females was 51.6 years, and among males was 49.8 years.

### Primary tumors

The most common indications for  $^{18}\text{F}$ -FDG PET-CT was for the evaluation of primaries of the lung (22.92%), the lymphoreticular system (22.57%), and for breast cancers (13.54%). The most common primary tumors in patients with thyroid incidentalomas were seen to be the lymphoreticular system (26.04%), lung (22.57%), and breast cancers (13.54%). There was no statistically significant correlation between the site of primary tumor and thyroid incidentaloma detection ( $P = 0.62$ ).

Among the 204 patients with focal  $^{18}\text{F}$ -FDG PET-CT thyroid incidentalomas, only 29 patients (14.22%) had undergone

further characterization of their thyroid nodules, both with an ultrasound and an FNAC. The remaining 175 (85.78%) patients did not undergo further investigation of their thyroid incidentalomas either due to locally advanced index tumor/metastatic disease, poor general condition, or due to various patient/physician factors.

### Size

The overall mean size of the thyroid incidentalomas was 2.3 cm. The mean size of the benign thyroid nodule among them in our series was 2.86 cm; and the mean size of the malignant/potentially malignant thyroid nodules was 1.9 cm. There was no statistically significant correlation between the nodule size and pathology ( $P = 0.22$ ).

### Standardized uptake values

The overall mean SUV for the  $^{18}\text{F}$ -FDG PET-CT-detected thyroid incidentalomas in our series was 3.83. The mean SUV among incidentalomas with diffuse uptake was 3.76, and the mean SUV among incidentalomas with focal uptake was 4.52. The mean SUV among thyroid incidentalomas (Bethesda III-IV) was 5.29 while it was 7.66 among thyroid incidentalomas of Bethesda II. Interestingly, the thyroid incidentaloma with highest SUV in our series (24.4) was of Bethesda II. There was no statistically significant correlation between SUV and cytology ( $P = 0.262$ ).

### Bethesda classification

Only 29 patients (14.22%) of the focal thyroid incidentalomas had a formal cytological diagnosis. The flow schema along with the Bethesda classification is given in Table 1.

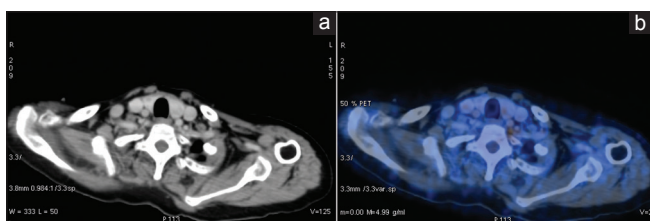
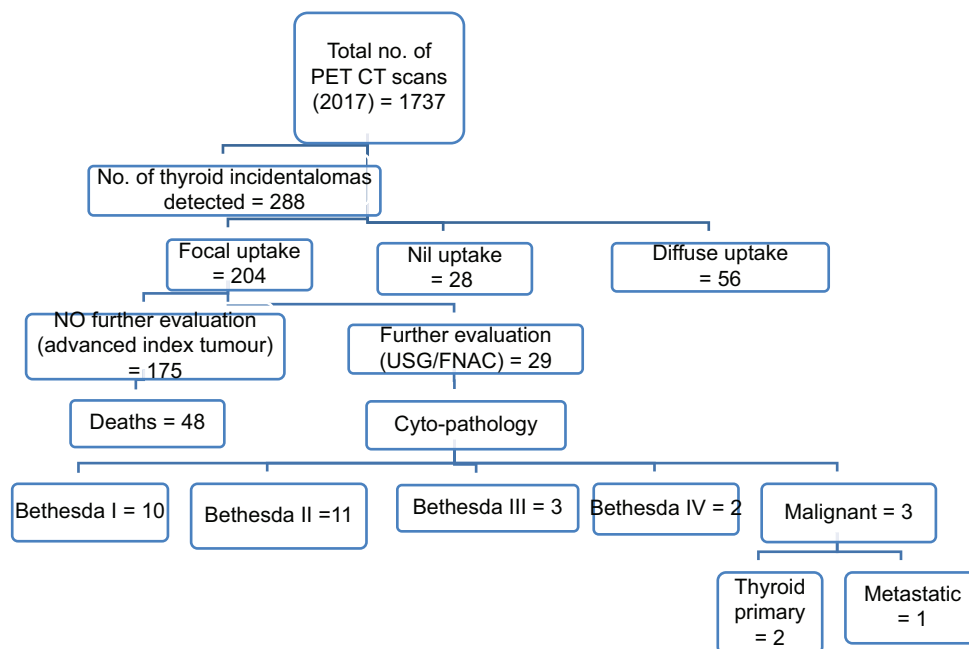
## DISCUSSION

A thyroid incidentaloma, by definition, is any clinically in-evident thyroid nodule picked up during imaging done for the evaluation of a different disease process. High-resolution neck ultrasound examinations report a prevalence of incidentally detected thyroid nodules ranging from 19% to 46%<sup>[4,6]</sup> among the general population; however, the associated risk of cancer is very low and ranges from 1.5%–10%.

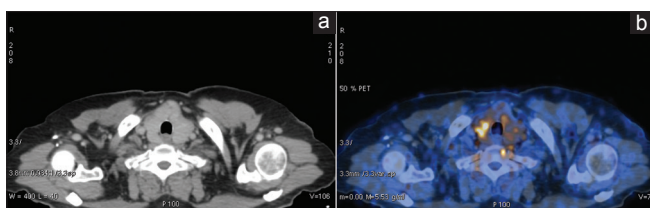
The PAINs of thyroid are relatively rarer. The thyroid gland generally shows low avidity for  $^{18}\text{F}$ -FDG [Figure 1a and b]. It has been well documented in literature that diffuse uptake of the thyroid gland on  $^{18}\text{F}$ -FDG PET-CT indicates a benign/inflammatory pathological process, usually thyroiditis and does not warrant further evaluation [Figure 2a and b].<sup>[7]</sup> However, any focal uptake of the thyroid gland on a PET-CT scan is a cause for concern<sup>[8-10]</sup> [Figure 3a and b].

Most published data suggest that the incidence rates for PET-detected incidentalomas are low (ranging from 1.2%–4.3%);

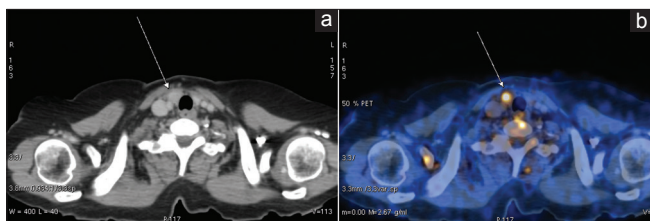
**Table 1: Flow schema of our patient cohort**



**Figure 1: (a and b) Thyroid incidentaloma with no uptake on positron emission tomography-computed tomography**



**Figure 2: (a and b) Thyroid incidentaloma with diffuse uptake on positron emission tomography-computed tomography**



**Figure 3: (a and b) Thyroid incidentaloma with focal uptake on positron emission tomography-computed tomography**

however, the incidence of malignancy is reported to be significantly higher.<sup>[7,9-14]</sup> A retrospective review of 32 studies reported a median frequency of 2.3% of FDG-avid lesions in

the populations studied. Further, the review reports thyroid cancer to occur in nearly one in every three patients with focal FDG-avid thyroid lesions.<sup>[3]</sup> The incidence of focal thyroid incidentalomas in our series was 11.74%, (204/1737) further, the rate of malignancy among the PET detected focal thyroid incidentalomas in the cohort of patients with a proven diagnosis was 10.34%. It is noteworthy to mention that only 29 out of 204 patients (14.21%) with focal thyroid incidentalomas in our cohort underwent a biopsy and/or ultrasound. This rate of malignancy quoted in literature; ranges from 14% to 50%.<sup>[7,11,12,15,16]</sup> A few reports have in fact reported a similar incidence<sup>[17]</sup> of malignancy and some other studies have quoted a much lower incidence (3%) of malignancy.<sup>[18]</sup>

There is a clear lack of consensus on the proportion of malignancy in the PAINS of the thyroid. This can be partly explained by the variation in the thyroid nodule prevalence's which in turn can interfere with epidemiological data on the frequency and malignancy rates of FDG-avid lesions. A recent systematic review and meta-analysis were performed to better understand this wide variation among the various published studies. The meta-analysis included 31 studies with a total of 197,296 patients. 3659 focal thyroid incidentalomas were identified with 1341 having definitive cytopathology or histopathology.<sup>[19]</sup> The results of the meta-analysis brought out a major limitation of the published studies that could possibly explain this lack of consensus. Studies that had a >50% of included lesions with a definitive diagnosis the pooled proportion of malignancy was calculated to be

55% (95% CI, 49%–62%,  $I^2 = 63.4\%$ ) and was significantly higher than those studies with <50% of lesions with a definitive diagnosis, which was at 11% (95% CI, 7%–14%,  $I^2 = 84.8\%$ ).<sup>[19]</sup> The studies of the PAINs of thyroid reviewed thus had a wide variation with regards to the proportion of patients who had a definite cyto/histopathological diagnosis (15%–83%), and this variation makes it difficult to arrive at the correct proportion of malignancy in this patient population.

The above limitation was also observed in our study as well, with only 14% of the focal thyroid incidentalomas having a definitive cytological diagnosis. In the presence of another malignancy, there seems to be reluctance on the part of the patient and possibly the caregivers toward chasing the PAINs of the thyroid. In fact, the evaluation of thyroid incidentalomas in the scenario of advanced index malignancy is not recommended, more so in patients with poor performance status.<sup>[16,20]</sup> This is further substantiated by the fact that nearly 27% of our patient cohort had died within a year of diagnosis of these patients of advanced index cancers having the thyroid incidentalomas. Many series have reported an even higher mortality rate of up to 50%.<sup>[3,21]</sup> Another limitation of our study was the modest number over 1 year and also the fact that the study was a single institution study. The result of our study preferably needs to be validated in a much larger cohort of patients, preferably a multiinstitutional/population based.

Attempts have been made to study the factors (including size and SUV) that help predict the risk of thyroid malignancy among patients with PET-detected thyroid incidentalomas. None of the factors studied, i.e., age, sex, tumor size, and SUV<sub>max</sub> in our study were predictors of thyroid malignancy. The expression of GLUT1 has been reported to be highly variable in thyroid cancers, and this could explain the lack of association of SUV and the incidence of malignancy in a majority of the reported studies,<sup>[21-25]</sup> despite a few studies suggesting a definite association.<sup>[19,26-28]</sup>

The PET-detected thyroid incidentalomas are generally known to present with a high incidence of unfavorable prognostic features and are further believed to carry a worse prognosis.<sup>[3,12,29]</sup> Considering this aggressive biological behavior, the vast majority of the clinicians would recommend a risk-adapted approach using further evaluation by an initial ultrasound and a subsequent FNAC in an attempt to risk stratify the PET-CT detected focal thyroid incidentalomas.<sup>[30,31]</sup> In regular clinical practice, the decision to evaluate the PET-CT-detected focal thyroid incidentalomas would additionally depend on the stage of the index malignancy as well as the performance status and preference of the patients.

## CONCLUSION

Our study highlights the challenges in the evaluation and management of PAIN in a tertiary care oncology setting. Further, our study showed that none of the factors studied including nodule size and SUV predicted the risk of malignancy. The management of PAIN of the thyroid gland must be considered in the context of the prognosis and treatment for the known malignancy, apart from other patient factors. Finally, clinicians specializing in the management of thyroid nodules must understand the clinical significance of PET-CT-detected thyroid incidentalomas, and we hope that our unique experience adds to the limited clinical information available in this regard.

## Ethical issues

All procedures performed in this article were in accordance with the ethical standards of the institutional research committee and with the 1964 Helsinki declaration and its later amendments or comparable ethical standards.

## Informed consent

Appropriate informed consents have been obtained.

## Declaration of patient consent

The authors certify that they have obtained all appropriate patient consent forms. In the form, the patients have given their consent for their images and other clinical information to be reported in the journal. The patients understand that their names and initials will not be published and due efforts will be made to conceal their identity, but anonymity cannot be guaranteed.

## Financial support and sponsorship

Nil.

## Conflicts of interest

There are no conflicts of interest.

## REFERENCES

1. Lumbreras B, Donat L, Hernández-Aguado I. Incidental findings in imaging diagnostic tests: A systematic review. *Br J Radiol* 2010;83:276-89.
2. Uppal A, White MG, Nagar S, Aschebrook-Kilfoy B, Chang PJ, Angelos P, *et al.* Benign and malignant thyroid incidentalomas are rare in routine clinical practice: A review of 97,908 imaging studies. *Cancer Epidemiol Biomarkers Prev* 2015;24:1327-31.
3. Asmar A, Simonsen L, Bülow J, Asmar M. Work-up of thyroid incidentalomas identified by 18F-fluorodeoxyglucose PET/CT. *Ugeskr Laeger* 2017;179. pii: V12160893.
4. Guth S, Theune U, Aberle J, Galach A, Bamberger CM. Very high prevalence of thyroid nodules detected by high frequency (13 MHz) ultrasound examination. *Eur J Clin Invest* 2009;39:699-706.
5. Tomimori E, Pedrinola F, Cavaliere H, Knobel M, Medeiros-Neto G.



- Prevalence of incidental thyroid disease in a relatively low iodine intake area. *Thyroid* 1995;5:273-6.
6. Ezzat S, Sarti DA, Cain DR, Braunstein GD. Thyroid incidentalomas. Prevalence by palpation and ultrasonography. *Arch Intern Med* 1994;154:1838-40.
  7. Liu Y, Ghesani NV, Zuckier LS. Physiology and pathophysiology of incidental findings detected on FDG-PET scintigraphy. *Semin Nucl Med* 2010;40:294-315.
  8. Demir Ö, Köse N, Özkan E, Ünlütürk U, Aras G, Erdoğan MF. Clinical significance of thyroid incidentalomas identified by 18F-FDG PET/CT: Correlation of ultrasonography findings with cytology results. *Nucl Med Commun* 2016;37:715-20.
  9. Soelberg KK, Bonnema SJ, Brix TH, Hegedüs L. Risk of malignancy in thyroid incidentalomas detected by 18F-fluorodeoxyglucose positron emission tomography: A systematic review. *Thyroid* 2012;22:918-25.
  10. Shie P, Cardarelli R, Sprawls K, Fulda KG, Taur A. Systematic review: Prevalence of malignant incidental thyroid nodules identified on fluorine-18 fluorodeoxyglucose positron emission tomography. *Nucl Med Commun* 2009;30:742-8.
  11. Kang KW, Kim SK, Kang HS, Lee ES, Sim JS, Lee IG, *et al.* Prevalence and risk of cancer of focal thyroid incidentaloma identified by 18F-fluorodeoxyglucose positron emission tomography for metastasis evaluation and cancer screening in healthy subjects. *J Clin Endocrinol Metab* 2003;88:4100-4.
  12. Are C, Hsu JF, Schoder H, Shah JP, Larson SM, Saha AR. FDG-PET detected thyroid incidentalomas: Need for further investigation? *Ann Surg Oncol* 2007;14:239-47.
  13. Hagenimana N, Dallaire J, Vallée É, Belzile M. Thyroid incidentalomas on 18FDG-PET/CT: A metabolic-pathological correlation. *J Otolaryngol Head Neck Surg* 2017;46:22.
  14. Gavriel H, Tang A, Eviatar E, Chan SW. Unfolding the role of PET FDG scan in the management of thyroid incidentaloma in cancer patients. *Eur Arch Otorhinolaryngol* 2015;272:1763-8.
  15. Kim TY, Kim WB, Ryu JS, Gong G, Hong SJ, Shong YK. 18F-fluorodeoxyglucose uptake in thyroid from positron emission tomogram (PET) for evaluation in cancer patients: High prevalence of malignancy in thyroid PET incidentaloma. *Laryngoscope* 2005;115:1074-8.
  16. Vaish R, Venkatesh R, Chaukar DA, Deshmukh AD, Purandare NC, D'cruz AK. Positron emission tomography thyroid incidentaloma: Is it different in Indian subcontinent? *Indian J Cancer* 2016;53:186-9.
  17. Achury C, Estorch M, Domènech A, Camacho V, Flotats A, Jaller R, *et al.* Interpretation of thyroid incidentalomas in (18)F-FDG PET/CT studies. *Rev Esp Med Nucl Imagen Mol* 2014;33:205-9.
  18. Elzein S, Ahmed A, Lorenz E, Balasubramanian SP. Thyroid incidentalomas on PET imaging – Evaluation of management and clinical outcomes. *Surgeon* 2015;13:116-20.
  19. Nayan S, Ramakrishna J, Gupta MK. The proportion of malignancy in incidental thyroid lesions on 18-FDG PET study: A systematic review and meta-analysis. *Otolaryngol Head Neck Surg* 2014;151:190-200.
  20. Pattison DA, Bozin M, Gorelik A, Hofman MS, Hicks RJ, Skandarajah A. 18F-FDG-avid thyroid incidentalomas: The importance of contextual interpretation. *J Nucl Med* 2018;59:749-55.
  21. Gedberg N, Karmisholt J, Gade M, Fisker RV, Iyer V, Petersen LJ. The frequency of focal thyroid incidental findings and risk of malignancy detected by 18F-fluorodeoxyglucose positron emission tomography in an iodine deficient population. *Diagnostics (Basel)* 2018;8. pii: E46.
  22. Schönberger J, Rüschoff J, Grimm D, Marienhagen J, Rümmele P, Meyringer R, *et al.* Glucose transporter 1 gene expression is related to thyroid neoplasms with an unfavorable prognosis: An immunohistochemical study. *Thyroid* 2002;12:747-54.
  23. Sager S, Vatankulu B, Sahin OE, Cımaral F, Uslu L, Baran A, *et al.* Clinical significance of standardized uptake values in thyroid incidentaloma discovered by F-18 fluorodeoxyglucose positron emission tomography/computed tomography. *J Cancer Res Ther* 2018;14:989-93.
  24. Brindle R, Mullan D, Yap BK, Gandhi A. Thyroid incidentalomas discovered on positron emission tomography CT scanning – Malignancy rate and significance of standardised uptake values. *Eur J Surg Oncol* 2014;40:1528-32.
  25. Bertagna F, Treglia G, Piccardo A, Giovannini E, Bosio G, Biasiotto G, *et al.* F18-FDG-PET/CT thyroid incidentalomas: A wide retrospective analysis in three Italian centres on the significance of focal uptake and SUV value. *Endocrine* 2013;43:678-85.
  26. Şencan Eren M, Özdoğan Ö, Gedik A, Ceylan M, Güray Durak M, Seçil M, *et al.* The incidence of 18F-FDG PET/CT thyroid incidentalomas and the prevalence of malignancy: A prospective study. *Turk J Med Sci* 2016;46:840-7.
  27. Chun AR, Jo HM, Lee SH, Chun HW, Park JM, Kim KJ, *et al.* Risk of malignancy in thyroid incidentalomas identified by fluorodeoxyglucose-positron emission tomography. *Endocrinol Metab (Seoul)* 2015;30:71-7.
  28. Yang Z, Shi W, Zhu B, Hu S, Zhang Y, Wang M, *et al.* Prevalence and risk of cancer of thyroid incidentaloma identified by fluorine-18 fluorodeoxyglucose positron emission tomography/computed tomography. *J Otolaryngol Head Neck Surg* 2012;41:327-33.
  29. Marques P, Ratão P, Salgado L, Bugalho MJ. Thyroid carcinoma detected by 18F-fluorodeoxyglucose positron emission tomography among individuals without prior evidence of thyroid disease: Relevance and clinicopathologic features. *Endocr Pract* 2014;20:1129-36.
  30. Yoon JH, Cho A, Lee HS, Kim EK, Moon HJ, Kwak JY. Thyroid incidentalomas detected on 18F-fluorodeoxyglucose-positron emission tomography/computed tomography: Thyroid imaging reporting and data system (TIRADS) in the diagnosis and management of patients. *Surgery* 2015;158:1314-22.
  31. Choi JS, Choi Y, Kim EK, Yoon JH, Youk JH, Han KH, *et al.* A risk-adapted approach using US features and FNA results in the management of thyroid incidentalomas identified by 18F-FDG PET. *Ultraschall Med* 2014;35:51-8.