

## Original Article

# The findings of $^{18}\text{F}$ -fluorodeoxyglucose positron emission tomography–computed tomography scan in patients with hidradenitis suppurativa in Malaysia: A multicenter study

## ABSTRACT

Hidradenitis suppurativa (HS) is known to have association with systemic diseases with chronic inflammation such as psoriasis. We aim to describe the concomitant systemic inflammation in patients with HS using  $^{18}\text{F}$ -fluorodeoxyglucose positron emission tomography–computed tomography ( $^{18}\text{F}$ -FDG PET/CT) scan. This was a case–control study conducted in three tertiary hospitals in Northern Malaysia from January to December 2017, involving HS patients aged 18 years and above. Thirty-two HS patients with age- and sex-matched controls were recruited with a mean age of 31.4 years (range: 18–56). Numerous cutaneous inflammatory foci were detected on FDG-PET/CT scan in clinically unapparent sites (27/32, 84.4%). Approximately 90.6%, 93.8%, and 50.0% of the patients had significantly higher cutaneous uptake over nasal, mandibular, and scalp regions, respectively ( $P < 0.0001$ ). PET/CT scan did not detect any systemic inflammation unlike those found in psoriasis. Three (9.4%) patients had thyroid nodules with high uptake (maximum standard uptake values ranging from 2.9 to 11.3). Two of them were confirmed to have papillary thyroid carcinoma, while the third patient has inconclusive finding.  $^{18}\text{F}$ -FDG PET/CT scan may be useful to map disease burden of HS. Nonlesional inflammatory foci on the skin of the nose, mandibular, and scalp are probably significant. The association of thyroid carcinoma in HS warrants further evaluation.

**Keywords:** Hidradenitis suppurativa, imaging, Malaysia, positron emission tomography–computed tomography scan, thyroid carcinoma

## INTRODUCTION

Hidradenitis suppurativa (HS) is a chronic inflammatory disease of the pilosebaceous follicle, occurring in genetically susceptible individuals with immune dysregulation. It is associated with metabolic syndrome, autoimmune diseases, and malignancies.<sup>[1–4]</sup> Although positron emission tomography–computed tomography (PET-CT) imaging is most commonly used in the oncology setting, it is also useful in nononcological setting such as the cardiac and brain imaging. The high sensitivity of  $^{18}\text{F}$ -FDG PET/CT in detecting cellular inflammation in tissues and early atherosclerosis is well demonstrated.<sup>[5,6]</sup> Mehta *et al.* demonstrated that patients with psoriasis have increased vascular inflammation in multiple aortic segments as well as increased hepatic inflammation based on  $^{18}\text{F}$ -FDG PET/CT though it is not significant after being adjusted for alcohol intake.<sup>[6]</sup> As HS is

associated with systemic diseases with chronic inflammation such as psoriasis, we postulate that the use of  $^{18}\text{F}$ -FDG

**CHAI HAR LOO<sup>1,2</sup>, ALEX CHEEN HOE KHOO<sup>3</sup>,  
WOOI CHIANG TAN<sup>2</sup>, YEK HUAN KHOR<sup>2</sup>,  
JYH JONG TANG<sup>4</sup>, MIN MOON TANG<sup>1</sup>, LEE CHIN CHAN<sup>2</sup>**

<sup>1</sup>Department of Dermatology, Hospital Kuala Lumpur, Kuala Lumpur, <sup>2</sup>Department of Dermatology, Hospital Pulau Pinang, <sup>3</sup>Department of Nuclear Medicine, Hospital Adventist, Penang, <sup>4</sup>Department of Dermatology, Hospital Raja Permaisuri Bainun, Ipoh, Malaysia


**Address for correspondence:** Dr. Chai Har Loo, Department of Dermatology, Hospital Pulau Pinang, Jalan Residensi, 10990 Pulau Pinang, Malaysia.  
E-mail: chaihhar@gmail.com

**Submitted:** 05-Apr-2020, **Revised:** 27-May-2020,  
**Accepted:** 26-Jun-2020, **Published:** 22-Aug-2020

This is an open access journal, and articles are distributed under the terms of the Creative Commons Attribution-NonCommercial-ShareAlike 4.0 License, which allows others to remix, tweak, and build upon the work non-commercially, as long as appropriate credit is given and the new creations are licensed under the identical terms.

**For reprints contact:** WKHLRPMedknow\_reprints@wolterskluwer.com

**How to cite this article:** Loo CH, Khoo AC, Tan WC, Khor YH, Tang JJ, Tang MM, *et al.* The findings of  $^{18}\text{F}$ -fluorodeoxyglucose positron emission tomography–computed tomography scan in patients with hidradenitis suppurativa in Malaysia: A multicenter study. *World J Nucl Med* 2021;20:32-7.

Access this article online	
<b>Website:</b> www.wjnm.org	<b>Quick Response Code</b> 
<b>DOI:</b> 10.4103/wjnm.WJNM_33_20	

PET/CT scan might assist in the identification of systemic inflammation in HS patients. Hence, our objective is to determine the role of  $^{18}\text{F}$ -FDG PET/CT scan in HS.

## MATERIALS AND METHODS

This was a substudy of a case–control, multicenter study conducted in three tertiary hospitals (Hospital Pulau Pinang in Penang, Hospital Sultanah Bahiyah in Kedah, and Hospital Raja Permaisuri Bainun in Perak) in Northern Peninsular Malaysia from January 2017 to December 2017. We enrolled HS patients regardless of their disease severity aged 18 years and above, who had volunteered and consented for  $^{18}\text{F}$ -FDG PET/CT scan. The FDG-PET/CT scan was subsequently performed in Hospital Pulau Pinang and reported by single-blinded nuclear medicine physician. The scan was done from the head to toes and maximum standard uptake values (SUV<sub>max</sub>) were measured. As there was no previous  $^{18}\text{F}$ -fluorodeoxyglucose PET-CT ( $^{18}\text{F}$ -FDG PET-CT) study of similar nature, the nuclear medicine physician decided to adopt visual interpretation guide similar to that of Deauville 5-Point Score in the imaging of lymphoma. The interpreting nuclear medicine physician uses SUV<sub>max</sub> in the mediastinum and liver as reference organs with the scale ranging from 1 to 5. The “lesion” was defined as any abnormality either detected on CT or PET. Each of the lesions is scored independently. Point 1 and Point 2 are scored for “visualized lesions on CT” with no uptake and slight uptake but below mediastinum blood pool uptake, respectively. Point 3 is scored when the ‘lesional’ uptake is above mediastinum but below or equal to uptake in the liver.

Point 4 and Point 5 are scored when the ‘lesional’ uptake is slightly moderately higher than liver and markedly increased uptake or any new lesion (subjectively set to at least 3x higher than the liver), respectively. Any non-physiological unexplained (not due to known trauma or infection) skin uptake of  $^{18}\text{F}$ -FDG was considered new “active” lesion based on scan findings. Subsequently, age- and sex-matched controls comprising nuclear medicine patients of unrelated diseases without cutaneous involvement were selected (1:1 ratio). Hurley staging was used for grading the disease severity. Inflammatory markers such as high-sensitivity C-reactive protein (hs-CRP) and total white cell count with absolute neutrophil count were measured. Ethics approval was obtained through Malaysia Medical Research and Ethics Committee (NMRR-16-727-30616, 8 September 2016).

## RESULTS

### Demographic and clinical characteristics

Thirty-two HS patients from the main study had  $^{18}\text{F}$ -FDG PET-CT scan done. Demographic characteristics of the study population and matched control are shown in Table 1. Their mean age was 31.4 years ( $\pm 10.97$ ) with a male preponderance (5:1). Two-third of the patients were Malays, followed by Indian (21.9%) and Chinese (9.3%). Positive family history of HS was found in 31.3% of the patients. The median age of onset was at 18 years with median disease duration at 7.5 years ( $\pm 11.0$ , range: 1–29 years). Among these patients, 37.5% ( $n = 12$ ) were obese and 34.4% ( $n = 11$ ) were overweight. Eighteen patients (56.3%) were either

**Table 1: Demographic characteristics of 32 patients with hidradenitis suppurativa and age-, sex-matched controls**

Characteristics	Case ( $n=32$ )	Control ( $n=32$ )
Mean age, years (range)	31.4 (18-56)	32.8 (18-58)
Median age of onset, year (range)	18.0 (12-56)	
Median delay in diagnosis, years (range)	4.5 (0-29)	
Median disease duration (range)	7.0 (1-29)	
Male:female	5:1	5:1
Ethnicity, $n$ (%)		
Malay	22 (68.8)	18 (56.3)
Chinese	3 (9.3)	12 (37.5)
Indian	7 (21.9)	2 (6.2)
BMI ( $\text{kg}/\text{m}^2$ ), $n$ (%)		
Obesity ( $\geq 27.5$ )	12 (37.5)	
Overweight (23-27.4)	11 (34.4)	
Normal (18.5-22.9)	5 (15.6)	
Underweight ( $< 18.5$ )	4 (12.5)	
Metabolic syndrome, $n$ (%)	7 (21.9)	
Disease severity (Hurley staging), $n$ (%)		
Stage I	5 (15.6)	
Stage II	19 (59.4)	
Stage III	8 (25.0)	
Median hs-CRP, mg/L, (IQR)	8.0 (16.93) (range: 0.62-100.7)	

hs-CRP: High-sensitivity c-reactive protein; IQR: Interquartile range; BMI: Body mass index

active or former smokers. About 21.9% ( $n = 7$ ) of patients had metabolic syndrome based on the National Cholesterol Education Program criteria. Based on Hurley staging, 15.6% ( $n = 5$ ) in Hurley Stage I, 59.4% ( $n = 19$ ) in Hurley Stage II, and 25.0% ( $n = 8$ ) in Hurley Stage III. The median hs-CRP was 8.0 mg/l ( $\pm 16.9$ , range: 0.62 mg/l– 100.70 mg/l), while the mean of total white cell count and absolute neutrophil count were  $10.4 \times 10^6/l$  ( $\pm 3.22$ ) and  $6.6 \times 10^6/l$  ( $\pm 2.80$ ), respectively.

#### **<sup>18</sup>F-fluorodeoxyglucose positron emission tomography-computed tomography scan assessment**

Numerous inflammatory foci in the cutaneous–subcutaneous tissues were detected from <sup>18</sup>F-FDG PET/CT scan in clinically unapparent sites, totaling 27/32 cases (84.4%). Approximately 90.6%, 93.8%, and 50.0% of the patients had higher cutaneous uptake (range of SUV<sub>max</sub> of between 0.7 and 9.8) over the nasal, mandibular, and scalp, respectively, when compared to their own standardized uptake values (SUV<sub>max</sub>) of the liver and mediastinum. When compared with age- and sex-matched controls, those high uptakes were statistically significant ( $P < 0.0001$ ) [Table 2]. However, on physical examination, these patients did not have clinically visible skin lesions over those sites. No histopathological confirmation was performed for confirmation of these subclinical lesions. There was no systemic inflammation at the vasculature, musculoskeletal, cardiac, and liver.

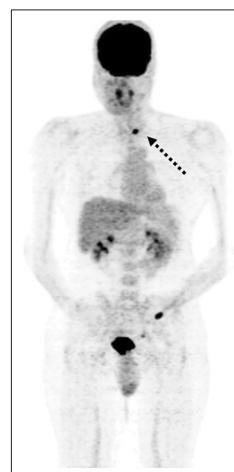Interestingly, three patients (9.4%) were detected to have high focal uptakes (SUV<sub>max</sub> ranging from 3.1 to 11.9) in the thyroid glands. Figure 1 shows a patient with high uptake at the thyroid gland. Further ultrasonography detected thyroid nodules for all three patients. Two patients (aged 21 and 44 years) were confirmed to have papillary thyroid carcinoma based on histopathological findings. SUV<sub>max</sub> detected over their thyroid glands was 11.3 and 11.9, respectively. Unfortunately, the third patient's biopsy sample was suboptimal and the patient refused for a repeat thyroid nodule sampling. SUV<sub>max</sub> detected at both his thyroid glands was 3.2 and 2.9. All of them had no obvious goiter and were biochemically euthyroid. Thyroid autoantibodies screening showed normal antithyroperoxidase level for all three

patients, while one of the two who had papillary thyroid carcinoma had a high antithyroglobulin antibody level at 156.48 IU/ml. Both patients underwent total thyroidectomy, while the third patient remained on close monitoring.

#### **DISCUSSION**

HS is a chronic autoinflammatory skin disease which greatly impacts one's life. Various imaging modalities have emerged to improve the diagnoses, disease severity assessment, and management of HS. The current imaging methods used for the study of HS are mainly focused on ultrasonography and magnetic resonance imaging (MRI). The utility of FDG-PET/CT studies in this disease remains uncommon. Ultrasonography can also be utilized as an adjunctive diagnostic tool with the proposed diagnostic criteria by Wortsman *et al.*,<sup>[7-9]</sup> whereas MRI was demonstrated to be an effective tool in assessing subclinical lesions especially over the anogenital regions in case reports.<sup>[10,11]</sup>

The role of <sup>18</sup>F-FDG PET/CT studies in HS remains unknown. Hypermetabolic and inflamed tissues are known to have higher <sup>18</sup>F-FDG uptake than the surrounding tissues due to increased glucose uptake and vascularity. The distribution of <sup>18</sup>F-FDG within the body would enable the clinicians to detect hypermetabolic tissues (especially cancer), infective and inflammatory conditions (e.g., vasculitis). Functional changes precede anatomical changes much earlier, and the detection of these changes enables clinicians to initiate treatment earlier. In our study, it was shown to detect subclinical skin lesions in up to 84.4% of patients with HS. Moreover, <sup>18</sup>F-FDG PET/CT is able to image the whole body in a single imaging session.<sup>[5]</sup> The identification of disease



**Figure 1:** <sup>18</sup>F-fluorodeoxyglucose positron emission tomography-computed tomography scan of *Hidradenitis suppurativa* patient. The maximal intensity projection of a 44 years-old Malay man showing high uptake (maximum standard uptake values: 11.9) within the left thyroid nodule (black arrow)– refer figure file

**Table 2:** <sup>18</sup>F-fluorodeoxyglucose positron emission tomography-computed tomography uptakes (maximum standard uptake values) compared with control

Sites	Case	Control	P
Nasal uptake, mean $\pm$ SD	4.3 $\pm$ 1.82	2.5 $\pm$ 1.17	<0.001*
Mandible uptake, median (IQR)	3.0 (1.28)	1.8 (0.67)	<0.001**
Scalp uptake, median (IQR)	2.2 (1.47)	1.6 (0.75)	0.001**
Thyroid uptake, median (IQR)	1.9 (0.68)	1.5 (0.68)	0.052

\*Independent t-test, \*\*Mann-Whitney test. SD: Standard deviation; IQR: Interquartile range

burden enables clinicians to plan their treatment accordingly. It helps determine the optimal timing in the initiation or escalation or deescalation of systemic therapy. For instance, a patient with extensive subclinical lesions (high disease burden) from FDG-PET/CT scan might require longer duration of systemic treatment or a more aggressive approach and to avoid premature tapering off of systemic treatment. Mapping of disease burden may be valuable in prognostication and early identification of individuals with potentially more severe disease with refractory disease course if cost is not a restricting factor.

We used visual interpretation as a guide in patient assessment in addition to  $SUV_{max}$  which is more objective, to facilitate comparison among patients. HS patients with liver impairment may impact the use of liver as one of our reference organs, but the data on this matter are rather limited.<sup>[12]</sup> Any discordance between  $SUV_{max}$  value and visual scoring can be easily detected and in actual clinical practice. Therefore, the nuclear medicine physician needs to be mindful to correlate visual interpretation using liver as a reference organ and objective interpretation ( $SUV_{max}$ ). None of our patients had evidence of liver inflammation, such as deranged liver function test or fatty liver, and therefore, we expect concordance between objective and visual interpretations.

To the best of our knowledge, this is the first case–control study using  $^{18}F$ -FDG PET/CT scan as an objective tool in assessing systemic inflammation in HS patients. There were only few case reports describing HS features on PET scan as an incidental finding noted during the staging of underlying malignancies.<sup>[13-15]</sup> In these studies, the hypermetabolic foci seen at subcutaneous tissues corresponded well with clinical HS. In recent years, new theories have been postulated on the pathogenesis of HS, which includes HS being an autoinflammatory disease.<sup>[16,17]</sup> Akiyama *et al.* have grouped the diseases with keratinization disorders with an underlying autoinflammatory pathogenesis as “autoinflammatory keratinization diseases” and HS is believed to be one of them.<sup>[18]</sup> Hence, theoretically, the ongoing subclinical inflammatory lesions would be detected by  $^{18}F$ -FDG PET/CT scan. In our study, there was an unexpectedly higher percentage of HS patients having a significantly higher cutaneous uptake over the nasal, mandibular, and scalp regions without clinical apparent disease compared with the matched controls ( $P < 0.0001$ ). Objective measurement of significantly higher FDG uptake in these nonlesional regions (where higher concentrations of folliculopilosebaceous units are found) confirms the ongoing subclinical inflammatory process. This supports

the hypothesis of overactivation of inflammatory drive or autoinflammatory pathogenesis in HS patients. In fact, Kelly and Cronin demonstrated the dysregulated cytokine expression could be presented in both lesional and nonlesional skin in HS patients.<sup>[19]</sup>

$^{18}F$ -FDG PET/CT scan in HS patients did not show any evidence of systemic inflammation unlike in patients with psoriasis where FDG uptake was seen in the skin, liver, joints, tendons, and aorta.<sup>[6]</sup> Uptakes were, however, seen in the skin and thyroid glands. One-fifth of HS patients (21.9%) suffered from metabolic syndrome, while more than two-third were overweight/obese with almost 85% of them had moderate-to-severe diseases with an elevated inflammatory marker (hs-CRP ranging from 0.62 mg/l up to as high as 100.70 mg/l with a median of 8.0 mg/l). However, no systemic inflammation was detected on  $^{18}F$ -FDG PET/CT scan. We postulate that systemic inflammation will probably occur but only after a prolonged duration. The study population was rather young with a mean age of 31.4 years and a longer period of follow-up with repeat PET-CT scan would be needed to evaluate the development of systemic inflammation.

The majority of our patients suffered from “atypical” type of HS with latent class 2 (LC2, follicular type) and latent class 3 (LC3, gluteal type) phenotypes, which did not have significant metabolic association as compared to the patients from the West.<sup>[20]</sup> Genetic heterogeneity in different races has been well depicted by Liu *et al.*<sup>[21]</sup> Differences in genetic background might explain the phenotypic discrepancies seen in our patients compared to those from the West, such as a male preponderance observed in this study. Unfortunately, there is no data on FDG-PET/CT scan in HS among the Western population. Furthermore, our previous published data demonstrated that the majority of our HS patients suffered from “atypical” type of HS with latent class 2 (LC2) and latent class 3 (LC3) phenotypes based on Canoui-Poitrine *et al.*<sup>[22]</sup> proposed classification. This atypical type of HS is more commonly seen among male patients. The increased  $^{18}F$ -FDG uptake over follicular regions such as nasal, mandibular, and scalp can be explained by the fact that most of our study patients had follicular-type HS (LC2)<sup>[22]</sup> and are exhibiting subclinical disease. Biopsy of these sites would be ideal for confirmation but were not done in this study as it was not part of the initial methodology. Systemic inflammation may not be seen in HS due to the non-identical underlying immune dysregulation and pathogenesis as compared to psoriasis. A longer period of follow-up would be ideal to observe if the aforementioned differences would eventually lead to systemic inflammation.

HS has been reported to be associated with various types of malignancies.<sup>[23-25]</sup> Nearly a tenth of our patients ( $n = 3$ ; 9.4%) were detected to have high <sup>18</sup>F-FDG focal uptake over the thyroid glands and 2 patients (6.3%) had confirmed papillary thyroid carcinoma. We detected higher prevalence of thyroid incidentaloma compared with other studies, which ranged from 0.8% to 4.3%.<sup>[26-29]</sup> Katz and Shaha named it as “PAIN phenomenon” which referred to PET-associated incidental neoplasm of thyroid in 2008.<sup>[30]</sup> The incidence of thyroid malignancy is high among PAIN phenomenon, especially in those with focal <sup>18</sup>F-FDG uptake. The malignancy rate ranged from 24% to 36% among these incidentalomas.<sup>[29,31,32]</sup> The most common reported malignancy was papillary thyroid cancer and this was similarly found in our study.<sup>[33,34]</sup> This novel finding of thyroid malignancy has not been highlighted in previous literatures on HS. Most studies reported the association of thyroid disorders in HS without alluding to thyroid malignancy.<sup>[23,35]</sup> A large-scale registry study by a Swedish group involving 2119 HS patients over 3 decades did not document any association with thyroid malignancy. This particular study, however, reported a 50% increased risk of all types of cancer in HS patients when compared with the matched controls, particularly for nonmelanoma skin cancer (5 cases; 4.6-fold increase risk), buccal cancer (5 cases), and primary liver cancer (3 cases).<sup>[36]</sup> The high percentage (9.4%) of thyroid nodules detection and high association of malignancy (66.7%) in this small group of patients with HS implies an important association that warrants further evaluation. We are unable to conclude if this is a true association between HS and thyroid malignancy or merely a coincidence due to our study’s small sample size. However, we believe that this association is worth exploring in future studies, as early detection of thyroid cancer might be curative or even prolong patient survival.

## CONCLUSION

There was no demonstrable systemic inflammation in HS such as psoriasis found in this study. However, <sup>18</sup>F-FDG PET-CT scan is useful to map disease burden, especially subclinical cutaneous sites for optimal treatment. The association between thyroid malignancy and HS patients found in this study needs further validation studies.

## Financial support and sponsorship

Nil.

## Conflicts of interest

There are no conflicts of interest.

## REFERENCES

- Miller IM, Ellervik C, Vinding GR, Zarchi K, Ibler KS, Knudsen KM, et al. Association of metabolic syndrome and hidradenitis suppurativa. *JAMA Dermatol* 2014;150:1273-80.
- Shalom G, Freud T, Harman-Boehm I, Polishchuk I, Cohen AD. Hidradenitis suppurativa and metabolic syndrome: A comparative cross-sectional study of 3207 patients. *Br J Dermatol* 2015;173:464-70.
- Crowley JJ, Mekkes JR, Zouboulis CC, Scheinfeld N, Kimball A, Sundaram M, et al. Association of hidradenitis suppurativa disease severity with increased risk for systemic comorbidities. *Br J Dermatol* 2014;171:1561-5.
- Gold DA, Reeder VJ, Mahan MG, Hamzavi IH. The prevalence of metabolic syndrome in patients with hidradenitis suppurativa. *J Am Acad Dermatol* 2014;70:699-703.
- Hess S, Hansson SH, Pedersen KT, Basu S, Høiland-Carlson PF. FDG-PET/CT in infectious and inflammatory diseases. *PET Clin* 2014;9:497-519, vi-vii.
- Mehta NN, Yu Y, Saboury B, Foroughi N, Krishnamoorthy P, Raper A, et al. Systemic and vascular inflammation in patients with moderate to severe psoriasis as measured by [<sup>18</sup>F]-fluorodeoxyglucose positron emission tomography-computed tomography (FDG-PET/CT): A pilot study. *Arch Dermatol* 2011;147:1031-9.
- Wortsman X, Moreno C, Soto R, Arellano J, Pezo C, Wortsman J. Ultrasound in-depth characterization and staging of hidradenitis suppurativa. *Dermatol Surg* 2013;39:1835-42.
- Wortsman X. Imaging of hidradenitis suppurativa. *Dermatol Clin* 2016;34:59-68.
- Wortsman X, Wortsman J. Clinical usefulness of variable-frequency ultrasound in localized lesions of the skin. *J Am Acad Dermatol* 2010;62:247-56.
- Griffin N, Williams AB, Anderson S, Irving PM, Sanderson J, Desai N, et al. Hidradenitis suppurativa: MRI features in anogenital disease. *Dis Colon Rectum* 2014;57:762-71.
- Kelly AM, Cronin P. MRI features of hidradenitis suppurativa and review of the literature. *AJR Am J Roentgenol* 2005;185:1201-4.
- Salomon T, Nganoa C, Gac AC, Fruchart C, Damaj G, Aide N, et al. Assessment of alteration in liver <sup>18</sup>F-FDG uptake due to steatosis in lymphoma patients and its impact on the Deauville score. *Eur J Nucl Med Mol Imaging* 2018;45:941-50.
- Simpson RC, Dyer MJ, Entwisle J, Harman KE. Positron emission tomography features of hidradenitis suppurativa. *Br J Radiol* 2011;84:e164-5.
- Asamoah P, Wale DJ, Viglianti BL, Wong KK, Gross M. Multiple hypermetabolic subcutaneous lesions from hidradenitis suppurativa mimicking metastases on <sup>18</sup>F-FDG PET/CT. *Clin Nucl Med* 2018;43:73-4.
- Poh F, Wong SK. Imaging of hidradenitis suppurativa and its complications. *Case Rep Radiol* 2014;2014:294753.
- Vinkel C, Thomsen SF. Autoinflammatory syndromes associated with hidradenitis suppurativa and/or acne. *Int J Dermatol* 2017;56:811-8.
- De Vita V, McGonagle D. Hidradenitis suppurativa as an autoinflammatory keratinization disease. *J Allergy Clin Immunol* 2018;141:1953.
- Akiyama M, Takeichi T, McGrath JA, Sugiura K. Autoinflammatory keratinization disease. *J Allergy Clin Immunol* 2017;140:1545-7.
- Kelly G, Hughes R, McGarry T, van den Born M, Adamzik K, Fitzgerald R, et al. Dysregulated cytokine expression in lesional and nonlesional skin in hidradenitis suppurativa. *Br J Dermatol* 2015;173:1431-9.
- Loo CH, Tan WC, Tang JJ, Khor YH, Manikam MT, Low DE, et al. The clinical, biochemical, and ultrasonographic characteristics of patients with hidradenitis suppurativa in Northern Peninsular Malaysia: A multicenter study. *Int J Dermatol* 2018;57:1454-63.
- Liu M, Davis JW, Idler KB, Mostafa NM, Okun MM, Waring JF. Genetic analysis of NCSTN for potential association with hidradenitis suppurativa in familial and nonfamilial patients. *Br J Dermatol* 2016;175:414-6.
- Canoui-Poitrine F, Le Thuaut A, Revuz JE, Viallette C, Gabison G,

- Poli F, *et al.* Identification of three hidradenitis suppurativa phenotypes: Latent class analysis of a cross-sectional study. *J Invest Dermatol* 2013;133:1506-11.
23. Shlyankevich J, Chen AJ, Kim GE, Kimball AB. Hidradenitis suppurativa is a systemic disease with substantial comorbidity burden: A chart-verified case-control analysis. *J Am Acad Dermatol* 2014;71:1144-50.
  24. Makris GM, Poulakaki N, Papanota AM, Kotsifa E, Sergentanis TN, Psaltopoulou T. Vulvar, perianal and perineal cancer after hidradenitis suppurativa: A systematic review and pooled analysis. *Dermatol Surg* 2017;43:107-15.
  25. Sotoodian B, Abbas M, Brassard A. Hidradenitis suppurativa and the association with hematological malignancies. *J Cutan Med Surg* 2017;21:158-61.
  26. Kang KW, Kim SK, Kang HS, Lee ES, Sim JS, Lee IG, *et al.* Prevalence and risk of cancer of focal thyroid incidentaloma identified by 18F-fluorodeoxyglucose positron emission tomography for metastasis evaluation and cancer screening in healthy subjects. *J Clin Endocrinol Metab* 2003;88:4100-4.
  27. Choi JY, Lee KS, Kim HJ, Shim YM, Kwon OJ, Park K, *et al.* Focal thyroid lesions incidentally identified by integrated 18F-FDG PET/CT: Clinical significance and improved characterization. *J Nucl Med* 2006;47:609-15.
  28. Flukes S, Lenzo N, Moschilla G, Sader C. Positron emission tomography-positive thyroid nodules: Rate of malignancy and histological features. *ANZ J Surg* 2016;86:487-91.
  29. Bertagna F, Treglia G, Piccardo A, Giubbini R. Diagnostic and clinical significance of F-18-FDG-PET/CT thyroid incidentalomas. *J Clin Endocrinol Metab* 2012;97:3866-75.
  30. Katz SC, Shaha A. PET-associated incidental neoplasms of the thyroid. *J Am Coll Surg* 2008;207:259-64.
  31. Cohen MS, Arslan N, Dehdashti F, Doherty GM, Lairmore TC, Brunt LM, *et al.* Risk of malignancy in thyroid incidentalomas identified by fluorodeoxyglucose-positron emission tomography. *Surgery* 2001;130:941-6.
  32. Sheikhabaehi S, Marcus C, Subramaniam RM. 18F FDG PET/CT and Head and Neck Cancer: Patient Management and Outcomes. *PET Clin* 2015;10:125-45.
  33. Kaliszewski K, Strutyńska-Karpińska M, Zubkiewicz-Kucharska A, Wojtczak B, Domosławski P, Balcerzak W, *et al.* Should the prevalence of incidental thyroid cancer determine the extent of surgery in multinodular goiter? *PLoS One* 2016;11:e0168654.
  34. Kaliszewski K, Diakowska D, Ziętek M, Knychalski B, Aporowicz M, Sutkowski K, *et al.* Thyroid incidentaloma as a “PAIN” phenomenon- does it always require surgery? *Medicine (Baltimore)* 2018;97:e13339.
  35. Chiricozzi A, Giovanardi G, Caro DR, Iannone M, De Simone C, Cannizzaro MV, *et al.* Characterization of comorbid conditions burdening hidradenitis suppurativa: A multicentric observational study. *G Ital Dermatol Venereol* 2020;155:335-40.
  36. Lapins J, Ye W, Nyrén O, Emtestam L. Incidence of cancer among patients with hidradenitis suppurativa. *Arch Dermatol* 2001;137:730-4.