

Case Report

Breast uptake on a myocardial perfusion scan

ABSTRACT

A 42-year-old female underwent a myocardial perfusion scan (MPS) for the evaluation of coronary artery disease. Raw and cine loop images hinted at abnormal tracer accumulation in the chest. Review of short-axis slices and low-dose computed tomography images taken for attenuation correction and their subsequent fusion confirmed the presence of focal tracer uptake localized to nodular breast masses. This case demonstrates that despite MPS not being optimized to detect breast pathologies, careful inspection of unprocessed images and the application of available software for fusion can help detect concurrent pathology.

Keywords: Breast, incidental findings, myocardial perfusion scan, technetium-99m sestamibi

INTRODUCTION

Technetium-99m (^{99m}Tc) sestamibi is widely used as a tracer for myocardial perfusion scintigraphy (MPS). Due to its affinity to tumors, it is also used to image neoplasms in the thyroid and parathyroid glands, breasts, lungs, kidneys, and bones.^[1] Approximately 0.68%–1.7% of myocardial perfusion scintigrams have noncardiac findings of varying importance, including tumors.^[2,3] Low-dose computed tomography (CT), acquired routinely for attenuation correction,^[4] facilitates anatomic correlation.

This is a case of abnormal breast uptake in a patient referred for the evaluation of coronary artery disease (CAD). The case highlights the importance of reviewing the raw images and low-dose CT images to detect concurrent pathologies.

CASE REPORT

A 42-year-old female was sent for a dipyridamole-sestamibi MPS. She was being treated at a local hospital for uncontrolled hypertension and typical angina.

She underwent a 1-day low-dose rest and high-dose stress protocol MPS. An initial resting study was done 60 min after intravenous injection of 282 MBq of ^{99m}Tc -sestamibi. She was given 31.8 mg of dipyridamole intravenously over 4 min,


followed by 705 MBq of ^{99m}Tc -sestamibi. Stress images were obtained 30 min after the second radiotracer injection. Dipyridamole and both doses of ^{99m}Tc -sestamibi were given via an intravenous catheter placed in the dorsum of her right hand. A dual-head GE Discovery NM/CT 670 Camera (GE Healthcare, Waukesha, WI) was used to obtain a 180° (45° RAO to 45° LPO) dataset using low-energy high-resolution parallel-hole collimators. Sixty-four projections were acquired for 25 and 20 s at rest and stress, respectively. The photo-peak was set at 140 keV with a 20% symmetrical window. A low-dose CT scan (helical, 140 keV, 10 mAs with 1.9 pitch, 5 mm slices) from the level of the sternomanubrial joint to below the xiphoid process was done for attenuation correction. All images were obtained with the patient positioned supine, arms raised and breasts taped down to the chest. Single-photon emission computed tomography (SPECT)

CRISTINA CUARESMA MORALES¹,
ANGELIN FRAGANTE APOSTOL^{1,2}

¹Nuclear Medicine Division, Philippine Heart Center, ²Nuclear Medicine Section, Lung Center of the Philippines, Quezon City, Philippines

Address for correspondence: Dr. Cristina Cuaresma Morales, Nuclear Medicine Division, Philippine Heart Center, Pagbubungkos Plaza, East Avenue, Quezon City 1100, Philippines.
E-mail: cristina.cuaresma.morales@gmail.com

Submitted: 25-Mar-2020, **Revised:** 7-May-2020,
Accepted: 25-May-2020, **Published:** 14-Sep-2020

Access this article online	
Website: www.wjnm.org	Quick Response Code 
DOI: 10.4103/wjnm.WJNM_35_20	

This is an open access journal, and articles are distributed under the terms of the Creative Commons Attribution-NonCommercial-ShareAlike 4.0 License, which allows others to remix, tweak, and build upon the work non-commercially, as long as appropriate credit is given and the new creations are licensed under the identical terms.

For reprints contact: WKHLRPMedknow_reprints@wolterskluwer.com

How to cite this article: Morales CC, Apostol AF. Breast uptake on a myocardial perfusion scan. World J Nucl Med 2021;20:105-8.

datasets were processed using the Evolution application in the Xeleris 4.0 Workstation (GE Healthcare, Waukesha, WI, USA).

There was a large, partially reversible defect in the basal to apical lateral and apical anterior left ventricular (LV) myocardial segments and apex [Figure 1], with associated reduced wall motion and systolic thickening. This was consistent with near-total occlusion of the left circumflex artery demonstrated on subsequent invasive coronary angiography.

Raw and cine loop images showed a focus of increased tracer accumulation on the right chest [Figure 2]. Short-axis slices confirmed the sestamibi-avid focus on the right, as well as milder and more diffuse uptake on the left, anterior-anterolateral to the LV myocardium [Figure 3]. Review of CT images showed bilateral nodular breast lesions. No focal tracer accumulation was seen in the medial, lateral, and superior borders of either breast. No adenopathies in the internal mammary and level I axillary lymph node chains were resolved by CT. Using the Volumetrix MI application

in the Xeleris 4.0 workstation, fusion of the SPECT and CT datasets showed that the foci of tracer accumulation localized to these breast masses. The largest and most sestamibi-avid nodule was found in the upper outer quadrant of the right breast with a tumor-to-background ratio of 5.6. Subsequent physical examination of the patient confirmed the presence of said lesions.

DISCUSSION

^{99m}Tc-sestamibi is widely used in the evaluation of CAD. It is taken up by myocytes in proportion to blood flow and binds to mitochondria. Likewise, increased blood flow and mitochondrial fraction in tumors allow sestamibi to concentrate inside living tumor cells.^[1]

While scintigraphic procedures for myocardial perfusion and breasts both use the same tracer, acquisition and processing of the images differ in important ways. In MPS, up to 370 MBq is given at rest and another dose up to 1100 MBq is given after a stressor, such as dipyridamole. The supine patient is




Figure 1: Myocardial scan showing severely reduced tracer uptake in the inferior and inferolateral segments after dipyridamole infusion. Rest images showing significant but incomplete improvement in these segments. Interfering activity inferior to the left ventricle is also appreciated

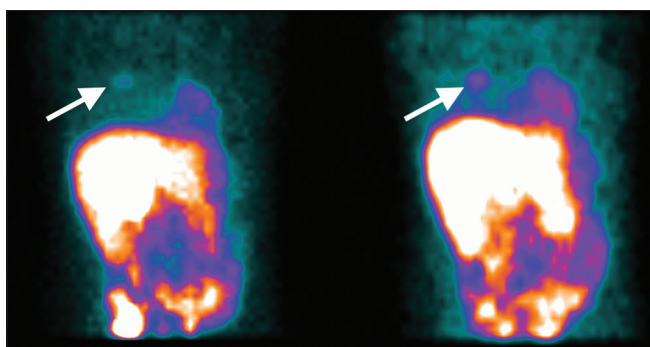


Figure 2: Focal tracer uptake is seen in the right anterior chest. Tumor-to-background ratio at rest (right) is 5.6, marginally higher than 5.1 taken poststress. Possible explanations include greater myocardial tracer extraction after dipyridamole infusion with consequently decreased tracer available to the tumor, and increased uptake time in the rest image protocol allowed for greater lesion tracer accumulation against increased background washout

imaged with the arms raised.^[4] In scintimammography with a general-purpose camera, 740–1110 MBq of ^{99m}Tc -sestamibi is given intravenously. Planar lateral and oblique images are obtained 5-15 minutes after tracer administration. During imaging, the patient is positioned prone on a mattress with cut-outs to allow the breasts to hang freely. This position improves resolution by decreasing the distance between the breasts and the camera while at the same time increasing the distance of the breasts from the myocardium and from the liver. The patient is repositioned to lie supine and an additional planar anterior image is then acquired. This image allows for better visualization of the primary lesion and for assessment of the internal mammary and axillary lymph node chains. The energy window is centered at 140 keV with its width reduced to 10% from 20%, to avoid shine-through artifacts when getting lateral images. Differences in protocols explain why images obtained for myocardial perfusion do not characterize breast lesions to the level of detail that scintimammography does.^[5]

The use of SPECT with or without low-dose CT in scintimammography is controversial. Planar images are more specific, but the addition of SPECT increases the ability to detect lesions by improving the lesion-to-background ratio, by removing overlying activity from adjacent slices, and by generating a three-dimensional maximum-intensity projection for improved localization.^[5] Localization and anatomic characterization are further enhanced with the addition of CT imaging and by subsequent fusion with SPECT using software.^[5]

In this case, SPECT and CT were invaluable. Acquisition of additional planar images was not feasible. Review of existing images and reprocessing were done instead. SPECT and review of short-axis slices confirmed the presence of tracer accumulation in the breasts, excluding the possibility that these foci of tracer accumulation merely represented

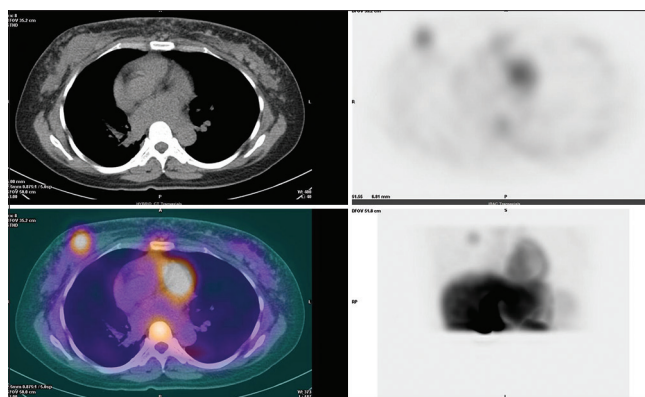


Figure 3: (a) Low-dose computed tomography images provide adequate anatomic detail on the nodular masses seen in both breasts. (b) An axial slice taken from the single-photon emission computed tomography data set shows a dense focus of tracer accumulation and another less intense and more diffuse area of uptake in the right and left breasts, respectively. (c) The fused images showed that the breast masses are sestamibi-avid, with the right tumor showing greater uptake. Sternal uptake is at the same level as that in the vertebral body. (d) The maximum intensity projection is a three-dimensional rendering of the single-photon emission computed tomography dataset

contamination or extravasation with subsequent transit into lymph nodes. The uptake in the left breast became more evident after being isolated from the intense myocardial uptake. CT provided anatomic correlates of nodular breast lesions to which the tracer localized. Thus, review and subsequent fusion of the SPECT and CT datasets using software different from the myocardial perfusion application allowed for the detection of malignant-looking breast masses.

The field of view of the CT images neither included the axillary lymph node chain nor resolved the internal mammary lymph node chain. Even with fusion, the assessment of the aforementioned lymph node chains could not be done. This could have been accomplished by scintimammography or, arguably, if an additional planar anterior image was obtained.

CONCLUSION

This is a case of abnormal uptake in the breasts of a patient referred for the evaluation of CAD. Careful review of raw SPECT and low-dose CT images and their subsequent fusion led to the detection and characterization of worrisome breast pathology.

Declaration of patient consent

The authors certify that they have obtained all appropriate patient consent forms. In the form the patient(s) has/have given his/her/their consent for his/her/their images and other clinical information to be reported in the journal. The patients understand that their names and initials will not be published and due efforts will be made to conceal their identity, but anonymity cannot be guaranteed.

Acknowledgment

We acknowledge the support of our research mentor, Dr. Jerry M. Obaldo, and the radiologic, cardiologic, and technical inputs of Dr. Irene Bandong, Dr. Emily Yap, Dr. Donald Palma, Mr. Romuald Tiangco, and Mr. Alvin Villalon.

Financial support and sponsorship

Nil.

Conflicts of interest

There are no conflicts of interest.

REFERENCES

1. Mohr WW, Gibson DL, Pang W. Extra-cardiac uptake of technetium-99m-MIBI: Normal and abnormal variants. *J Nucl Med Tech* 1996;2:104-11.
2. Williams KA, Hill KA, Sheridan CM. Noncardiac findings on dual-isotope myocardial perfusion SPECT. *J Nucl Cardiol* 2003;10:395-402.
3. Greene LR, Wilkinson D. The role of general nuclear medicine in breast cancer. *J Med Radiat Sci* 2015;62:54-65.
4. Dorbala S, Di Carli MF, Delbeke D, Abbara S, DePuey EG, Dilsizian V, *et al.* SNMMI/ASNC/SCCT guideline for cardiac SPECT/CT and PET/CT 1.0. *J Nucl Med* 2013;54:1485-507.
5. Schillaci O, Danieli R, Filippi L, Romano P, Cossu E, Manni C, *et al.* Scintimammography with a hybrid SPECT/CT imaging system. *Anticancer Res* 2007;27:557-62.