

Case Report

Vertebral uptake of ^{99m}Tc -macroaggregated albumin during lung perfusion scanning

ABSTRACT

A 53-year-old female underwent a lung ventilation/perfusion scintigraphy (V/Q scan) in the workup of extensive thrombosis of the left subclavian and internal jugular veins. The perfusion lung scan visualized an atypical uptake in the thoracic vertebrae. A chest Computed Tomography (CT) scan demonstrated unusual tortuous and opacified thoracic superficial veins, collaterals of the lateral thoracic vein. Many venous collateral pathways can be developed in the case of superior vena cava syndrome. ^{99m}Tc -macroaggregated albumin particles may pass through the lateral thoracic vein and eventually through the vertebral venous plexus before being finally trapped by the vertebral capillaries. Besides right-to-left shunting, extrapulmonary uptake in the lung perfusion scintigraphy is very rare and may be used by collateral venous pathways.

Keywords: Collateral pathways, lung perfusion scan, superior vena cava syndrome, vertebral uptake

INTRODUCTION

Perfusion lung scintigraphy using ^{99m}Tc -macroaggregated albumin (^{99m}Tc -MAA) is an important diagnostic tool for pulmonary embolism (PE). In case of PE, the embolus blocks the blood flow and causes a typical segmental perfusion defect with a normal ventilation using the V/Q scan.^[1] All ^{99m}Tc -MAA particles have a size comprised between 10 and 100 μm and are lodged in the pulmonary precapillary arterioles after intravenous injection.^[2] However, in case of congenital heart disease with a right-to-left shunt, ^{99m}Tc -MAA can also be distributed in the systemic circulation.^[3] Here, we report an uncommon cause and site of ^{99m}Tc -MAA uptake during a lung perfusion scintigraphy.

CASE REPORT

A 53-year-old female underwent a lung V/Q scan [Figure 1a] in the workup of extensive thrombosis of the left subclavian and internal jugular veins. The V/Q scan ruled out PE, but showed atypical perfusion uptake in the upper part of the mediastinum [white arrow, Figure 1a]. The perfusion single-photon emission computed tomography (CT)/CT

confirmed a ^{99m}Tc -MAA uptake at the level of the posterior edge of the fifth thoracic vertebra and less intensely in the seventh thoracic vertebra [white arrow, Figure 1b]. A chest CT scan realized 2 days before was retrospectively analyzed by a senior thoracic radiologist and demonstrated unusual tortuous and opacified thoracic and superficial veins in the left chest wall and collaterals of the lateral thoracic vein [gray arrow, Figure 1c].

DISCUSSION

^{99m}Tc -MAA particles used for lung perfusion scan were injected into a vein of the left arm. Normally, all these particles passed through the right heart to be finally trapped by lung

PHILIPPE D'ABADIE, BENOIT GHAYE¹, FRANÇOIS JAMAR

Departments of Nuclear Medicine and ¹Radiology, Cliniques Universitaires Saint-Luc, Université Catholique de Louvain, Brussels, Belgium


Address for correspondence: Dr. Philippe D'Abadie, Department of Nuclear Medicine, Cliniques Universitaires Saint-Luc, Université Catholique de Louvain, Avenue Hippocrate, 10, Brussels 1200, Belgium.
E-mail: philippe.dabadie@uclouvain.be

Submission: 28-Mar-19, **Accepted:** 23-Jul-19, **Published:** 07-Nov-19

This is an open access journal, and articles are distributed under the terms of the Creative Commons Attribution-NonCommercial-ShareAlike 4.0 License, which allows others to remix, tweak, and build upon the work non-commercially, as long as appropriate credit is given and the new creations are licensed under the identical terms.

For reprints contact: WKHLRPMedknow_reprints@wolterskluwer.com

How to cite this article: D'Abadie P, Ghaye B, Jamar F. Vertebral uptake of ^{99m}Tc -macroaggregated albumin during lung perfusion scanning. World J Nucl Med 2020;19:271-2.

Access this article online	
Website: www.wjnm.org	Quick Response Code 
DOI: 10.4103/wjnm.WJNM_44_19	

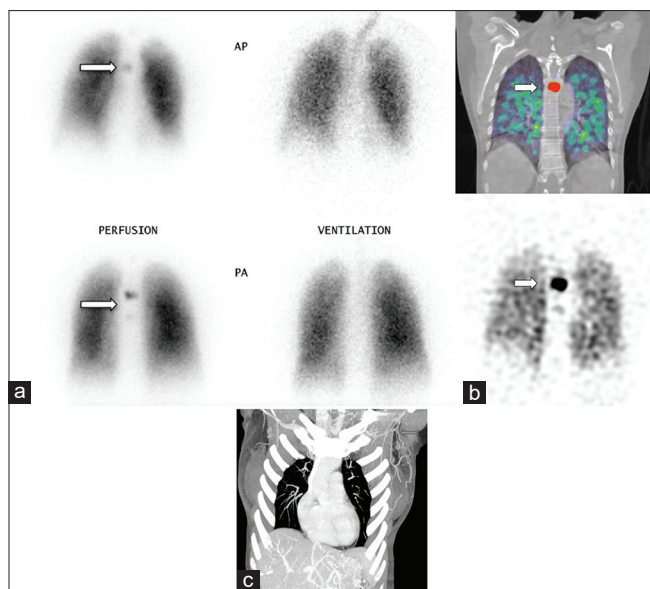


Figure 1: (a) V/Q scan with atypical perfusion uptake in the upper part of the mediastinum (white arrow). Anterior views are visualized in the upper part and posterior views in the lower part. (b) Perfusion ^{99m}Tc -macroaggregated albumin single-photon emission computed tomography/computed tomography with uptake at the level of the posterior edge of the fifth thoracic vertebra (white arrow) and less intensely in the seventh thoracic vertebra (coronal views of single-photon emission computed tomography/computed tomography fusion in the upper part and single-photon emission computed tomography in the lower part). (c) Chest computed tomography scan with contrast injection (maximum intensity projection MIP reconstruction) with unusual tortuous veins in the left thoracic wall and collaterals of the lateral thoracic vein (gray arrow)

precapillaries. In our case, some ^{99m}Tc -MAA particles passed through the left chest wall venous collaterals and probably through the vertebral venous plexus to be finally trapped by the vertebral capillaries. Indeed, in case of obstruction of superior vena cava or its branches (such as the subclavian vein), multiple venous collateral pathways are developed to bypass thrombosis and drain blood;^[4,5] these include the lateral thoracic vein and the vertebral venous network.^[6] The vertebral venous plexus is a valveless^[7] and large capacitance system that communicates with other venous systems.^[8] Its absence of valves allows changing the direction of the blood flow, depending on the local pressure. In our case, some ^{99m}Tc -MAA particles passed through the vertebral venous plexus by retrograde flow^[9] and were finally trapped by the vertebral capillaries.^[10]

CONCLUSION

Besides right-to-left shunting, extrapulmonary uptake in lung perfusion scintigraphy is very rare and may be used

by collateral venous pathways. The knowledge of the recent venous status is important for choosing the best site of ^{99m}Tc -MAA injection.

Declaration of patient consent

The authors certify that they have obtained all appropriate patient consent forms. In the form the patient(s) has/have given his/her/their consent for his/her/their images and other clinical information to be reported in the journal. The patients understand that their names and initials will not be published and due efforts will be made to conceal their identity, but anonymity cannot be guaranteed.

Financial support and sponsorship

Nil.

Conflicts of interest

There are no conflicts of interest.

REFERENCES

- Bajc M, Jonson B. Ventilation/Perfusion SPECT for diagnosis of pulmonary embolism and other diseases. *Int J Mol Imaging* 2011;2011:682949.
- Bajc M, Neilly JB, Miniati M, Schuemichen C, Meignan M, Jonson B, *et al.* EANM guidelines for ventilation/perfusion scintigraphy: Part I. Pulmonary imaging with ventilation/perfusion single photon emission tomography. *Eur J Nucl Med Mol Imaging* 2009;36:1356-70.
- Ciofetta G, Piepsz A, Roca I, Fisher S, Hahn K, Sixt R, *et al.* Guidelines for lung scintigraphy in children. *Eur J Nucl Med Mol Imaging* 2007;34:1518-26.
- Kapur S, Paik E, Rezaei A, Vu DN. Where there is blood, there is a way: Unusual collateral vessels in superior and inferior vena cava obstruction. *Radiographics* 2010;30:67-78.
- Richard HM 3rd, Selby JB Jr., Gay SB, Tegtmeyer CJ. Normal venous anatomy and collateral pathways in upper extremity venous thrombosis. *Radiographics* 1992;12:527-34.
- Kara M, Pradel C, Phan C, Miquel A, Arrivé L. CT features of vertebral venous congestion simulating sclerotic metastases in nine patients with thrombosis of the superior vena cava. *AJR Am J Roentgenol* 2016;207:80-6.
- Stringer MD, Restieaux M, Fisher AL, Crosado B. The vertebral venous plexuses: The internal veins are muscular and external veins have valves. *Clin Anat* 2012;25:609-18.
- Nathoo N, Caris EC, Wiener JA, Mendel E. History of the vertebral venous plexus and the significant contributions of breschet and Batson. *Neurosurgery* 2011;69:1007-14.
- Batson OV. The function of the vertebral veins and their role in the spread of metastases. *Ann Surg* 1940;112:138-49.
- Karls S, Hassoun H, Derbekyan V. Vertebral uptake of tc-99m macroaggregated albumin (MAA) with SPECT/CT occurring in superior vena cava obstruction. *Nucl Med Mol Imaging* 2016;50:266-9.