

Case report

Fluorodeoxyglucose, sodium fluoride, and prostate-specific membrane antigen positron emission tomography studies for treatment response assessment in prostate cancer

ABSTRACT

Various positron emission tomography (PET) studies are available for prostate cancer which show various successes at demonstrating primary, recurrent, or metastatic tumor and assessing response to treatment. In this case report, we will present and compare pre- and post-therapy fluorodeoxyglucose, sodium fluoride, and gallium-68 prostate-specific membrane antigen PET images of a patient with prostate cancer.

Keywords: Fluorodeoxyglucose, gallium-68 prostate-specific membrane antigen, prostate cancer, sodium fluoride, treatment response assessment

INTRODUCTION

Prostate cancer is the most common cancer and the third most cause for cancer-associated death in men.^[1] Various positron emission tomography (PET) studies are available for prostate cancer which target various molecules, metabolisms, synthesis, or receptors with various degrees of success at detecting primary tumor and metastatic disease and assessing response to treatment. Among these, F-18 fluorodeoxyglucose (FDG) assesses the glucose metabolism, F-18 sodium fluoride (NaF) evaluates osteoblastic activity, radiolabeled choline (F-18 choline or C-11 choline) is a marker of cell membrane proliferation which is phosphorylated by choline kinase to form phosphorylcholine, followed by generation of phosphatidylcholine in the tumor cell membrane, C-11 acetate incorporates into intracellular phosphatidylcholine membrane microdomains following conversion to acetyl-CoA and then to fatty acids, F-18 fluoro-5 α -dihydrotestosterone binds to androgen receptors, C-11 methionine assesses the amino acid transport and protein synthesis, F-18 fluciclovine assesses the amino acid transport, and gallium-68 prostate-specific membrane antigen (Ga-68 PSMA) ligand has high affinity to human PSMA.

Bone scan is widely used in the management of prostate cancer in the detection of bone metastases. Currently, NaF PET/computed tomography (CT) bone scan has significantly replaced standard bone scintigraphy. Ga-68 PSMA ligand PET/CT has gained high attention for accurate staging of primary prostate cancer and restaging after biochemical recurrence.^[2-4] FDG PET/CT is not commonly used in prostate cancer and its use is limited to staging patients with aggressive primary tumors or localizing the site of disease in a small fraction of patients with biochemical failure and negative conventional imaging studies.^[5] FDG-PET is useful for assessing response

ISMET SARIKAYA, ABDELHAMID ELGAZZAR, ALI SARIKAYA¹, MAHMOUD ALFEELI²


Department of Nuclear Medicine, Faculty of Medicine, Kuwait University, ²Department of Nuclear Medicine, Mubarak Al-Kabeer Hospital, Jabriya, Kuwait, ¹Department of Nuclear Medicine, Faculty of Medicine, Trakya University, Edirne, Turkey

Address for correspondence: Dr. Ismet Sarikaya, Department of Nuclear Medicine, Faculty of Medicine, Kuwait University, PO Box 24923, 13110 Safat, Kuwait.
E-mail: isarikaya99@yahoo.com

This is an open access journal, and articles are distributed under the terms of the Creative Commons Attribution-NonCommercial-ShareAlike 4.0 License, which allows others to remix, tweak, and build upon the work non-commercially, as long as appropriate credit is given and the new creations are licensed under the identical terms.

For reprints contact: reprints@medknow.com

How to cite this article: Sarikaya I, Elgazzar A, Sarikaya A, Alfeeli M. Fluorodeoxyglucose, sodium fluoride, and prostate-specific membrane antigen positron emission tomography studies for treatment response assessment in prostate cancer. World J Nucl Med 2018;17:207-10.

Access this article online	
Website: www.wjnm.org	Quick Response Code 
DOI: 10.4103/wjnm.WJNM_51_17	

to treatment and prognosis in patients with castrate-resistant metastatic prostate cancer.^[5-7]

In this article, we will present FDG, NaF, and PSMA PET/CT images to assess response to treatment in a patient with prostate cancer.

CASE REPORT

A 71-year-old male initially presented with elevated prostate-specific antigen (PSA) of 190 ng/ml and multiple lung nodules on CT of the chest in June 2015. Biopsy from the prostate gland was performed. FDG PET/CT study 2 days after the biopsy showed hypermetabolic nodule in the left lung with SUVmax of 1.9, which further increased to 5.5 on delayed images and heterogeneously increased bone marrow uptake which was suspicious for diffuse bone metastases and moderate uptake in the prostate gland (SUVmax: 5.8) [Figures 1 and 2]. Biopsy result from the prostate gland was consistent with prostate cancer. NaF PET in July 2015 showed widespread bone metastasis [Figure 1]. Clinical stage based on PET and radiological studies was T3bN1M1. The patient was placed on chemotherapy. PSA became 4.4 ng/ml with chemotherapy, but it was stopped in February 2016, due to liver toxicity, and hormone therapy (HT) was started. Because of rising PS (10 ng/ml), while on HT, FDG and NaF PET studies were ordered in May 2016. FDG PET showed resolution of uptake in the lung nodule and significant reduction of the

bone marrow hypermetabolic activity but persistent uptake in the prostate gland (SUVmax: 8.4) [Figures 1 and 2]. NaF PET/CT study showed widespread bone metastasis with slight reduction in osteoblastic activity of some lesions with overall stability in other lesions as compared to prechemotherapy NaF PET/CT scan [Figure 1]. To better assess residual disease, Ga-68 PSMA PET/CT scan was also obtained which showed uptake in the prostate gland as well as in several bones and pelvic lymph nodes [Figures 1 and 2]. The patient continued to receive HT, but PSA continued to rise to 99 ng/ml. Ga-68 PSMA PET/CT study in November 2016 showed the progression of disease with increase in the number of metastatic lesions in the bone and lymph nodes with diffuse uptake in the prostate gland [Figures 1 and 2]. The patient was referred to another hospital for Lu-177 PSMA treatment.

DISCUSSION

In our patient with widespread bone metastases on NaF PET scan, there was only mild reduction with mainly persistent osteoblastic activity after chemotherapy. Based on NaF PET images only, we can say findings are due mild response to treatment with significant residual disease. However, when comparing and correlating postchemotherapy NaF with FDG PET which showed significant reduction in metabolic activity of bone and bone marrow disease, we can now say that significant portion of persistent osteoblastic activity on NaF PET is likely due to bone repair in the region of the

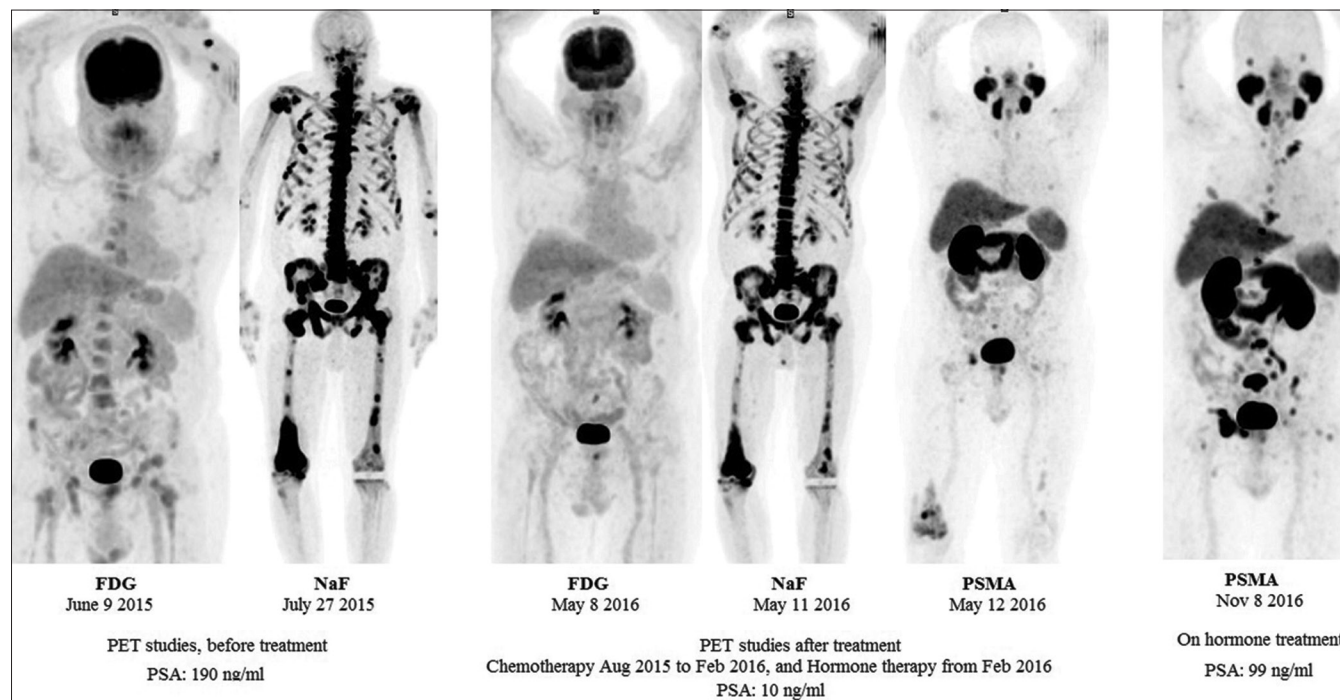


Figure 1: Fluorodeoxyglucose, sodium fluoride, and prostate-specific membrane antigen positron emission tomography maximum intensity projection images before and after treatment

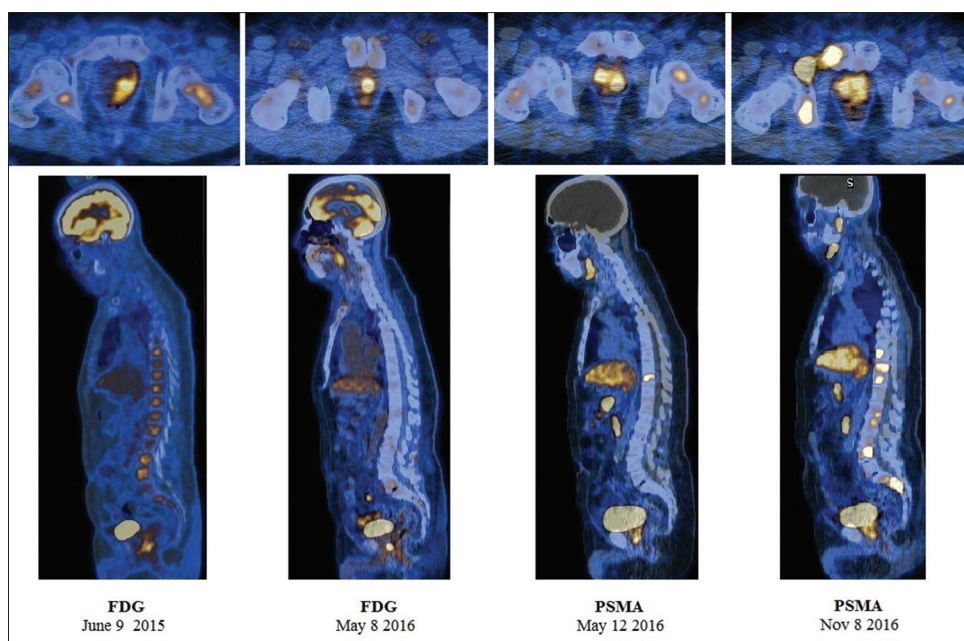


Figure 2: Selected transaxial and sagittal fluorodeoxyglucose and prostate-specific membrane antigen positron emission tomography/computed tomography fusion images demonstrating uptake in the prostate gland and bones

treated disease or decreasing flare uptake 3 months after chemotherapy. On the other hand, FDG PET findings (mild residual bone and bone marrow activity) cannot determine whether there is mild residual disease or reactive bone marrow changes. Obtaining Ga-68 PSMA PET study helped to confirm the amount of residual disease in this patient. However, it would be valuable to have a prechemotherapy Ga-68 PSMA PET and compare the amount of metastatic disease in bone and soft tissues with the extent of the disease identified on prechemotherapy FDG and NaF PET studies.

Bone scans, either with NaF PET or bone scintigraphy, have limited value at evaluating response to treatment as they show the osteoblastic reaction or response to tumor infiltration, not the tumor itself. Osteoblastic activity as a result of bone healing or flare response can cause false-positive diagnosis of disease progression or residual disease.^[8-11] Flare response is considered when metastases on bone scan remain stable or show progression despite other parameters indicate response to treatment. Flare is probably caused by an increase in blood flow due to an inflammatory response or an increased turnover of hydroxyapatite in the new bone laid down as part of the healing process.^[12] Flare phenomenon lasts 6–12 months after chemotherapy.

It is well known that FDG PET has limited value in detecting osteoblastic metastatic disease.^[13] In our case, NaF PET clearly showed the more extensive involvement of the bone than FDG PET did. However, at treatment response assessment, FDG PET provided better result than NaF PET.

The advantage of FDG over NaF is that FDG shows tumor itself, but NaF demonstrates osteoblastic reaction or response to tumor. At response assessment to abiraterone (HT) and cabozantinib (inhibitor of the tyrosine kinases) in patients with castrate-resistant prostate cancer, FDG PET/CT provided better results than NaF PET/CT and standard imaging.^[6]

Recent studies showed promising results with Ga-68 PSMA ligand in detecting metastatic disease in both soft tissues and bone.^[14-16] In a patient with bone metastases and progression after Ra-223 treatment on both Ga-68 PSMA and NaF PET, it was not clear if the increased uptake was due to flare or disease progression on NaF PET.^[17] Authors suggested that Ga-68 PSMA PET may be superior to F-18 NaF PET for the evaluation of therapy response to Ra-223 therapy in bone metastases. In a recent study, Ga-68 PSMA-11 PET resulted in a major change in management in 53% of patients with biochemical recurrence.^[18] In patients with PSA levels below 0.2 ng/dL, 7 of 12 patients had disease detected on PSMA PET scan, five of whom had a major change in management in the same study.

CONCLUSION

In our patient with prostate cancer and extensive bone metastases who had multiple PET images before and after treatment, NaF PET was clearly superior to FDG PET for demonstrating amount of bone metastasis. On the other hand, FDG PET provided a better result than NaF PET for assessing response to treatment, but PSMA PET was superior to both NaF and FDG PET studies for demonstrating amount

of residual disease. It appears that Ga-68 PSMA PET is helpful in differentiating flare from stable or progressive metastatic bone disease in cases with indeterminate bone scan.

Declaration of patient consent

The authors certify that they have obtained all appropriate patient consent forms. In the form the patient(s) has/have given his/her/their consent for his/her/their images and other clinical information to be reported in the journal. The patients understand that their names and initials will not be published and due efforts will be made to conceal their identity, but anonymity cannot be guaranteed.

Financial support and sponsorship

Nil.

Conflicts of interest

There are no conflicts of interest.

REFERENCES

- Torre LA, Bray F, Siegel RL, Ferlay J, Lortet-Tieulent J, Jemal A. Global cancer statistics, 2012. *CA Cancer J Clin* 2015;65:87-108.
- Sterzing F, Kratochwil C, Fiedler H, Katayama S, Habl G, Kopka K, *et al.* (68) Ga-PSMA-11 PET/CT: A new technique with high potential for the radiotherapeutic management of prostate cancer patients. *Eur J Nucl Med Mol Imaging* 2016;43:34-41.
- Afshar-Oromieh A, Avtzi E, Giesel FL, Holland-Letz T, Linhart HG, Eder M, *et al.* The diagnostic value of PET/CT imaging with the (68) Ga-labelled PSMA ligand HBED-CC in the diagnosis of recurrent prostate cancer. *Eur J Nucl Med Mol Imaging* 2015;42:197-209.
- Kabasakal L, Demirci E, Ocak M, Akyel R, Nematyazar J, Aygun A, *et al.* Evaluation of PSMA PET/CT imaging using a 68Ga-HBED-CC ligand in patients with prostate cancer and the value of early pelvic imaging. *Nucl Med Commun* 2015;36:582-7.
- Jadvar H. Is there use for FDG-PET in prostate cancer? *Semin Nucl Med* 2016;46:502-6.
- Zukotynski KA, Kim CK, Gerbaudo VH, Hainer J, Taplin ME, Kantoff P, *et al.* (18) F-FDG-PET/CT and (18) F-NaF-PET/CT in men with castrate-resistant prostate cancer. *Am J Nucl Med Mol Imaging* 2014;5:72-82.
- Harrison MR, Hahn NM, Pili R, Oh WK, Hammers H, Sweeney C, *et al.* A phase II study of 2-methoxyestradiol (2ME2) NanoCrystal® dispersion (NCD) in patients with taxane-refractory, metastatic castrate-resistant prostate cancer (CRPC). *Invest New Drugs* 2011;29:1465-74.
- Levenson RM, Sauerbrunn BJ, Bates HR, Newman RD, Eddy JL, Ihde DC. Comparative value of bone scintigraphy and radiography in monitoring tumor response in systemically treated prostatic carcinoma. *Radiology* 1983;146:513-8.
- Pollen JJ, Witzum KF, Ashburn WL. The flare phenomenon on radionuclide bone scan in metastatic prostate cancer. *AJR Am J Roentgenol* 1984;142:773-6.
- Ciray I, Aström G, Andréasson I, Edekling T, Hansen J, Bergh J, *et al.* Evaluation of new sclerotic bone metastases in breast cancer patients during treatment. *Acta Radiol* 2000;41:178-82.
- Scher HI. Prostate carcinoma: defining therapeutic objectives and improving overall outcomes. *Cancer* 2003;97 3 Suppl: 758-71.
- Messiou C, Cook G, deSouza NM. Imaging metastatic bone disease from carcinoma of the prostate. *Br J Cancer* 2009;101:1225-32.
- Nakai T, Okuyama C, Kubota T, Yamada K, Ushijima Y, Taniike K, *et al.* Pitfalls of FDG-PET for the diagnosis of osteoblastic bone metastases in patients with breast cancer. *Eur J Nucl Med Mol Imaging* 2005;32:1253-8.
- Afshar-Oromieh A, Zechmann CM, Malcher A, Eder M, Eisenhut M, Linhart HG, *et al.* Comparison of PET imaging with a(68) Ga-labelled PSMA ligand and (18)F-choline-based PET/CT for the diagnosis of recurrent prostate cancer. *Eur J Nucl Med Mol Imaging* 2014;41:11-20.
- Maurer T, Gschwend JE, Rauscher I, Souvatzoglou M, Haller B, Weirich G, *et al.* Diagnostic efficacy of (68) Gallium-PSMA positron emission tomography compared to conventional imaging for lymph node staging of 130 consecutive patients with intermediate to high risk prostate cancer. *J Urol* 2016;195:1436-43.
- Eiber M, Maurer T, Souvatzoglou M, Beer AJ, Ruffani A, Haller B, *et al.* Evaluation of hybrid 68Ga-PSMA Ligand PET/CT in 248 patients with biochemical recurrence after radical prostatectomy. *J Nucl Med* 2015;56:668-74.
- Uprimny C, Kroiss A, Nilica B, Buxbaum S, Decristoforo C, Horninger W, *et al.* (68)Ga-PSMA ligand PET versus (18)F-NaF PET: Evaluation of response to (223) Ra therapy in a prostate cancer patient. *Eur J Nucl Med Mol Imaging* 2015;42:362-3.
- Hope TA, Aggarwal R, Chee B, Tao D, Greene KL, Cooperberg M, *et al.* Impact of Ga-68 PSMA-11 PET on management in patients with biochemically recurrent prostate cancer. *J Nucl Med* 2017. pii: jnumed. 117.192476.