

Case Report

Diffuse pleural metastases of osteosarcoma detected by bone scan

ABSTRACT

Osteosarcoma (OS) is a fast-growing tumor, with a high risk of local recurrence and distant metastases, with the lung and bone being the most common sites of dissemination occurring in approximately 80% of cases. Pleural metastases rarely occurs and the appearance of diffuse pleural thickening with ossification is not usual, with few such cases reported due to the current state-of-art treatment protocols. A 29-year-old woman, diagnosed with a proximal left tibial OS underwent planar and single-photon emission computed tomography/computed tomography bone scan scintigraphy with ^{99m}Tc methylene diphosphonate showing bilateral pleural uptake, corresponding to multiple calcified foci of thickening and nodules.

Keywords: Bone scan, osteosarcoma, pleural metastases

INTRODUCTION

Osteosarcoma (OS), the most common primary malignant neoplasm of the bone, has the second-highest mortality rate among pediatric cancers, and is most commonly diagnosed in patients in the second and third decades of life.^[1] It is a fast-growing tumor, with a high risk of local recurrence and distant metastases, with the lung and bone being the most common sites of dissemination, occurring in approximately 80% of cases,^[2] but metastases to other sites are uncommon and occur in fewer than 10% of cases.^[3]

Bone scan scintigraphy (BS) with ^{99m}Tc methylene diphosphonate (^{99m}Tc -MDP) is useful for the detection of distant bone disease, which is the second most likely location for metastatic spread. Positive findings on the bone scan may warrant additional imaging of the area of concern and ultimately, a biopsy may be necessary to prove the definitive presence of distant bone disease.^[4]

Pleural metastases rarely occurs and the appearance of diffuse pleural thickening with ossification is not usual, with few such cases reported currently reported due to the state-of-art treatment protocols.^[5,6] Most of the reported cases occurred

after the initial treatment and isolated pleural metastases without lung metastases are unusual.^[7]

Histologically, this tumor is composed of a sarcomatous fibroblastic stroma in which osteoblastic activity induces the formation of tumor osteoid and bone. Uptake of bone-seeking radionuclides in OS metastases have been described and the mechanism of uptake is believed to be direct incorporation in the osteoid deposited by the tumor, including pleural metastases.^[8]

Herein, we report an interesting case of OS with bilateral pleural and lung metastases, without bone involvement detected by BS.

ANDRÉ MARCONDES BRAGA RIBEIRO, EDUARDO NOBREGA PEREIRA LIMA, DANIEL HABIB ISSA LIMA

Department of Nuclear Medicine, A. C. Camargo Cancer Center, Liberdade, São Paulo, Brazil


Address for correspondence: Dr. André Marcondes Braga Ribeiro,
Department of Nuclear Medicine, A. C. Camargo Cancer Center,
Rua Professor Antônio Prudente, 211, 01509-010, Liberdade,
São Paulo, Brazil.
E-mail: andre_mbr@hotmail.com

Submission: 23-Apr-20, **Revised:** 01-Jun-20,
Accepted: 26-Jun-20, **Published:** 22-Aug-20

This is an open access journal, and articles are distributed under the terms of the Creative Commons Attribution-NonCommercial-ShareAlike 4.0 License, which allows others to remix, tweak, and build upon the work non-commercially, as long as appropriate credit is given and the new creations are licensed under the identical terms.

For reprints contact: WKHLRPMedknow_reprints@wolterskluwer.com

How to cite this article: Ribeiro AM, Lima EN, Lima DH. Diffuse pleural metastases of osteosarcoma detected by bone scan. World J Nucl Med 2020;19:310-2.

Access this article online	
Website: www.wjnm.org	Quick Response Code 
DOI: 10.4103/wjnm.WJNM_59_20	

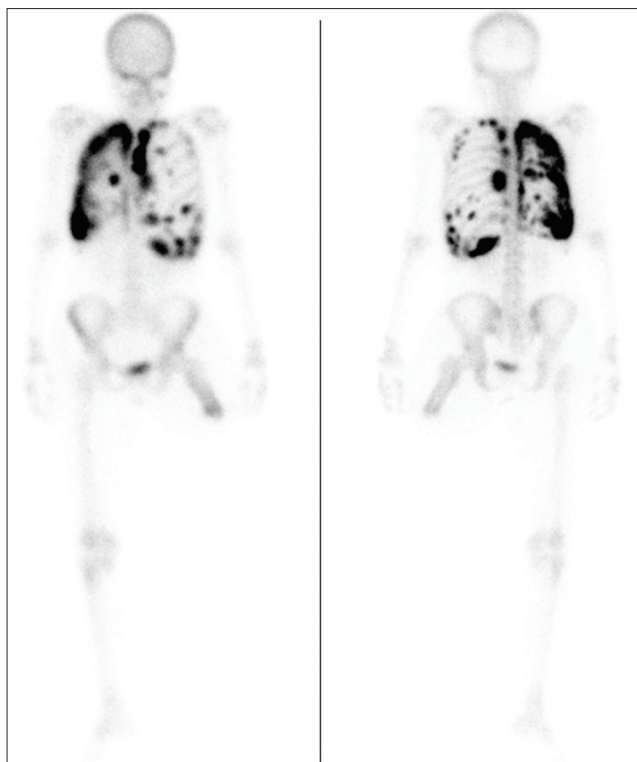


Figure 1: Planar images of the bone scan showing diffuse areas of ^{99m}technetium methylene diphosphonate uptake in the pleura projection bilaterally

CASE REPORT

A 29-year-old woman was diagnosed with high-grade fibroblastic OS in the proximal left tibia. She was initially treated with chemotherapy, followed by amputation of the left lower limb. Thirteen months later, she complained of dyspnea and chest pain. A computed tomography (CT) scan of the chest was performed and showed multiple pulmonary and pleural nodules suggestive of involvement secondary to the OS. In addition, a planar and single-photon emission computed tomography/CT, BS with ^{99m}Tc-MDP was also requested and demonstrated bilateral diffuse pleural plaques, which corresponded to multiple calcified foci of thickening and nodules [Figures 1 and 2]. BS did not show signs of bone metastases.

After restaging examinations, systemic palliative treatment for the patient was started.

DISCUSSION

OS is an aggressive primary bone tumor arising from primitive bone-forming cells.^[6] The metastases of OS are typically hematogenous and the most common sites are lungs and bone.^[2] Pleural metastases of OS are exceedingly rare^[6] and the appearance of diffuse pleural thickening with ossification is also unusual, and few such cases have been reported.^[3] A

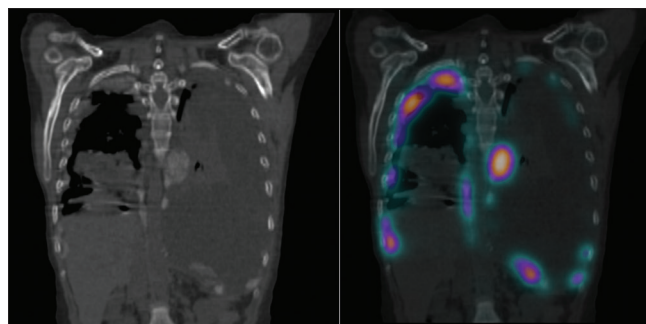


Figure 2: Coronal computed tomography image showing multiple calcified foci of thickening and nodules in both pleura (left) and the single-photon emission computed tomography/computed tomography fusion showing the ^{99m}technetium methylene diphosphonate uptake correspondence in these areas (right)

study that included 134 patients diagnosed with OS showed that 13 of them had extrapulmonary metastases, and only two of them presented pleural metastases.^[3]

Pleural metastases in OS can occur by two mechanisms: Direct contact of pleura with the lung metastases and hematogenous spread of OS.^[7]

Conventional imaging features of extraskeletal OSs are largely nonspecific.^[9] It is a fact that this kind of tumor can produce bone and osteoid,^[10] BS can help to show these lesions, including pleural metastases.

BS is often used in conjunction with CT to identify metastases, and the presence or absence of metastatic disease remains one of the most important predictors of patient outcome.^[4]

Although CT had already shown lung and pleural lesions, our intention was to demonstrate a rare presentation of OS and an unusual image of pleural metastases detected by BS, and its diffuse pattern of distribution compared to the anatomical diagnostic method.

Declaration of patient consent

The authors certify that they have obtained all appropriate patient consent forms. In the form the patient(s) has/have given his/her/their consent for his/her/their images and other clinical information to be reported in the journal. The patients understand that their names and initials will not be published and due efforts will be made to conceal their identity, but anonymity cannot bechrological order guaranteed.

Financial support and sponsorship

Nil.

Conflicts of interest

There are no conflicts of interest.

REFERENCES

1. Pochanugool L, Subhadharaphandou T, Dhanachai M, Hathirat P, Sangthawan D, Pirabul R, *et al.* Prognostic factors among 130 patients with osteosarcoma. *Clin Orthop Relat Res* 1997;345:206-14.
2. Lindsey BA, Markel JE, Kleinerman ES. Osteosarcoma overview. *Rheumatol Ther* 2017;4:25-43.
3. Rastogi R, Garg R, Thulkar S, Bakhshi S, Gupta A. Unusual thoracic CT manifestations of osteosarcoma: Review of 16 cases. *Pediatr Radiol* 2008;38:551-8.
4. Geller DS, Gorlick R. Osteosarcoma: A review of diagnosis, management, and treatment strategies. *Clin Adv Hematol Oncol* 2010;8:705-18.
5. Marchiori E, Menna Barreto M, Zanetti G. Pleural metastases of osteosarcoma. *Ann Thorac Surg* 2018;105:e87-e88.
6. Krishnamurthy K, Alghamdi S, Kochiyil J, Bruney GF, Poppiti RJ. Osteosarcoma presenting with malignant pleural effusion in a 55 year old. *Respir Med Case Rep* 2018;25:314-7.
7. Sukumaran R, Nayak N, Mony R, Kaur J, Nair S: Osteosarcoma presenting with massive malignant pleural effusion. *Oncol J India* 2019;3:20.
8. Palestro CJ, Styles ST, Kim CK, Goldsmith SJ. Bone scintigraphy in pleural metastases of osteogenic sarcoma. *Clin Nucl Med* 1990;15:346-7.
9. Roller LA, Chebib I, Bredella MA, Chang CY. Clinical, radiological, and pathological features of extraskeletal osteosarcoma. *Skeletal Radiol* 2018;47:1213-20.
10. Murphey MD, Robbin MR, McRae GA, Flemming DJ, Temple HT, Kransdorf MJ. The many faces of osteosarcoma. *Radiographics* 1997;17:1205-31.