

Case Report

¹⁸F-fluorodeoxyglucose positron emission tomography/computed tomography in the diagnosis of a rare mycotic aneurysm of the thoracic aorta in a patient with fever of unknown origin

ABSTRACT

Fever of unknown origin (FUO) is a condition with high mortality that often presents a diagnostic challenge to clinicians. We present the case of a patient with FUO who was discovered to have a rare mycotic aneurysm of the thoracic aorta by ¹⁸F-fluorodeoxyglucose positron emission tomography/computed tomography imaging. Mycotic aneurysm, also known as an infected aneurysm, is a highly lethal condition due to the risk of sepsis and aneurysmal rupture. While unusual to present in this manner, it is of utmost importance to promptly recognize a mycotic aneurysm as a potential diagnosis because initiation of treatment is critical in reversing the natural history of the disease.

Keywords: Aneurysm, aorta, fluorodeoxyglucose, fever of unknown origin, infection, mycotic, positron emission tomography/computed tomography

INTRODUCTION

Identifying the etiology of fever of unknown origin (FUO) remains a challenging diagnostic problem despite recent advances in diagnostic techniques. Early detection of the cause for FUO is important in guiding therapy.^[1] The use of ¹⁸F-fluorodeoxyglucose positron emission tomography/computed tomography (¹⁸F-FDG PET/CT) as a tool for evaluation of patients with FUO has been shown to contribute clinically important information for the diagnosis or exclusion of an etiology for FUO.^[2] We present a patient with longstanding FUO which was discovered on ¹⁸F-FDG PET/CT to be due to a rare mycotic aneurysm of the thoracic aorta.

CASE REPORT

A 49-year-old female with a complex medical history including a 10-year history of end-stage renal disease due to systemic lupus erythematosus, a history of infected left upper extremity hemodialysis graft 4 years ago, and methicillin-sensitive *Staphylococcus aureus* (MSSA) bacteremia, presented with prolonged, recurrent fevers of unclear etiology. One month

earlier, the patient was hospitalized with MSSA bacteremia thought to be secondary to mastitis for which she was receiving outpatient intravenous antibiotics. Despite antibiotics, she continued to experience fevers as high as 38.3°C. On admission, laboratory workup included normal white blood cell count, an elevated erythrocyte sedimentation rate of 101 mm/h (reference range: 0–20 mm/h), elevated C-reactive protein

MATTHEW Q. SCHMIDT, ROLA ALTOOS¹, JENNIFER J. KWAK

Department of Radiology, University of Colorado School of Medicine, Aurora, CO, ¹Radiology Specialists of Florida, Nuclear Medicine Section, Maitland, FL, USA


Address for correspondence: Dr. Jennifer J. Kwak, Department of Radiology, University of Colorado School of Medicine, 12401 E 17th Ave., Mailstop L954, Aurora, CO 80045, USA.
E-mail: jennifer.kwak@cuanschutz.edu

Submitted: 29-Apr-2020, **Revised:** 29-Jun-2020,
Accepted: 30-Jun-2020, **Published:** 20-Aug-2021

This is an open access journal, and articles are distributed under the terms of the Creative Commons Attribution-NonCommercial-ShareAlike 4.0 License, which allows others to remix, tweak, and build upon the work non-commercially, as long as appropriate credit is given and the new creations are licensed under the identical terms.

For reprints contact: WKHLRPMedknow_reprints@wolterskluwer.com

How to cite this article: Schmidt MQ, Altoos R, Kwak JJ. ¹⁸F-fluorodeoxyglucose positron emission tomography/computed tomography in the diagnosis of a rare mycotic aneurysm of the thoracic aorta in a patient with fever of unknown origin. World J Nucl Med 2021;20:305-8.

Access this article online	
Website: www.wjnm.org	Quick Response Code 
DOI: 10.4103/wjnm.WJNM_64_20	

of 10.7 mg/dL (reference range: 0.0–1.0 mg/dL), and positive blood cultures for MSSA. Extensive clinical and imaging workup failed to localize a source of the FUO. Finally, ^{18}F -FDG PET/CT (17.9 mCi; 61-min uptake time; Discovery ST 16-slice PET/CT, GE Healthcare, Chicago, IL, USA) was obtained to evaluate for the potential cause of fevers and for the clinical concern for recurrent infection of the left upper extremity vascular graft due to left arm pain.

^{18}F -FDG PET/CT incidentally revealed a lobulated soft-tissue mass [Figure 1a, arrow] with intense FDG uptake along the aortic arch [Figure 1b and c, arrow]. Evaluation of the nonattenuation corrected PET image [Figure 1d] confirmed that FDG uptake was not an attenuation correction artifact due to the adjacent dense aortic arch calcification. In addition, there were enlarged paratracheal mediastinal lymph nodes [Figure 1a] and enlarged bilateral axillary lymph nodes (not shown) demonstrating mild FDG uptake. Differential considerations for the FDG-avid soft-tissue mass adjacent to the aortic arch included infected aortic aneurysm and inflammatory aortic aneurysm, both of which require urgent follow-up. In addition, although less favored, adenopathy due to lymphoma or other metastatic malignancy was also considered. The abandoned left upper arm vascular graft did not demonstrate FDG uptake suspicious for infection [Figure 2a-c]. A new right upper thigh hemodialysis vascular graft demonstrated expected physiologic blood pool FDG activity and no abnormal FDG activity suspicious for infection [Figure 2d and e]. CT angiogram of the chest was obtained for further

evaluation of the FDG-avid soft-tissue mass adjacent to the aortic arch, which revealed a small 1-cm saccular aneurysm of the aortic arch segment of the thoracic aorta surrounded by a thick rim of inflammatory soft tissue [Figure 3a and b] compatible with a mycotic aneurysm in the setting of bacteremia.

The patient underwent thoracic endovascular aortic repair of the aneurysm [Figure 4] and was treated with 4 weeks of postoperative intravenous antibiotics. Follow-up blood cultures were negative, and the patient experienced resolution of her fevers. At the last follow-up, no cardiovascular complications or infections were reported.

DISCUSSION

FUO, generally defined as recurrent fevers lasting 2–3 weeks with no localizing etiology after appropriate inpatient or outpatient workup, presents a diagnostic challenge for clinicians. The mortality rate from FUO-related causes is reported to be as high as 12%–35%.^[3] As morphologic changes may be subtle early in the disease process, anatomic imaging modalities often have lower sensitivity in detecting abnormalities. Because determining the source of the fevers is critical in directing treatment, functional imaging can play an important role in diagnosis. In patients with FUO, elevated erythrocyte sedimentation rates, and elevated C-reactive protein levels, ^{18}F -FDG PET/CT has been shown to identify an etiology in 56% of cases with a high negative predictive value up to 100%.^[1] There are a few case reports of infected aneurysms of various arteries detected with ^{18}F -FDG PET/CT during the workup of FUO.^[4,5]

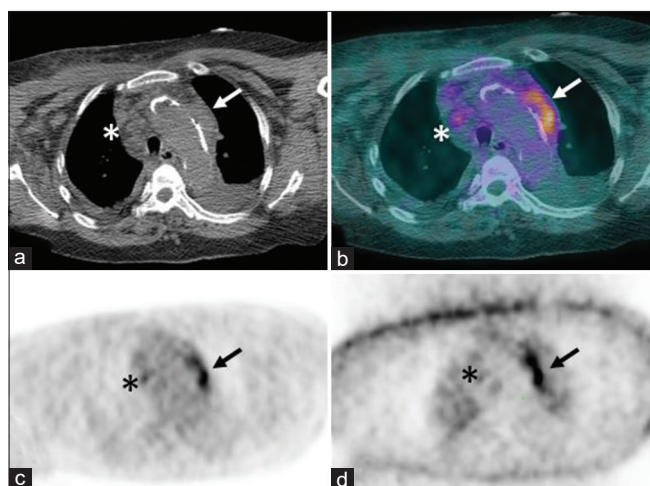


Figure 1: ^{18}F -fluorodeoxyglucose positron emission tomography/computed tomography localization computed tomography image (a) demonstrates a soft-tissue mass along the aortic arch (arrow) and enlarged mediastinal lymph nodes (asterisk). Fused positron emission tomography/computed tomography (b), attenuation corrected (c) and nonattenuation corrected (d) positron emission tomography images demonstrating intense fluorodeoxyglucose uptake in the soft-tissue mass (arrows) and mild fluorodeoxyglucose activity in lymph nodes (asterisk)

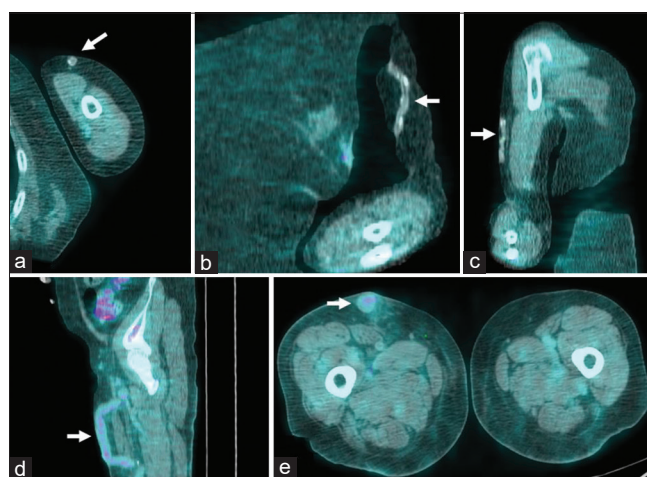


Figure 2: Axial (a), coronal (b), and sagittal (c) fused positron emission tomography/computed tomography images demonstrating no abnormal fluorodeoxyglucose activity at the abandoned left upper arm vascular graft (arrow). Sagittal (d) and axial (e) fused positron emission tomography/computed tomography images of the right thigh vascular graft (arrow) demonstrating physiologic blood pool activity

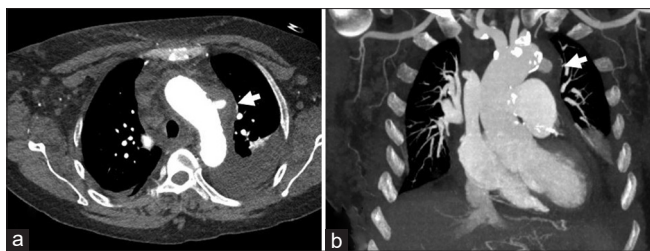


Figure 3: Axial (a) and coronal (b) images from the computed tomography angiography of the chest reveal a 1-cm saccular aneurysm of the aortic arch surrounded by a thick rim of inflammatory tissue (arrows)

Mycotic aneurysms, also known as infected aneurysms, can be a source of ongoing sepsis and fevers. Mycotic aneurysm located in the thoracic aorta is a rare diagnosis with no known true prevalence, reported only in case reports and a few small case series.^[6] In a single-institution review which included both the thoracic and abdominal aorta, the incidence of mycotic aneurysms in all surgically treated aortic aneurysms was reported to be 1 in 117.^[7] The condition carries a high mortality rate due to an aggressive natural history, with the cause of death most commonly secondary to aneurysmal rupture or multiorgan failure due to sepsis. Prompt diagnosis and initiation of therapy is essential. However, diagnosis is sometimes challenging because patients may be asymptomatic and blood cultures may be negative.^[8] Imaging is necessary to establish the diagnosis. CT angiography is the current imaging modality of choice for evaluating suspected infected aneurysms.^[9] CT imaging may show a lobulated or saccular appearance and/or rapid expansion of the aneurysm with surrounding inflammatory soft-tissue changes.^[10] Once discovered, the first choice of treatment for an infected thoracic aortic aneurysm is endovascular repair, especially in high-risk patients whose mortality rates from open surgery would be prohibitive, combined with intravenous antibiotic therapy.^[11]

As seen in this case, findings on ¹⁸F-FDG PET/CT may be the only indication that a mycotic aneurysm is the cause of FUO. However, ¹⁸F-FDG PET/CT may play an additional role in the evaluation of known aneurysms in patients with suspected infection as this can alter treatment plans. In addition, the utility of ¹⁸F-FDG PET/CT has been demonstrated in the setting of surveillance after postoperative antibiotic therapy.^[12] As such, it is of clinical importance to appropriately recognize and consider the diagnosis of mycotic aneurysm in patients with FUO.

Declaration of patient consent

The authors certify that they have obtained all appropriate patient consent forms. In the form the patient(s) has/have

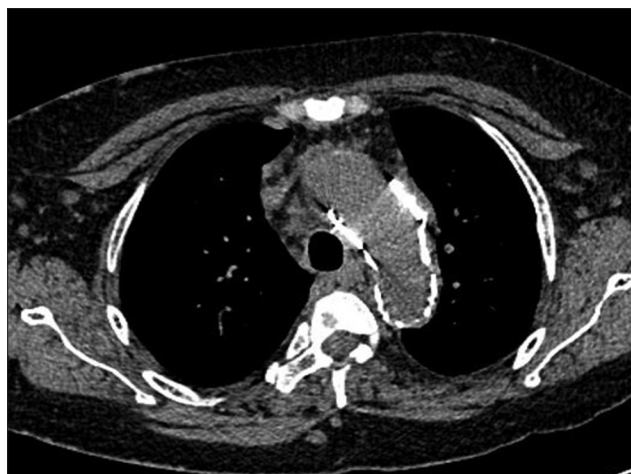

Figure 4: Postoperative computed tomography of the chest showing repair of the aortic arch aneurysm

given his/her/their consent for his/her/their images and other clinical information to be reported in the journal. The patients understand that their names and initials will not be published and due efforts will be made to conceal their identity, but anonymity cannot be guaranteed.

Financial support and sponsorship

Nil.

Conflicts of interest

There are no conflicts of interest.

REFERENCES

- Balink H, Collins J, Bruyn GA, Gemmel F. F-18 FDG PET/CT in the diagnosis of fever of unknown origin. *Clin Nucl Med* 2009;34:862-8.
- Keidar Z, Gurman-Balbir A, Gaitini D, Israel O. Fever of unknown origin: The role of 18F-FDG PET/CT. *J Nucl Med* 2008;49:1980-5.
- Mourad O, Palda V, Detsky AS. A comprehensive evidence-based approach to fever of unknown origin. *Arch Internal Med* 2003;163:545-51.
- Davison JM, Montilla-Soler JL, Broussard E, Wilson R, Cap A, Allen T. F-18 FDG PET-CT imaging of a mycotic aneurysm. *Clin Nucl Med* 2005;30:483-7.
- Jaruskova M, Belohlavek O. Role of FDG-PET and PET/CT in the diagnosis of prolonged febrile states. *Eur J Nucl Med Mol Imaging* 2006;33:913-8.
- Hsu R, Lin F. Infected aneurysm of the thoracic aorta. *J Vascular Surg* 2008;47:270-6.
- Chan FY, Crawford ES, Coselli JS, Safi HJ, Williams TW Jr. *In situ* prosthetic graft replacement for mycotic aneurysm of the aorta. *Ann Thorac Surg* 1989;47:193-203.
- Murakami M, Morikage N, Samura M, Yamashita O, Suehiro K, Hamano K. Fluorine-18-fluorodeoxyglucose positron emission tomography-computed tomography for diagnosis of infected aortic aneurysms. *Ann Vasc Surg* 2014;28:575-8.
- Lee WK, Mossop PJ, Little AF, Fitt GJ, Vrazas JI, Hoang JK, *et al.* Infected (mycotic) aneurysms: Spectrum of imaging appearances and management. *Radiographics* 2008;28:1853-68.

10. Macedo TA, Stanson AW, Oderich GS, Johnson CM, Panneton JM, Tie ML. Infected aortic aneurysms: Imaging findings. *Radiology* 2004;231:250-7.
11. Johnstone JK, Slaiby JM, Marcaccio EJ, Chong TT, Garcia-Toca M. Endovascular repair of mycotic aneurysm of the descending thoracic aorta. *Ann Vasc Surg* 2013;27:23-8.
12. Choi SJ, Lee JS, Cheong MH, Byun SS, Hyun IY. F-18 FDG PET/CT in the management of infected abdominal aortic aneurysm due to Salmonella. *Clin Nucl Med* 2008;33:492-5.