

Case Report

Grade 3 metastatic neuroendocrine neoplasms of two unusual primary sites with contrasting differentiation characteristics: Dual tracer positron emission tomography and computed tomography imaging (¹⁸F-fluorodeoxyglucose and ⁶⁸Ga-DOTATATE) correlates and their treatment implications

ABSTRACT

The correlates of dual tracer positron emission tomography and computed tomography (PET-CT) (¹⁸F-fluorodeoxyglucose [¹⁸F-FDG] and ⁶⁸Ga-DOTATATE) in patients of Grade 3 neuroendocrine neoplasms (NENs) are presented. The first, a patient of gall bladder NEN, operated, with histopathology suggestive of high-grade well-differentiated neuroendocrine tumors with MIB-1 labeling index of 35%, showed uptake with both ¹⁸F-FDG and ⁶⁸Ga-DOTATATE, including an uptake equivalent to Krenning score of 3–4 on ⁶⁸Ga-DOTATATE PET-CT; in the second, a patient of esophageal NEN, Grade 3 with poor differentiation features, with MIB-1 labeling index of 70%, thereby qualifying for Grade 3 neuroendocrine carcinoma, the FDG uptake was high with minimal uptake on ⁶⁸Ga-DOTATATE PET-CT. The illustrations reiterate the impression that relative uptake of ⁶⁸Ga-DOTATATE/FDG in the NEN lesions forms a valuable parameter for assessing the dynamic tumor biology in continuum and thus personalizing the treatment strategies.

Keywords: ¹⁸F-fluorodeoxyglucose positron emission tomography and computed tomography, ⁶⁸Ga-DOTATATE, dual tracer positron emission tomography and computed tomography, grade 3, Ki-67/MIB-1 labeling index, neuroendocrine neoplasms

INTRODUCTION

Neuroendocrine neoplasms (NENs) are heterogeneous class of tumors with the spectrum of low- to high-grade tumors with a varied presentation, imaging characteristics, treatment modalities, and response profile and eventually the overall prognosis; the biology cannot be strictly predicted in 3 histology grades, especially considering a wide range of G2 and G3. The WHO 2017 grading classification of NENs recognizes the classification of Grade 3 NENs based on (i) tumor Ki-67/MIB-1 labeling index and (ii) tumor differentiation as two distinctive parameters which could demonstrate divergent characteristics.^[1] This rationale is the basis for subdividing Grade 3 NENs into two subclasses: (a) Grade

SARVESH LOHARKAR^{1,2}, SANDIP BASU^{1,2}

¹Radiation Medicine Centre, Bhabha Atomic Research Centre, Tata Memorial Hospital Annexe, ²Homi Bhabha National Institute, Mumbai, Maharashtra, India

Address for correspondence: Dr. Sandip Basu, Radiation Medicine Centre, Bhabha Atomic Research Centre, Tata Memorial Hospital Annexe, Jerbai Wadia Road, Parel, Mumbai - 400 012, Maharashtra, India.
E-mail: drsanb@yahoo.com

Submitted: 08-May-2020, **Revised:** 20-May-2020,

Accepted: 04-Jun-2020, **Published:** 09-Sep-2020

This is an open access journal, and articles are distributed under the terms of the Creative Commons Attribution-NonCommercial-ShareAlike 4.0 License, which allows others to remix, tweak, and build upon the work non-commercially, as long as appropriate credit is given and the new creations are licensed under the identical terms.

For reprints contact: WKHLRPMedknow_reprints@wolterskluwer.com

How to cite this article: Loharkar S, Basu S. Grade 3 metastatic neuroendocrine neoplasms of two unusual primary sites with contrasting differentiation characteristics: Dual tracer positron emission tomography and computed tomography imaging (¹⁸F-fluorodeoxyglucose and ⁶⁸Ga-DOTATATE) correlates and their treatment implications. World J Nucl Med 2021;20:125-8.

Access this article online**Website:**

www.wjnm.org

DOI:

10.4103/wjnm.WJNM_67_20

Quick Response Code

3 neuroendocrine tumors (NET) with well-differentiation features and (b) Grade 3 poorly-differentiated neuroendocrine carcinomas (NEC). This communication illustrates the correlates of dual tracer positron emission tomography and computed tomography (PET-CT) findings with this histopathological concept in Grade 3 NENs that demonstrate the potential of this molecular PET-CT imaging approach in deciphering the tumor biology that could have important treatment implications.^[2,3]

CASE REPORT

Case 1

A 44-year-old serviceman, diagnosed to have gall bladder NET (operated) with hepatic metastasis, was referred for the evaluation of peptide receptor radionuclide therapy (PRRT) presented with vague upper abdominal discomfort with dyspepsia of 1.5 months duration. The ultrasonography (USG) of the abdomen revealed ill-defined lesion adjacent to gall bladder fossa with soft-tissue area in the fundus. Further evaluation with diagnostic contrast-enhanced CT (CECT) (abdomen and pelvis) showed an irregular heterogeneously enhancing mass lesion at gall bladder fundus with the invasion of adjacent liver parenchyma (segment IVb). Histopathological analysis of the mass (USG-guided biopsy) revealed high grade well-differentiated NET with Ki-67/MiB-1 labeling index of 35%. The patient had received neoadjuvant chemotherapy regimen three cycles of cisplatin and etoposide, followed by radical cholecystectomy (the histopathology report correlated well with previous biopsy report). Postsurgery, he had received adjuvant chemotherapy of further three cycles of cisplatin and etoposide. On follow-up visit, he complained of only minor discomfort in the upper abdomen CECT at this time showed hypoenhancing mass of 5.1 cm × 3.7 cm involving segments IVa and IVb, with a tumor thrombus extending into the proximal part of the left main portal vein, suspicious for recurrence. The serum chromogranin A level was raised (3509 ng/mL).

The patient underwent dual tracer PET/CT scan (¹⁸F-fluorodeoxyglucose [¹⁸F-FDG] PET/CT and ⁶⁸Ga-DOATATE PET/CT) at our center for the evaluation of the disease. The dose injected was 4.5 mCi (166 Mbq) for ¹⁸F-FDG and study acquisition was undertaken at 60 min, while that for ⁶⁸Ga-DOATATE PET/CT was 2.5 mCi (92.5 Mbq) and scan acquisition was undertaken between 50 and 60 min. The scans revealed both somatostatin receptor (SSTR) expressing and FDG-avid hypodense liver lesions, largest in segment IVa and IVb measuring 6.6 cm × 5.0 cm with SUVmax (FDG)-21.3 and SUVmax on ⁶⁸Ga-DOTATATE PET/CT 33 with no other distant site of metastasis identified [Figure 1].

Case 2

The second patient was a 35-year-old male, a patient of esophageal NEN, who initially presented with 6 months history of progressive dyspepsia and gastroesophageal reflux disease. An upper gastrointestinal endoscopic examination (scopy) showed lower esophageal growth measuring around 0.8 cm. The histopathology report was NEC Grade III with the Ki-67 labeling index approximately 70%. The baseline/staging ¹⁸F FDG PET/CT at his local place had revealed metabolically active 7.4 cm thickening at the lower third of the esophagus, suspicious paraesophageal lymph nodes in its thoracic part and hypodense hepatic lesions. He received chemotherapy (Etoposide and Cisplatin) and restaging ¹⁸F-FDG PET/CT revealed only metabolically active esophageal disease, and he further proceeded to local EBRT; Post EBRT ¹⁸F-FDG-PET/CT showed complete response with no evidence of any metabolically active disease in the esophagus and abdomen. He remained asymptomatic but showed no significant weight gain for the next 6 months; this time the ¹⁸F-FDG PET/CT showed metabolically active recurrent/residual disease in the esophagus, perigastric lymph nodes, and multiple hypodense liver lesions; he was then considered for second-line paclitaxel based chemotherapy which was tolerated well, and ¹⁸F-FDG PET/CT for response evaluation showed stable disease with no significant decrease in size as well as SUV values.

Subsequently, he defaulted for 6 months and again presented with complaints of significant weight loss (>8 kg in the previous 6 months) and dysphasia. He was evaluated in our department with dual tracer PET/CT studies 37 months after being diagnosed with surgically inoperable NEC, and after completion of 2nd line chemotherapy (¹⁸F-FDG PET/CT and ⁶⁸Ga-DOATATE PET/CT) for disease evaluation. The dose injected was 5.5 mCi (203.5 Mbq) for ¹⁸F-FDG and study acquisition was undertaken at 60 min, while that for ⁶⁸Ga-DOATATE PET/CT was 2.2 mCi (81.4 Mbq) and scan acquisition was undertaken between 50 and 60 min. The scans revealed metabolically active lesion of the lower third part of the oesophagus (measuring approximately 4.5 cm vs previous 2.8cm) and multiple hypodense liver lesions (largest measuring 7.2 cm × 7 cm Vs previous 2.2cm x 2cm), multiple abdominal enlarged lymph nodes (largest perigastric lymph node now measuring 4.1 cm × 2.9 cm Vs previous 0.8cm) suggesting disease progression. All these lesions showed more avidity on the ¹⁸F-FDG scan compared to ⁶⁸Ga-DOTATATE scan, which showed minimal uptake in the aforementioned lesions [Figure 2]. On comparison of the FDG-PET/CT, the primary esophageal lesion measured ~4.5 cm versus the previously recorded 2.8 cm, and SUVmax 7.0 versus 5.6

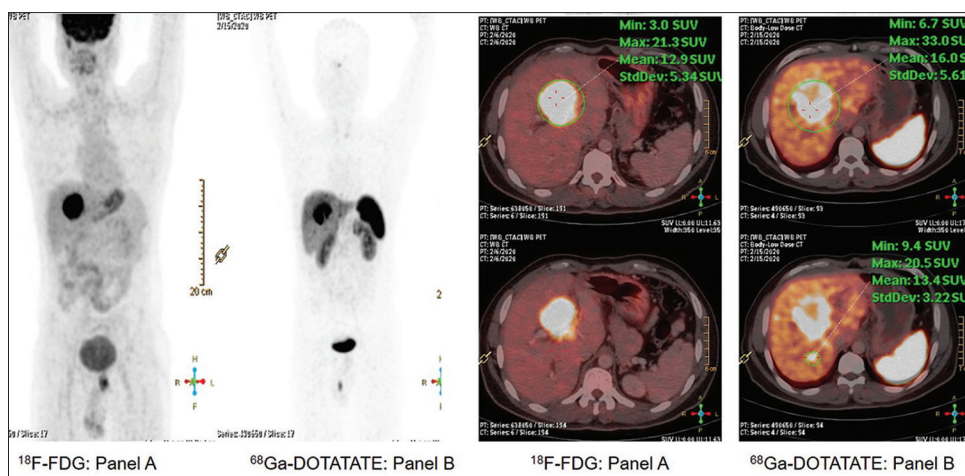


Figure 1: Dual tracer positron emission tomography and computed tomography scan (¹⁸F-fluorodeoxyglucose positron emission tomography and computed tomography and ⁶⁸Ga-DOTATATE positron emission tomography and computed tomography) showing both somatostatin receptor expressing and fluorodeoxyglucose avid hypodense liver lesions, largest in segment IVa and IVb measuring 6.6 × 5.0 cm with SUVmax (¹⁸F-fluorodeoxyglucose)-21.3 (panel A) and SUVmax (⁶⁸Ga-DOTATATE)-33 (panel B)

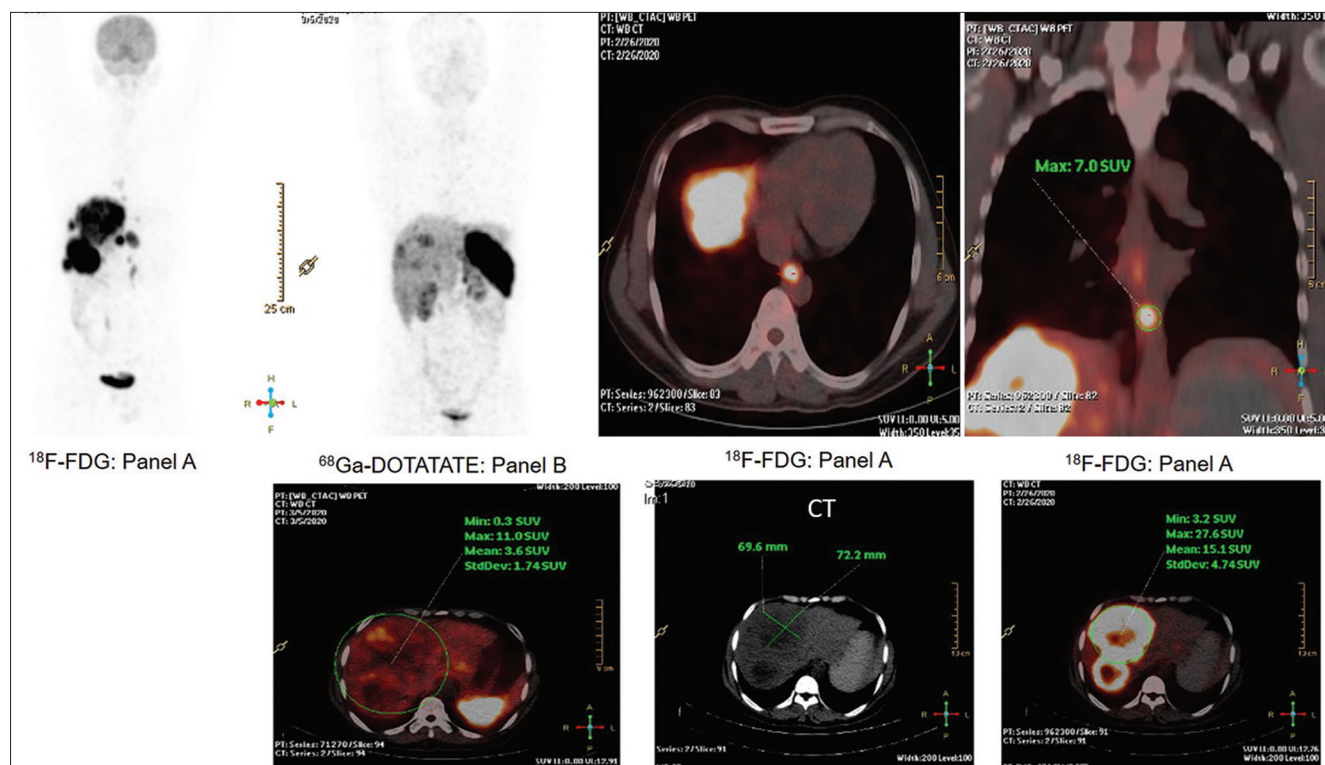


Figure 2: Dual tracer positron emission tomography and computed tomography evaluation (¹⁸F-fluorodeoxyglucose and ⁶⁸Ga-DOTATATE) demonstrates the progression of disease with fluorodeoxyglucose avid lesions of the lower third part of the esophagus (now measuring approximately 4.5 cm), multiple hypodense liver lesions (largest measuring 7.2 cm × 7 cm), multiple abdominal enlarged lymph nodes (largest perigastric lymph node measuring 4.1 cm × 2.9 cm) all showing more avidity on 18F fluorodeoxyglucose scan (panel A) compared to ⁶⁸Ga-DOTATATE positron emission tomography and computed tomography (panel B)

was observed. The liver segment IVb lesion measured 7.2 cm × 7.0 cm versus 2.2 cm × 2.0 cm, while the measured SUVmax was 27.6 versus 22.7 previously. With regard to the lymph nodes, the largest perigastric lymph node measured

4.1 cm × 2.9 cm with SUVmax 19.1, which was merely visible before (subcentimeter size). Many abdominal lymph nodes and liver lesions were newly seen; all these suggested disease progression.

DISCUSSION

Thus this communication illustrates the imaging features in rare nonfunctional Grade 3 metastatic NENs from two unusual primary sites (gall bladder and esophagus) with contrasting differentiation characteristics. The dual tracer PET-CT imaging (^{18}F -FDG and ^{68}Ga -DOTATATE) was undertaken, wherein the first group (a patient of gall bladder NEN, operated, histopathology suggestive of high grade well-differentiated NET with Ki-67 labeling index 35%) showed uptake with both tracers (including high uptake equivalent to Krenning score of 3–4 on ^{68}Ga -DOTATATE PET-CT) [Figure 1], whereas in the second group (a patient of esophageal NEN, Grade 3, with Ki-67 labeling index 70%, poorly-differentiated NEC), the FDG uptake was high with minimal uptake on ^{68}Ga -DOTATATE PET-CT [Figure 2]. It is imperative that the former case scenario would respond better to combined chemo-PRRT (^{177}Lu -DOTATATE and CAPTEM combination is the preferred choice with Ki-67 <55%), while the latter would be a more suitable candidate for platinum-based chemotherapy (carboplatin-paclitaxel combination), with which he was treated, and PRRT is not an option in this case scenario.

CONCLUSION

The illustrations reiterate the impression that relative uptake of ^{68}Ga -DOTATATE/FDG in the NEN lesions forms a valuable parameter for assessing the dynamic tumor biology in continuum and thus personalizing the treatment strategies. We recommend that these classes of patients with Grade 3 NENs must be extensively evaluated at the diagnosis and restaging with dual tracer PET/CT scan. We believe this would contribute substantially inpatient management and allow to address the “unmet needs” of Grade NENs that have been highlighted in recent times.^[4]

Declaration of patient consent

The authors certify that they have obtained all appropriate patient consent forms. In the form the patient(s) has/have given his/her/their consent for his/her/their images and other clinical information to be reported in the journal. The patients understand that their names and initials will not be published and due efforts will be made to conceal their identity, but anonymity cannot bechrological order guaranteed.

Financial support and sponsorship

Nil.

Conflicts of interest

There are no conflicts of interest.

REFERENCES

1. Rindi G, Klimstra DS, Abedi-Ardekani B, Asa SL, Bosman FT, Brambilla E, *et al.* A common classification framework for neuroendocrine neoplasms: An International Agency for Research on Cancer (IARC) and World Health Organization (WHO) expert consensus proposal. *Mod Pathol* 2018;31:1770-86.
2. Basu S, Sirohi B, Shrikhande SV. Dual tracer imaging approach in assessing tumor biology and heterogeneity in neuroendocrine tumors: Its correlation with tumor proliferation index and possible multifaceted implications for personalized clinical management decisions, with focus on PRRT. *Eur J Nucl Med Mol Imaging* 2014;41:1492-6.
3. Basu S, Adnan A. Well-differentiated grade 3 neuroendocrine tumours and poorly differentiated grade 3 neuroendocrine carcinomas: Will dual tracer PET-computed tomography (^{68}Ga -DOTATATE and FDG) play a pivotal role in differentiation and guiding management strategies? *Nucl Med Commun* 2019;40:1086-7.
4. Capdevila J, Bodei L, Davies P, Gorbounova V, Jensen RT, Knigge UP, *et al.*; ENETS 2016 Munich advisory board participants; ENETS 2016 Munich advisory board participants. Unmet Medical Needs in Metastatic Lung and Digestive Neuroendocrine Neoplasms. *Neuroendocrinology* 2019;108:18-25.